GBS

A 14-year-old boy with a history of epilepsy complains of progressive lower limbs weakness and tingling sensation since last two days. His face, trunk and upper limbs are not involved. He has had fever and runny nose 10 days ago. On physical examination, there is 3/5 muscle strength in both lower limbs with absent reflexes.

* Ascending Paralysis
- Loss of Deep Tendon Reflexes
- EMG / NCS

Blood pressure 120/80 mmHg
Heart rate 85 /min
Respiratory rate 18 /min
Temperature 37.4° C

Which of the following is the most likely diagnosis?

Rx : * IVIG
Plasmapheresis

A. Polymyositis

B. Multiple sclerosis

C. Acute poliomyelitis

**D. Guillain-barre syndrome

Guillain-Barré Syndrome (GBS) (or acute inflammatory polyneuropathy) is an autoimmune damage of multiple peripheral nerves.

There is no CNS involvement. A circulating antibody attacks the myelin sheaths of the peripheral nerves, removing their insulation.

GBS is associated with Campylobacter jejuni infection.

A 5-year-old boy is brought to the Emergency Department after an episode of convulsion that involved all limbs 1 hour ago. It continued for 3 minutes and associated with drooling and loss of consciousness. He had runny nose, mild cough and fever for last 3 days. On physical examination, he was fully active with mild congested throat.

Blood pressure 120/80 mmHg
Heart rate 98 /min
Respiratory rate 22 /min
Temperature 37.9° C

* If ACTIVE SEIZURES or time > 5 mins : give Diazepam (rectally).

Which of the following is the most appropriate treatment?

A. Phenytoin

B. Diazepam

C. Amoxicillin

✓ **D. Paracetamol

Which of the following measures would decrease the incidence of Sudden Infant Death Syndrome?

**A. Pacifier at bedtime

B. Sleep in prone potion

C. Soft sleeping mattress

D. Sleep position support device

In which conditions circumcision should be avoided?

A. Phimosis

**B. Hypospadias

C. Unilateral Cryptorchidism

D. Posterior urethral valve

A 6-year-old girl presents with sudden involuntary abnormal movement in her limbs that started 10 minutes ago. It was associated with inability to speak. Few hours ago, she took metoclopramide, hyoscine butylbromide and oral rehydration solution after being diagnosed with viral gastroenteritis. The physical examination showed facial grimacing and protrusion of tongue.

Which of the following is most appropriate treatment?

A. Tizanidine

(Acute dystonic reaction, common side effect of metacroplomide. treated by IV anticholinergic such as benztropine or diphenhydramine)

B. Epinephrine

C. Cyproheptadine

**D. Diphenhydramine

A 4-month-old boy presents to the clinic with rash over the neck for 3 days. The rash is not itchy (see image).

Which of the following is the most likely diagnosis?

A. Cellulitis

**B. Candidal intertrigo

C. Erythema Multiform

D. Seborrheic dermatitis

A 3-year-old boy presents to the clinic with blood in his diapers for 2 days. There is no associated abdominal pain or constipation. He had similar presentation 3 months ago. The physical examination shows pale conjunctiva and dry oral mucosa.

Blood pressure 130/75 mmHg
Heart rate 124 /min
Respiratory rate 35 /min
Temperature 37.4° C

Which of the following is the most likely diagnosis?

A. Juvenile polyp

B. Intussusceptions

C. Hirschsprung disease

**D. Meckel's diverticulum

A 6-year-old boy presents to the Outpatient Department with frequent and brief episodes of

rapid eyes blinking for 2 weeks. The episodes are not associated with pain, redness, tearing or discharge. During the episode, he communicated well with his parents. The physical examination shows normal visual acuity.

Which of the following is the most likely diagnosis?

**A. Tic disorder

B. Petit mal seizure

C. Dry eye syndrome

D. Tourette syndrome

A 2-week-old girl presents with persistent vomiting since birth. She vomits about 1 hour after feeding. She passes stool 3 times per day. The physical examination shows a small non-tender mass in the epigastrium.

Blood pressure 95/55 mmHg
Heart rate 135 /min
Respiratory rate 35 /min
Temperature 37.1° C

Which of the following is the most appropriate investigation?

A. Barium swallow

B. Abdominal X-ray

C. Abdominal CT scan

**D. Abdominal ultrasound

A 13-year-old boy comes to clinic complaining of fatigue, non-productive cough, low-grade fever and night sweats over the past 7 weeks. He also mentioned that he has had 2 episodes of hemoptysis.

Which of the following is the most likely diagnosis?

**A. Tuberculosis

B. Bronchiectasis

C. Lung neoplasm

D. Mycoplasma pneumonia

A 6-year-old child presents with a high-grade fever, malaise, conjunctivitis, coryza, and a cough. A rash of discrete pink macules recently began on the face and extends to the hands and feet. The child also had small, whitish spots inside the mouth before the rash appeared.

Which of the following is the most likely diagnosis?

KOPLIK SPOTS

A. Toxic shock syndrome

B. Gonococcal bacteremia

**C. Measles

D. Rubella

Gynae Obs

A 40-year-old Healthy Primigravida with a history previous deep venous thrombosis.

Which of the following is the most appropriate management?

A. Aspirin

B. Heparin

C. Enoxaparin

**D. No anticoagulation

A 29-year-old G4 P3003 at 12 weeks' gestation. Her current pregnancy has been uneventful. One week ago she has noticed swelling of her ankles and feet (see lab results).

Blood pressure 150/95 mmHg
Heart rate 84 /minute
Temperature 36.9°C
Respiratory Rate 15 /minute

Test Result Normal Values
Hb 11.9 120-158 g/L
Creatinine 65 58-145 µmol/L
Uric acid 210 140-360 µmol/L
Urine analysis Trace protein

Which of the following is the most appropriate therapy?

**A. Methyldopa

B. Atenolol

C. Captopril

D. Losartan

During a difficult forceps delivery, an obstetrician misapplied the blade of the forceps at the child's left stylo-mastoid foramen where the forceps crushed its contents.

What would be the baby's residual defect?

Orbicularis Oculi
↓
Facial N

**A. Inability to close the left eyelid

B. Reduced blood supply to the left ear

C. Loss of sensation from the left side of the face

D. Loss of taste from anterior 2/3rd of the tongue

A 34-year-old G4 P0030 at 32 weeks' gestation presented to the Emergency Department with

tonic clonic convulsions.

Temperature 37.2
Blood pressure 140/95 mmHg
Respiratory rate 16/ minute
Pulse 90/minute

What is the most effective drug to control her seizures?

**A. Magnesium sulphate

B. Hydralazine

C. Phenytoin

D. Diazepam

A 27-year-old primigravida had a glucose tolerance test (see lab results).

	Patient's results	Normal Values
Fasting	5.7	3.3 to 5.5 Mmol/l
1 hour	9.4	Less than 11.1 Mmol/l
2hour	9.8	Less than 8.6 Mmol/l
3 hour	7.2	Less than 7.8 Mmol/l

Which of the following is the next best step in management?

A. Take a random glucose level

B. Obtain a haemoglobin A1c

**C. Adjust the patient's diet

D. Repeat the GTT

A 35-year-old G2 P1001 at 30 weeks' gestation with poorly controlled gestational diabetes on diet.

Which of the following medications is the most appropriate treatment?

A. Pioglitazone HCl

B. Metformin HCl

C. Glyburide

**D. Insulin

A 35-year-old nulliparous on treatment for hyperprolactinemia for the past year.

When would pituitary imaging be indicated?

A. Prolactin level is twice the normal

**B. Persistent galactorrhea

C. Blurred vision

D. Pregnancy

A 40-year-old woman is on Tamoxifen 20 mg daily as a hormonal treatment of breast cancer. She complains of heavy and prolonged menstrual period. Her transvaginal ultrasound revealed the presence of 28 mm endometrial thickness with cystic changes.

Which of the following is the next step in the patient's evaluation?

≥ 5mm thickness
↓
BIOPSY

**A. Endometrial sampling

B. Cancer cell surface antigen 125

C. Computed tomography of the pelvis

D. Serum follicular and luteinizing hormones

A 24-year-old obese woman, no previous pregnancy, complains of irregular menstrual periods. Menarche was at age of 14 and her periods were irregular in timing, duration and flow. The last menstrual flow was scanty 3 months ago. History of weight gain since menarche along with facial acne and mild facial hirsutism (see lab results).

Test Result Normal Values
↑ Testosterone 3.4 0.7-2.8 nmol/L
Sex hormone-binding globulins 9 13-17nmol/L
↑ Luteinizing hormone 31 5-22 U/L
↓ Follicle-stimulating hormone 2.1 5-20 IU/L
Random Glucose 6.1 3.9-5.5 mmol/L

Free testosterone will be elevated secondary to the high androgens
High androgens and obesity lead to an increase in estrogen formation outside the ovary; this stimulates LH secretion and inhibits FSH secretion, where the LH:FSH ratio >3:1.

Which of the following is the most likely diagnosis?

A. Turner's syndrome

B. Exogenous obesity

C. Premature ovarian failure

**D. Polycystic ovary syndrome

A 25-year-old breastfeeding mother, who delivered a month ago, presents with fever and pain in the right breast for the past 2 days. The fever comes with chills and malaise. On examination, the right breast shows a skin wound on the areolar with a reddened and indurated surrounding area.

Blood pressure 110/70 mmHg
Heart rate 86 /min
Respiratory rate 18 /min
Temperature 39.0° C

Which of the following is the most likely causing pathogen?

A. Escherichia coli

**B. Staphylococcus aureus

C. Haemophilus influenzae

D. B-haemolytic streptococci

PCOS

A 22-year-old woman has multiple small cysts within the ovary, as well as excessive androgen production from the ovaries, anovulation, insulin resistance, hypertension, and hirsutism.

Which of the following is the most likely diagnosis?

Diagnosis of polycystic ovary syndrome is made when 2 of the following 3 conditions are present:
Amenorrhea or irregular menses
Signs of hirsutism
Polycystic ovaries on U/S

A. Gynecomastia

B. Kallman's syndrome

C. Klinefelter's syndrome

**D. Stein-leventhal syndrome

Rx
- OCP's (pts. who DONT want to conceive)
- Metformin + LETROZOLE } who wants to CONCEIVE
- Metformin OR + Clomiphene } who wants to CONCEIVE

A 28-year-old woman presents to the Maternal Health Clinic and reports that she has not had a menstrual period for the past 2 months. Human chorionic gonadotropin tested positive. Her significant health history included a needle-stick injury 1 year ago from a patient with hepatitis C. She was treated with interferon and has received monthly screening examinations. She asked if she would be able to breastfeed her newborn.

Which of the following complications would most likely prevent breastfeeding?

A. Lack of routine newborn immunizations

B. Neonatal oral candidiasis

C. Maternal anaemia

**D. Cracked nipples

A 22-year-old woman presents to the Women's Health Clinic for a routine examination. Her menstrual cycle occurs every 28 days and lasts for 5 days with moderate bleeding. Clinical breast examination showed bilateral symmetry with no abnormal findings on palpation. However, she reported regular breast tenderness that began 3 days prior to menses. There was no known maternal or paternal history of cancer. She wishes to become pregnant within the next 2 years.

Which of the following screening tests should be done?

A. Breast ultrasound

**B. Papanicolaou smear

C. Human papilloma virus

D. Group beta streptococcus

A 30-year-old multiparous woman at 10 weeks' gestation presented to the Maternal Health Clinic complaining of nausea and vomiting. She was unable to keep down any food or fluid. Her tongue appeared dry and covered with a white coating. The skin turgor was reduced; refill time and urine output was scant. She was admitted to the High Risk Maternity Unit for observation and was started on an intravenous infusion of 10% glucose in normal saline. A urinalysis sent to

the laboratory for examination.

Blood pressure 90/60 mmHg
Heart rate 120 /min
Respiratory rate 16 /min
Temperature 37.0° C oral

Which urinalysis finding would most likely confirm the diagnosis?

A. Leukocytes

B. Glucose

**C. Ketones

D. Proteins

A 25-year-old woman is 10 days postpartum and breastfeeding on demand. For 48 hours before presentation to the clinic, she has had episodes of chills with feeling weak and tired. Physical examination revealed redness of the left breast, and tenderness and excoriation of the areola. A left breast tender, mobile 3 cm dominant lump was found in the upper outer quadrant on palpation and left axillary lymphadenopathy was present (see lab results).

Blood pressure 110/70 mmHg
Heart rate 115 /min
Respiratory rate 20 /min
Temperature 39.0° C

Test Result Normal Values
Hb 115 120-160 g/L
WBC 14 4.5-10.5 x 109/L
Neutrophils 80 40-60%
Band cells 7 3-5%
Basophils 1 0.5-1 %
Eosinophils 1 1-4 %
Lymphocytes 50 20-40 %
Monocytes 2 2-8 %

Which of the following is the most likely diagnosis?

A. Fibrocystic breast disease

B. Inflammatory carcinoma

C. Puerperal sepsis

**D. Breast abscess

A 35-year-old woman attended the Gynecological Clinic complaining of greenish-yellow purulent vaginal discharge that has started after her period. Upon vaginal examination, there was multifocal rounded macular erythematous lesions (like a spotted rash or bruise), and there was pelvic tenderness.

Which of the following conditions is the most likely diagnosis?

A. Vaginal candidiasis

B. Bacterial vaginosis (not itching)

C. Atrophic vaginitis

**D. Vaginal trichomoniasis (itching)

A 65-year-old post-menopausal woman complains of on and off vaginal bleeding that started 2 months ago. The amount of bleeding is mild to moderate of fresh blood. The woman is diabetic, hypertensive and obese. She has used hormone replacement therapy to control post-menopausal symptoms.

Body mass index 37 kg/m2

Which of the following investigations is essential to establish the diagnosis?

A. Pelvic magnetic resonance image

B. Pelvic ultrasonography

**C. Endometrial biopsy

D. Tumor markers

A 67-year-old woman attended the Gynecological Clinic for the follow up of lichen sclerosus diagnosed few years earlier. Upon examination, a small mass measuring 0.5 x 0.5 cm was identified on her right labia majora. Punch biopsy was taken from the lesion and sent for histopathology.

Which of the following is the most likely histopathological finding?

A. Adeno-squamous carcinoma

**B. Squamous cell carcinoma

C. Adenocarcinoma

D. Melanoma

A 29-year-old woman complaining of a heavy vaginal discharge for the past 2 weeks. The discharge was thin and a greyish white color with a slight fishy vaginal odor. On examination, a copious, thin, whitish discharge is seen adherent to the vaginal wall.

Vaginal pH 5.5

Δ Bacterial Vaginosis

Which of the following is the most appropriate treatment?

**A. Metronidazole

B. Oral diflucan

C. Tetracycline

D. Doxycycline

A 57-year-old menopausal woman, presents for evaluation of post-menopausal bleeding. She is morbidly obese, hypertensive and diabetic. Endometrial sampling showed complex endometrial hyperplasia with atypia.

Which of the following is the most appropriate treatment?

A. Myomectomy

B. Oral progesterone → Premenopausal – who want to conceive

C. Uterine artery embolization

**D. Total abdominal hysterectomy → Pre + Post — who dont want to conceive

A 55-year-old woman presented to the clinic with urinary leakage for the last 6 weeks. She cannot hold her urine and urine leaks even before she reaches the bathroom. History revealed she has been menopause for the last 6 years.

Which of the following is the first step in the evaluation?

A. Cystourethroscopy

B. Intravenous pyelogram

C. Urethral pressure profile

**D. Urine analysis and culture

A patient who had a vaginal delivery 3 months ago is complaining of fecal incontinence and passage of vaginal flatus. These symptoms have started 1 week postpartum.

Which of the following is the most likely diagnosis?

A. Hemorrhoids

B. Puerperal sepsis

C. Partial perineal tear

**D. Recto-vaginal fistula

A 60-year-old woman's recent pap smear yielded a result of Atypical squamous cells of undetermined significance (ASC-US). She was given topical vaginal estrogen for one month and was scheduled for another pap smear a week after the treatment cycle has completed. The second pap smear showed ASC-US as well.

Which of the following is the most appropriate next investigation?

A. Repeating pap smear after 6 months

B. Endometrial biopsy

C. HPV testing

**D. Colposcopy

A 25-year-old woman complained of swelling on one side of the labia. The swelling was first noticed 24 hours ago and has not improved despite warm tub soaking. There was a non-tender 3 cm slightly mobile cystic mass at approximately 7 o'clock on the right side of the vaginal introitus.

Blood pressure 110/70 mmHg
Heart rate 76 /min
Respiratory rate 18 /min
Temperature 37° C

Bartholin glands are located on the lateral sides of the vulva. They secrete mucus and can become obstructed, leading to a cyst or abscess which causes pain, tenderness, and dyspareunia. Physical exam shows edema and inflammation of the area with a deep fluctuant mass.

Rx: I & D (if not resolved by conserv. measures)
Marsupialization (if recurrent)

Which of the following is the most likely diagnosis?

**A. Bartholin cyst

B. Vulvar myoma

C. Vaginal adenosis

D. Skene's duct cyst

Candidiasis

A 33-year-old woman comes to the clinic complaining of recent onset of vaginal itching. Physical examination of the vagina revealed a thick, odorless white cottage cheese-like vaginal discharge that adheres to the mucosa. She has recently finished a course of antibiotics for an upper respiratory tract infection.

Which of the following is the most likely diagnosis?

	Discharge	*Micro*	*Notes*	*Abx*
Candida	Thick, white, adherent to wall	**Hyphae** (KOH prep)	DM, Abx	**Anti-Fungals** OTC: Topical Rx: Fluconazole
BV	Grey-white, fishy odor, most common	**Clue Cells** (saline prep)	KOH fishy smell	**Metronidazole**
Trich	Yellow-Green and Frothy, Strawberry Cervix	**Motile Flagellated** (saline prep)	Ping-Pong	**Metronidazole** Both partners!

A. Chlamydia

**B. Candidiasis

C. Gardnerella

D. Trichomoniasis

A 48-year-old woman patient suffers from several episodes of vaginal discharge and itching around the genital area. The discharge is white and curd-like. The patient's spouse does not have any related condition. Microscopy of the discharge revealed budding yeast and pseudohyphae.

The patient's symptoms might be associated with which of the following conditions?

A. Sarcoidosis

B. Tuberculosis

**C. Diabetes mellitus

D. Lupus erythematosus

A 56-year-old postmenopausal woman presents with a 1-year history of recurrent irritation in the pubic area. The patient reported itchiness with blood-stained discharge at times. The patient has tried a metronidazole suppositories as well as topical cream over the labia with little relief. Recently, the patient feels a pea-sized lump on the labia.

Which of the following is the most likely diagnosis?

A. Bartholin cyst

B. Cystic adenosis

C. Bartholin gland carcinoma

**D. Squamous cell carcinoma of vulva

A 21-year-old patient presented to the clinic complaining of diffuse abdominal pain for the past 3 days. Her history included dyspareunia, nausea, and several episodes of vomiting. On examination, external genitalia and cervix appeared normal. However, the patient reported cervical motion, adnexal, and lower abdominal tenderness.

Blood pressure 120/60 mmHg
Heart rate 72 /min
Respiratory rate 16 /min
Temperature 38.4° C

Which of the following is the most likely diagnosis?

**A. Pelvic inflammatory disease

B. Chronic cholecystitis

C. Acuter appendicitis

D. Cervicitis

A 23-year-old woman who just recently had an intrauterine device fitted, complaining of watery brown vaginal discharge and abdominal pain.

Which of the following is the most likely diagnosis?

A. Uterine rupture

B. Bacterial vaginosis

C. Twisted ovarian mass

**D. Pelvic inflammatory disease

A 21-year-old woman patient complained of severe vulvovaginal itching and discharge. There are no urinary or other symptoms, and annual papanicolaou tests have all been normal. On inspection, Vulvar erythema with swelling. Speculum examination revealed a thick, white, curdy discharge adherent to the vaginal walls with no odour. A gross and microscopic examination of the vaginal discharge was done; the wet mount revealed no evidence of clue cells or trichomonads and the KOH prepped slide confirmed several pseudohyphae (see lab results).

Test Result Normal Values
pH 4.0 3.8-4.5
Whiff test negative negative

Which of the following is the most likely diagnosis?

A. Trichomoniasis

B. Bacterial vaginosis

C. Physiologic discharge

**D. Vulvovaginal candidiasis

A young adult was being treated with Ceftriaxone for acute salpingitis and pelvic inflammatory disease without benefit.

Which of the following is the most likely diagnosis?

A. Adenovirus infection

B. Herpes virus infection

C. Neisseria gonorrhoeae infection

**D. Chlamydia trachomatis infection (MC)

A 34-year-old woman non-smoker with 2 previous normal deliveries presented for a routine pap smear and her last pap was normal 7 years ago. The patient has had 1 episode of venereal warts at 18 year-old with no recurrence. The rest of her history is not significant (see report).

Pap smear:
A typical squamous cells of undetermined significance.

What will be the first step in management?

A. Another pap smear

B. Hysterectomy

C. Colposcopy

**D. HPV testing

A woman comes to the clinic for having a history of increasing pelvic pain, which is cyclic in nature and increasing in intensity just before menses.

Which of the following is an acceptable method for diagnosing endometriosis?

A. Magnetic resonance image

**B. Diagnostic laparoscopy

C. Endometrial biopsy

D. Ultrasound

Initial . TV US

Confirmatory: Laparoscopy

A 67-year-old woman presented with vaginal itching and burning. Currently, she is only on calcium supplements. Physical examination revealed thinning and pallor of the vaginal mucosa and no discharge. Wet prep from the scant material present was negative for any organisms.

Which of the following is most appropriate initial treatment?

A. Topical corticosteroid cream

B. Metronidazole vaginal gel

C. Vinegar and water douche

**D. Estrogen vaginal cream

A 23-year-old woman presented with a yellowish green malodorous vaginal discharge. Speculum exam showed the cervix was slightly red and inflamed. A probe for chlamydia was collected and wet prep confirmed Trichomonas vaginalis.

Which of the following is the first step in management?

A. Doxycycline — 2nd LINE

6th June Exam DHA

B. Clindamycin

**C. Metronidazole

D. Follow-up wet prep

A 28-year-old woman presented with a history of a copious white vaginal discharge associated with intense vulvar irritation and itching for four days. Microscopic examination revealed evidence of pseudohyphae.

Which of the following is the most appropriate treatment?

**A. Terconazole vaginal cream

B. Metronidazole

C. Doxycycline

D. Ganciclovir

A 24-year-old married woman presented with severe abdominal pain followed by vaginal bleeding for the last 6 hours. She reported having amenorrhea for the past 8 weeks as well. The patient looked drowsy with a tense abdomen.

Blood pressure 90/60mmHg
Heart rate 120 /min
Respiratory rate 18 /min
Temperature 36.6° C

Δ Ectopic Pregnancy Rupture

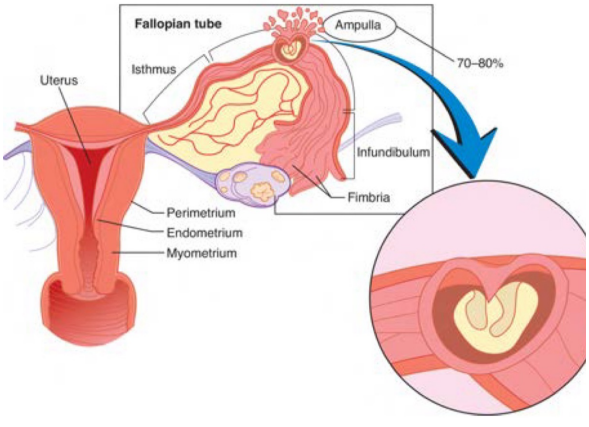

Which of the following is the most likely source of bleeding?

A. Ovary

B. Cervix

C. Peritoneum

**D. Fallopian tube (Ampulla - MC location)

A 58-year-old multiparous woman is complaining of urine leakage at laugh or cough. She is not able to hold her urine along with feeling of "dragging" or "balloon-like" sensation in the genital area for the past 4 months. Physical examination is normal except for bulging of the lower anterior vaginal wall.

Which of the following is the most likely cause of those symptoms?

A. Cystocele

B. Rectocele

C. Enterocele

**D. Urethrocele

A 30-year-old married woman has had an abnormal Papanicolaou test result. Repeated smears were suggestive of high-grade intraepithelial lesions. Pelvic and rectal examinations were normal.

Which of the following is the next step in management?

A. Total hysterectomy

B. Cervical cone biopsy

C. Therapeutic irradiation

**D. Colposcopy directed biopsy

A 68-year-old woman underwent a total abdominal hysterectomy and bilateral salpingo-oophorectomy. 3 days following the surgery, urinary catheter was removed and she was able to independently void 1 hour with an output of 35 ml/hr. She has been receiving fluids by continuous intravenous drip. She described the incisional pain as uncomfortable and rates it at a level 5 on the pain assessment scale. For pain relief, she was taking Ibuprofen 800 milligrams every 6 hours. The doctor considered her ready for discharge (see lab results).

Blood pressure 118/68 mmHg
Heart rate 70 /min
Respiratory rate 20 /min
Temperature 37.4° C oral

Test Result Normal Values
HCT 0.37 0.37-0.48
Hb 122 120-160 g/L

Which of the following would be a reason for this patient to remain in hospital?

A. Decreased hemoglobin and hematocrit

**B. Absence of oral fluid intake

C. Inadequate urinary output

D. Increased body temperature

A 56-year-old nulliparous and menopaused for 4 years, presented to the clinic with intermittent vaginal bleeding for the last 4 weeks. The bleeding was scanty and bright in color. Pelvic examination shows healthy vagina and cervix with a small amount of blood in the cervical os.

Which of the following is the next step in management?

A. No treatment necessary

**B. Dilation and curettage

C. Endometrial biopsy

D. Pelvic ultrasound

D & C → Biopsy to rule out Hyperplasia

Colposcopy

A 30-year-old para 3 woman presented with a significant history of smoking 2 packs of per week for the past 7 years. She was using a progestin-only pills. She has had annual Papanicolaou examinations for the past 9 years and all results have been normal. Bimanual pelvic examination showed normal findings. Papinicolaou smear repeated with results of low-grade epithelial lesions.

	Age 21–25	Age 25–30	Age 30–65
Routine screening	Cytology every 3 years	Cytology every 3 years	• Cytology every 3 years OR • Cytology and HPV testing every 5 years OR • HPV testing alone every 5 years
ASCUS	Repeat cytology in 1 year	Order HPV: • HPV+, colposcopy and ECC • HPV–, repeat Pap in 3 years	Order HPV: • HPV+, colposcopy and ECC • HPV–, repeat Pap in 3 years
LSIL	Repeat cytology in 1 year	Colposcopy and ECC	Order HPV: • HPV+, colposcopy and ECC • HPV–, repeat Pap in 1 year
HSIL	Colposcopy and ECC required regardless of age		

Which of the following is the most appropriate next step in management?

**A. Colposcopy

B. Repeat test in 1 year

C. Cold-knife conisation

D. Loop electrosurgical incision

A patient comes for a follow-up 2 weeks after a vaginal hysterectomy with anterior and posterior repair; the patient had leakage of urine from the vagina during micturition.

Which of the following is the most likely diagnosis?

A. Cystitis

B. Vesicovaginal fistula

C. Ureterovaginal fistula

**D. Urethrovaginal fistula

A 38-year-old woman presented with dysuria and increased frequency of urination. History reveals, she is allergic to sulfa, penicillin, and shellfish (see report).

Blood Pressure 120/80 mmHg
Heart Rate 80 /min
Respiratory Rate 16 /min
Temperature 38.0° C

Urine Dipstick:
Positive for leukocyte esterase.

Which of the following is the most appropriate treatment?

**A. Nitrofurantoin

B. Trimethoprim-sulfamethoxazole

C. Cephalexin

D. Amoxicillin

A 25-year-old woman had severe pelvic inflammatory disease 2 years ago that was treated by intravenous antibiotics. The isolated organism was chlamydia trachomatis. Since then the patient was trying for pregnancy but failed to do so. She had normal regular period and normal seminal analysis of her husband.

Which of the following investigations is recommended?

Chlmydia → PID
↓
Tubal Infertility
↓
Hysterosalpingogram

A. Ultrasound monitoring of her ovulation

**B. Magnetic resonance image of the pelvis

C. Computed tomography of the pelvis

Corrected ✓ D. Hysterosalpingogram

A 25-year-old woman had severe pelvic inflammatory disease 2 years ago that was treated by intravenous antibiotics. The isolated organism was chlamydia trachomatis. Since then the woman was trying for pregnancy failed to conceive. She had normal regular period and her husband had a normal seminal analysis. Hysterosalpingogram revealed normal uterine cavity and no free spillage of the injected dye bilaterally (see lab results).

Body mass index 35 kg/m2

Test Result Normal Values
Follicle-stimulating hormone 4.5 5-20 IU/L
Luteinizing hormone 3.9 5-22 U/L

Which of the following is the most appropriate method of management?

**A. In-vitro-fertilization and embryo transfer

B. Induction of ovulation followed by normal intercourse

C. Induction of ovulation followed by intrauterine insemination

D. Weight reduction to reach body mass index of 23 kg/m2

A 22-year-old diabetic woman presented with vaginal discharge and pruritus. The discharge is thick, grey and odorless. On physical examination, her vulva was erythematous and swollen. The vagina has a white-grey discharge that is adherent to the mucosa. Microscopic examination of the discharge confirmed the presence of spores.

Which of the following is the most likely pathogen?

A. Trichomonas vaginalis

B. Pediculosis pubis

**C. Candida albicans

D. Herpes simplex

A 27-year-old woman presented with vaginal itching and an unpleasant smelling discharge. Itching gets worse at night and after intercourse. Physical examination confirmed a frothy and yellow-green vaginal discharge. Her vulva is erythematous and edematous and the cervix is inflamed and friable (see report).

Wet Preparation:
Flagellated protozoa.

Which of the following is the most likely diagnosis?

A. Chlamydia

B. Gonorrhea

**C. Trichomoniasis

D. Bacterial vaginosis

A 48-year-old woman has had 2 inflammatory pap smears 3 months apart and a normal pelvic examination. A colposcopically directed biopsy of a normal appearing cervix revealed invasive carcinoma.

Which of the following is the best next step in management?

**A. Clinical staging of the disease

B. Conization of the disease area

C. Radical hysterectomy and chemotherapy

D. Radical hysterectomy and radiotherapy

A 34-year-old woman G5 P4004 presented to with amenorrhea, tiredness, nausea and vomiting during the morning hours for 3 months. Human chorionic gonadotropin test was positive. A physical examination showed no swelling in the lower extremities. The thyroid was enlarged on palpation. The tongue, conjunctiva and nail beds appeared pale. The uterine fundus was palpable 3 cm above the pubic symphysis. A peripheral blood smear showed macrocytic red blood cells and hypersegmented neutrophils (see lab results).

Blood pressure 100/60 mmHg
Heart rate 120 /min
Respiratory rate 26 /min
Temperature 37.0° C oral

Test Result Normal Values
Hb 85 120-160 g/L
HCT 0.32 0.37-0.48
MCHC 332 320-360 g/L
MCV 100 80-95 fl
Thyroid-Stimulating Hormone 0.44 0.4 - 5.0 µU/L

Which of the following is the most appropriate treatment?

A. Intravenous rehydration

**B. Folic acid supplements

C. Observation

D. Iron tablets

A 20-year-old nulliparous woman at 20 weeks' gestation has been on iron supplement therapy throughout her pregnancy to treat anemia. She complained of weakness and becoming easily tired (see lab results).

Test Result Normal Values
Hb 78 120-160 g/L
MCV 60 80-95 fl
RBC 5.4 4.2-5.4 x 1012/L → Iron Def Anemia → ↑ RDW

Which of the following is the most likely diagnosis?

A. Pregnancy associated hypothyroidism

B. Vitamin B12 deficiency

C. Iron deficiency anemia

**D. Beta thalassemia

A 20-year-old woman has a history of 3 first trimester abortions. She was diagnosed last year with pulmonary embolism (see lab results).

Test Result Normal Values
Prothrombin time 11 10-13 sec
APTT 69 30-40 sec
Platelets count 320 150-400 x 109/L
Lupus anticoagulant positive

Which of the following is the most likely diagnosis?

A. Factor V Leiden

B. Factor V deficiency

C. Protein C deficiency

**D. Antiphospholipid syndrome

A woman in her last month of pregnancy is diagnosed with right lower lobe pneumonia. Immune response to this infection leads to the formation of specific IgG antibodies.

The fetus would be immunologically protected when born owing to which of the following mechanisms?

A. Active artificial immunity

B. Active natural immunity

**C. Passive natural immunity

D. Passive artificial immunity

A 21-year-old woman presented with an abnormal vaginal discharge, burning on micturition, and blood spotting for the past 2 months. On genital examination, there was an eroded and friable (strawberry appearance) cervix, with a yellow-green mucopurulent discharge (see report).

Lab Testing:
>10 PMNs per oil immersion field.

Which of the following is the most likely diagnosis?

A. Gardnerella vaginalis

Corrected

B. Trichomonas vaginalis

C. Neisseria gonorrhoeae

**D. Chlamydia trachomatis

A 23-year-old woman presented with vaginal discharge with an unpleasant smell. Examination confirmed a homogenous grayish-white vaginal discharge that has a high PH. A saline wet-preparation examination of the discharge showed "clue cells" and with application of potassium hydroxide a fishy smell was generated.

Which of the following is the most likely diagnosis?

A. Phthirus pubis

B. Pediculosis pubis

C. Candida albicans

**D. Bacterial vaginosis

A 28-year-old woman presented with pain, fever, spasm of lower abdominal muscles and profuse purulent vaginal discharge for the past 2 days. On examination, there was suprapubic tenderness. Vaginal examination revealed tenderness in the fornices.

Blood pressure 108/56 mmHg
Heart rate 110 /min
Respiratory rate 14 /min
Temperature 38.4 ° C

Which of the following is the most likely diagnosis?

A. Acute cervicitis

**B. Acute salpingitis

C. Acute appendicitis

D. Chronic appendicitis

A 34-year-old primigravida presented to the obstetrician for an initial prenatal visit after self-confirming pregnancy with a home pregnancy test. She complained of breast tenderness and occasional nausea. There were no complaints of urinary frequency or urgency. Urine dipstick analysis was performed and a mid-stream urine sample was obtained (see lab results and report).

Test Result Normal Values
Nitrites ++ Negative
Leukocyte esterase Positive Negative

Culture Report:
Escherichia coli count is 50,000 CFU/ml.

Which of the following is the most likely diagnosis?

A. Cystitis

B. Pyelonephritis

C. Gonococcal infection

**D. Asymptomatic bacteriuria

A 26-year-old nulliparous patient presented to the clinic with vaginal itching and increased vaginal discharge. She had been diagnosed with a positive pregnancy test 3 months ago. A pelvic examination showed a yellow-white discharge at the vaginal introitus. The labia were inflamed and covered with scratch marks. The vaginal discharge was fishy smell pH 4.8.

Which of the following is the most appropriate treatment?

A. Ceftriaxone tablets

B. Ampicillin capsules

C. Clotrimazole cream

**D. Metronidazole tablets

A 35-year-old woman G4 P2012 at 26 weeks' gestation, uneventful pregnancy presented for a 50-gram oral glucose tolerance test. 1 hour later by finger stick sample glucose was 8.1 mmol/L.

Which vaginal infection is she at the highest risk of contracting?

**A. Candidiasis

B. Vulvodynia

C. Trichomoniasis

D. Bacterial vaginosis

A 25-year-old woman presented to the clinic with an unpleasant-smelling discharge. A speculum examination showed vaginal discharge, grey-green in color. The cervix was covered with

papillae with light-red color. A specimen of vaginal secretions was obtained for a wet-prep microscopy which showed unicellular organisms with flagella.

Which of the following is the most appropriate management?

**A. Oral metronidazole

B. Topical imidazole

C. Oral fluconazole

D. Clindamycin

A 28-year-old woman at 24 weeks' gestation presented to the clinic for a routine examination. A pelvic examination showed a watery grey-colored discharge, fish-like smell. There were no signs of inflammation of the vagina or cervix. She reported some itching and moderate discomfort. The vaginal pH 5.1. A sample of the vaginal discharge was collected for analysis.

Which of the following is the most likely finding?

A. Branching hyphae

**B. Granular epithelial cells

C. Giant multinucleated cells

D. Overproduction of lactobacilli

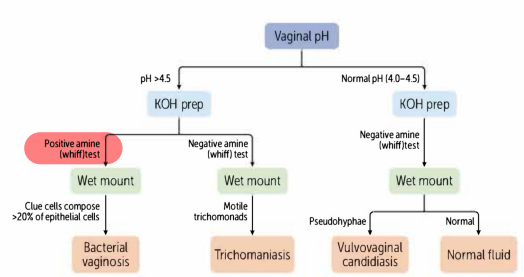

Bacterial Vaginosis

KEY FACT

Criteria for the clinical diagnosis of bacterial vaginosis (three of four are required):

- Abnormal whitish-gray discharge
- Vaginal pH >4.5
- ⊕ amine ("whiff") test
- Clue cells composing >20% of epithelial cells on wet mount

A 32-year-old woman presents with smelly vaginal discharge associated with intense itching. Her husband has history of slight urethral discharge. A pelvic examination confirmed strawberry spots on the cervix.

Which one of the following is the most appropriate treatment?

A. Progestogen cream

B. Sulfonamide cream

C. Estrogen cream

**D. Metronidazole

Single-dose PO metronidazole or tinidazole for both partners
Treatment of partners; otherwise, a "ping-pong effect"

A 3-year-old girl presents to the Emergency Department with vaginal bleeding and pain. Her mother reports that has been passing stools in her pants for 2 weeks despite being toilet trained. On examination, there is bruises on with blood staining labia majora (see lab results).

Test Result Normal Values
Hb 120 112-165 g/L
WBC 9.4 4-10.5 x 109/L
Platelet count 344 150-400 x 109/L
Prothrombin time 13 12-14 sec
APTT 36 30-40 sec

Which of the following is the most likely diagnosis?

**A. Sexual abuse

B. Herpetic vaginitis

C. Precocious puberty

D. Gonorrheal vaginitis

A 33-year-old woman was referred to the Gynecology Clinic because of secondary infertility. Detailed clinical history revealed that she has history of severe dysmenorrhea.

Which of the following will typically be the cause of her dysmenorrhea?

A. Ovarian thecoma

B. Ovarian fibroma

**C. Endometriosis

D. Leiomyoma

Endometriosis is the implantation of endometrial tissue outside of the endometrial cavity. Although the endometrial tissue can implant anywhere, the most common sites are the ovary and pelvic peritoneum.

Dysmenorrhea and dyspareunia are common in endometriosis.

Dx : Laparoscopy

Rx : NSAIDS
Danazol
Leuprolide

A 25-year-old woman complained of crampy, lower abdominal pain that occurs during the first day of her menses and usually improves by the third day. Her periods is regular and all clinical assessment and pelvic ultrasound within normal.

Which of the following most likely explains her clinical presentation?

A. Adenomyosis

B. Endometriosis

**C. Primary dysmenorrhea

D. Pelvic inflammatory disease

ADENOMYOSIS

- Basalis
- Functionalis

Adenomyosis is the invasion of endometrial glands into the myometrium, and it commonly occurs in women age 35–50. Risk factors are endometriosis and uterine fibroids. Symptoms include dysmenorrhea and menorrhagia.

Adenomyosis is a clinical diagnosis. On physical examination the uterus is large, globular, and boggy.

MRI is the most accurate test. Treatment is hysterectomy (the onl definitive treatment and the only way to definitively diagnose adenomyosis).

A 19-year-old girl complained of recurrent painful menstruation that starts on day one of her menses and subsides between day 3 to 4. The pain is severe enough to affect her daily activities and school attendance. All investigations were negative. She was started on non-steroid anti-inflammatory drugs, her pain severity became less and she was able to resume normal function during menses. The patient is still not satisfied and insisting to receive a stronger pain killer.

Which of the following is an appropriate management?

A. Addition of diazepam

**B. Counseling and education on self-care

C. Addition of magnesium tablets orally

D. Uterine tocolytics during pain episodes

A 53-year-old woman has missed her period over the last 12 months.

Which of the following hormones is likely to be altered as a result of the condition?

A. Serum estradiol

Δ MENOPAUSE

The oocytes produce less estrogen and progesterone, and both the LH and FSH start to rise.

↑ FSH → diagnostic
↑ LH

B. Serum testosterone

C. Serum progesterone

**D. Follicular stimulating hormone

A 45-year-old woman has undergone a total abdominal hysterectomy and bilateral salpingo-oophorectomy for a benign reason. Immediately post operation, she started to have acute vasomotor symptoms. Accordingly, she was counselled for hormone replacement therapy and agreed.

Which of the following is the most appropriate hormone replacement therapy regimens?

A. Transdermal estrogen only patches

B. Levonorgestrel-releasing intrauterine device

**C. Cyclical estrogen and progesterone replacement

D. Continuous estrogen and progesterone replacement

HRT is associated with endometrial hyperplasia and can lead to endometrial carcinoma. For this reason, HRT use is limited to 5 years.

CTG Deceleration

A primigravida woman at 32 weeks' gestation brought to the Emergency Room with vaginal bleeding and abdominal pain. On examination: Fundal height equals to 30 weeks and abdomen is tense. Cardiotocography revealed fetal tachycardia, reduced variability and late decelerations.

Which of the following is the most likely diagnosis?

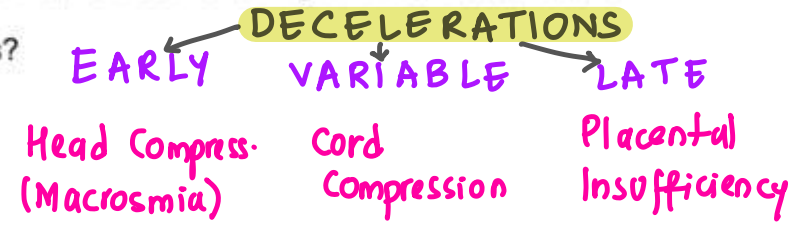

**A. Abruptio placenta

B. Placenta previa

C. Cervical polyp

D. Vasa previa

A 25-year-old woman complained of recurrent behavioral symptoms that started few days before her menstrual cycles and usually disappeared around the second day of the cycle. These symptoms have led to reduced work productivity, increased work absenteeism, and increased visits to ambulatory healthcare.

What is the most common affective or behavioral symptom for her diagnosis?

A. Irritability

**B. Mood swings

C. Depressed mood

D. Anxiety and tension

A 25-year-old woman complained of recurrent behavioral symptoms that started few days before her menstrual cycles and usually disappear around the second day of the cycle. These symptoms have led to reduced work productivity, absenteeism from work, and increased visits to ambulatory healthcare.

Which of the following is the most reliable method to establish the diagnosis?

A. Serum progesterone

B. Pelvic ultrasonography finding

**C. Clinical symptoms

D. Cerebrospinal fluid analysis

PAP

A 35-year-old healthy woman attended the Gynecological Clinic for her regular Pap smear screening. Upon speculum pelvic examination, the uterine cervix appeared raised irregular mass measuring 10 X 12 mm localized on the cervix left lateral aspect.

Which of the following is the most appropriate next step?

A. Excise the lesion

**B. Tissue biopsy from the mass

C. Human papilloma virus infection test

D. Reassurance until the pap smear result

SCC
Colposcopy

A 38-year-old woman attended Outpatient Clinic complaining of fresh vaginal bleeding occurring after each intercourse. This problem has been disturbing her over the last 3 months. Upon examination, her speculum examination revealed normal cervix. The report of Pap smear is showing squamous cell carcinoma.

Which of the following is the most appropriate next immediate action?

A. Radiotherapy

B. Neo-adjuvant chemotherapy

C. Total abdominal hysterectomy

**D. Colposcopy directed cervical biopsy

Endometrioma

A 39-year-old woman, who is a mother of 3 children and has completed her family, she is a known case of endometrioma in the right ovary that has been removed 2 years ago. She came to the clinic complaining of mild to moderate dysmenorrhea and deep pain during intercourse along with her chronic lower abdomen pain.

Pelvic ultrasonography revealed the presence of left ovarian cyst measuring 6X7 cm that appeared to be an endometriotic cyst.

Which of the following is the most appropriate next step?

A. Removing the cyst when the size becomes more than 10 cm

B. Aspiration of the content of cyst under ultrasound guidance

C. Total abdominal hysterectomy and bilateral salpingo-oophorectomy

**D. Removing the cyst laparoscopically with ablation of any endometriotic spot

A 35-year-old woman delivered her fifth baby by vacuum extraction due to prolonged second stage of labor 3 months ago. The woman was complaining of leakage of urine when she

coughed, sneezed or laughed. The symptoms have started after delivery and persisted since then.

Which of the following is the most likely diagnosis?

A. Detrusal instability

**B. Stress incontinence

C. Urethro-vaginal fistula

D. Over flow incontinence

Fibroid ' Leiomyosarcoma

A post-menopausal woman undergoing tamoxifen treatment for breast cancer, she had her last gynecological assessment by ultrasonography during her pre-menopausal period 5 years ago. At that time, she had intramural uterine fibroid measuring 2 x 3 cm. The patient complained of on and off moderate amount of vaginal bleeding and her ultrasound confirmed intramural uterine fibroid measuring 5 x 8 cm and homogenous endometrium 5 mm in thickness.

Which of the following is the most likely diagnosis?

A. Leiomyoma

**B. Leiomyosarcoma

C. Endometrial adenocarcinoma

D. Metastatic ovarian carcinoma

...

Lioyoma → if increased size After menopause → Lieomyosarcoma

Post menopausal women with a history of fibroid "certain size" increased ,what's the diagnosis "endometrium were 5mm (normal ≤5mm) pt on tamoxifen"

A. Leiomyosarcoma ✅ B. Endometrial cancer C. Adenomyosis

Symptoms include heavy, irregular menstrual bleeding with pelvic pain and pressure. These tumors are hormonally sensitive—growing in pregnancy and shrinking with menopause.

so if no shrinkage ± MENOPAUSE think LEIOMYOSARCOMA.

Fibroid

A 48-year-old asymptomatic woman attended the Gynaecology Clinic for her Pap smear screening. During pelvic examination, pelvic mass was felt, further assessment by transvaginal ultrasonography indicated the presence of solitary uterine fibroid on the uterine fundus measuring 5 x 6 cm.

Which of the following is the most appropriate management?

A. Immediate myomectomy

B. Immediate hysterectomy

**C. Regular follow up with yearly pelvic ultrasound

D. Regular follow up with pelvic ultrasound and complete blood count every two months

A 16-year-old girl is complaining of infrequent cycle occurring once every 6 to 8 weeks.

Which of the following is most likely the cause?

A. Endometrial hyperplasia

B. Ovarian mucinous cystadenoma

**C. Physiological variation in menstrual period timing

D. Uterine benign masses in particular uterine fibroids

A 24-year-old woman is complaining of failure to conceive over the last 16 months despite

regular intercourse. She has infrequent menstruation occurring once every 6 to 8 weeks, with increased facial hair and acne. On ultrasound, her ovaries had multiple small follicles each is 2-5 mm in diameter on the surface.

Body mass index 37 kg/m2

Which of the following is the most likely diagnosis?

**A. Polycystic ovarian syndrome

B. Premature ovarian failure

C. Adrenocortical tumor

D. Hypothyroidism

A 24-year-old woman is complaining of failure to conceive over the last 16 months despite regular intercourse. She has infrequent menstruation occurring once every 6 to 8 weeks along with increased facial hair and acne. On ultrasound, her ovaries had multiple small follicles each is 2-5 mm diameter on the surface. She indicated that her main aim is getting pregnant.

Body mass index 37 kg/m2

Which of the following is the initial step in management?

A. Weight reduction, danazol and metformin

**B. Weight reduction, metformin and clomiphene citrate

C. Weight reduction, in vitro fertilization and salicylic acid

D. Weight reduction, laparoscopic ovarian wedge resection and metformin

Ovarian tumor

A 45-year-old woman comes to the clinic complaining of loss of appetite, bloating and abdominal pain. Clinical assessment and investigations confirmed the presence of moderate ascites, pleural effusion and bilateral ovarian masses. Cancer antigen 125 (CA 125) was 95 unit/ml.

Which of the following is the most likely diagnosis?

A. Sex cord stromal ovarian tumor

B. Ovarian germ cell tumor

**C. Epithelial ovarian tumor

D. Gonadoblastoma

Ovarian Cancer

There is no screening test for ovarian cancer.

Look for a woman age >50 with increasing abdominal girth who is still losing weight. BRCA is associated with ovarian cancer.

The best initial test is an ultrasound or CT scan. The most accurate diagnostic test is a biopsy. CA-125 is not for screening; it is used only for follow-up of treatment.

Ovarian cancer is the only cancer in which removing large amounts of locally metastatic disease will benefit the patient. Remove all visible tumor and pelvic organs and give chemotherapy. PARP inhibitors are especially effective in ovarian cancer.

A 45-year-old woman comes to the clinic complaining of loss of appetite, bloating and abdominal pain. Clinical assessment and investigations confirmed the presence of moderate ascites, pleural effusion and bilateral ovarian masses. Cancer antigen 125 (CA 125) was 100 unit/ml.

Which investigation is the most helpful in making a diagnosis?

A. Tumor markers

**B. Tissue histopathology

C. Genetic testing for hereditary cancers

D. Magnetic resonance imaging of the pelvic soft tissue

PCOS

A 25-year-old woman complains of velvety, hyperpigmented plaques on her neck and under arm. She fails to conceive over the last 2 years despite regular intercourse. Her menses are infrequent and occurring once every 6 to 8 weeks. She notices recently increased facial hair. Her husband is healthy with a normal seminal analysis.

Which of the following is the most likely diagnosis?

A. Diabetes mellitus

B. Internal malignancy

**C. Polycystic ovarian syndrome

D. Systemic lupus erythematous

Acanthosis Nigricans

A 25-year-old woman complains of velvety, hyperpigmented plaques on her neck and axillae. She fails to conceive over the last 2 years despite regular intercourse. Her menses are irregular and occurring once every 6 to 8 weeks. She starts recently to experience increased facial hairs.

What is the appropriate term of her skin hyperpigmentation?

**A. Acanthosis nigricans

B. Linea nigra

C. Melanoma

D. Stria

A 26-year-old married woman presents to Endocrinology-Gynecology clinic for a follow-up of her investigation results. Accordingly, a polycystic ovarian syndrome is made. She is counselled about plan of management and metformin use in her condition.

What does metformin do in the above condition?

A. Anti-androgen effect

**B. Reducing insulin resistance

C. Increasing P450 in the liver

D. Lowering blood sugar by increasing consumption

Polymenorrhagia

A 47-year-old woman, poorly controlled diabetic, complains of polymenorrhagia every couple of weeks.

Body mass index 37 kg/m2

Which of the following is most appropriate investigation to establish the diagnosis?

A. Coagulation profile

**B. Endometrial biopsy

C. Ultrasonography of the pelvis

D. Magnetic resonance imaging of the pelvis

Mass protruding
Uterine prolapse

A 55-year-old woman comes to the Gynaecology Clinic complaining of a mass protruding through her vagina when standing for quite sometimes especially during cough and straining. She has 7 children that were delivered vaginally. The last delivery was complicated by prolonged second stage and ended up with vacuum extraction delivery of a 4.2 Kg baby.

Which of the following is the most appropriate next step?

A. Bonney's test

B. Uro-dynamic studies

C. Retro grade cysto-urethrogram

**D. Speculum examination of vagina

Labour Progression

A 30-year-old woman G2 P2002 at 32 weeks' gestation presents to Emergency Department complaining of lower abdominal and back pain, which has increased in frequency and intensity over the last few hours. Abdominal examination shows fundal height equals to 32 cm, longitudinal lie fetus and cephalic presentation. Fetal heart was positive and cardiotocography is reactive with 2-3 uterine contractions per 10 minutes. Vaginal examination shows 1 cm dilated cervix, 70% effacement, -3 station and cephalic.

Which of the following is the most appropriate step in management?

A. Inform neonatologist, administer corticosteroids and strict bed rest

**B. Inform neonatologist, administer corticosteroids and hydrate the patient → for lungs maturation

C. Inform neonatologist, administer tocolytics and start intravenous antibiotics

D. Inform neonatologist, administer intravenous antibiotics and strict bed rest

Labour

A 30-year-old woman G2 P2002 at 32 weeks' gestation presents to Emergency Department complaining of lower abdominal and back pain which has increased in frequency and intensity over the last few hours. Abdominal examination shows fundal height equals to 32 cm, longitudinal lie fetus and cephalic presentation. Fetal heart was positive and cardiotocography is reactive with 2-3 uterine contractions/10 minutes. Vaginal examination shows 1 cm dilated cervix, 70% effacement, -3 station and cephalic.

Which of the following is the next step to confirm the diagnosis?

A. Continuous cardiotocography

B. Lecithin-sphingomyelin ratio

**C. Repeat vaginal assessment in two hour-time

D. Cervical length assessment by ultrasound scanning

Preterm
Progesterone
Cervical length
Cervical Incompetence
Ala Obs

A 23-year-old woman G3 P02002 at 20 weeks' gestation with history of previous 2 preterm deliveries attends Antenatal Clinic. Current pregnancy is uneventful. An ultrasound shows size correspond to date, anterior placenta and cervical length is 30 mm.

Which of the following is the most appropriate intervention?

A. Strict bed rest till term

B. Immediate cervical cerclage → cervical length < 25mm, < 24 wk (13-16 wk)

C. Aspirin 81 mg oral tablet daily

**D. Progesterone supplementation → To reduce risk of PRETERM birth

A 26-year-old woman G2 P1001 admitted to the hospital in active labor and ruptured membranes at 38 weeks of gestation. Upon vaginal examination, the cervix was 6 cm dilated and 1 cm long. The orbital ridge and orbits, saddle of the nose, mouth, and chin were palpable.

What is the scientific term for this fetal presentation?

A. Compound presentation

B. Cephalic presentation

C. Brow presentation

**D. Face presentation

Leopold
Bicornuate
Breech

A primigravida at 37 weeks gestation known to have bicornuate uterus complains of subcostal discomfort and fetal kicking is appreciated in the lower abdomen mainly. Leopold maneuver; shows global soft presenting part with sluggish ballottement by first and second pelvic grips. Fetal heart detected at the level of maternal umbilicus.

Which of the following is the most likely fetal presentation?

A. Face presentation

B. Brow presentation

**C. Breech presentation → C/S

D. Shoulder presentation

A primigravida at 37 weeks gestation known to have bicornuate uterus complains of subcostal discomfort and fetal kicking is appreciated in the lower abdomen mainly. Leopold maneuver; shows global soft presenting part with sluggish ballottement by first and second pelvic grips. Fetal heart detected at the level of maternal umbilicus.

What is the recommended method of delivery if this fetal presentation persisted?

A. Spontaneous vaginal delivery

B. Ventouse delivery

C. Forceps delivery

**D. Cesarean section

ECV Contraindications

A 32-year-old woman G3 P2002 presented at 38 weeks' gestation to Antenatal Clinic. She has had history of 2 previous normal deliveries of 3 Kg babies. Current pregnancy, fetus found to be breech in presentation. The patient was counselled and consented for external cephalic version. On the scheduled day, an estimated fetal weight is 2.6 Kg by ultrasound, flexed fetal head, and uterus is bicornuate with average liquor measured.

Which of the above findings is contraindicated external cephalic version?

A. Flexed fetal head

**B. Bicornuate uterus

C. Average liquor

D. Fetal weight

Ala Obs Gynae
Eclampsia
Gestational HTN

A 24-year-old primigravida is found during antenatal care at 22 weeks gestation to have a blood pressure of 140/95 mmHg in 2 different measurements documented 4 hours apart. Her urine test for protein was negative and she was asymptomatic.

Which of the following is the most likely diagnosis?

<20 wk → Essential HTN >140/90

A. Preeclampsia (if protein +ve + HTN >20 wk)

>20 wk → Gestational HTN >140/90

B. Chronic hypertension

Rx: Methyldopa (1st line)

**C. Gestational hypertension

D. Transient hypertension of pregnancy

HELLP

A 30-year-old woman G2 P1001 at 32 weeks' gestation is admitted to labor and delivery complaining of lower abdominal and back pain. She has a significant previous history of severe preeclampsia (see lab results).

Blood pressure 140/90 mmHg

Test Result Normal Values
Platelets count 80 150-400 x 109/L
Uric Acid 460 140-360 µmol/L

Which of the following findings would indicate severe preeclampsia?

A. Abdominal pain

B. Blood pressure

C. Uric acid level

**D. Platelet count

Ala Obs Gynae
Pre Eclampsia

A 38-year-old woman G3 P2002 at 34 weeks' gestation is admitted to labor and delivery complaining of headache, epigastric pain and blurred vision. Non-stress test is reassuring.

- >160/110 PRE-ECLAMPSIA & severe :-
- Mental status changes
- Vision changes
- RUQ pain
- Headache

Rx :-
- Methyldopa → to prevent Eclampsia
- Labetolol → control BP
- Delivery

Blood pressure 170/120 mmHg

Which of the following is the most appropriate management?

A. Inform anesthesia and deliver the patient immediately

**B. Stabilize general condition, administer magnesium sulfate and deliver the patient

C. Administer magnesium sulfate, stabilize general condition and wait till 37 weeks' gestation

D. Stabilize general condition, administer corticosteroids and deliver the patient

Abortion

A 24-year-old woman presents at 7 weeks' gestation complaining of mild vaginal bleeding and lower abdominal pain colicky in nature. Upon examination; normal vital signs and speculum examination shows the cervix is closed and fresh bleed coming through the cervix.

Which of the following is the most likely cause of the bleeding?

A. Septic abortion

B. Inevitable abortion

C. Incomplete abortion

**D. Threatened abortion

A 22-year-old primigravida at 7 weeks' gestation is brought to Emergency Department complaining of moderate vaginal bleeding with passage of tissue like material and lower abdominal colicky pain. Speculum examination; tissue is in the vagina, uterine cervix is opened and admitting one finger. Product of conception is protruding through cervical canal. Bimanual examination reveals bulky uterus corresponding to seven-eight weeks gestation. Adnexa were free and there was no cervical excitation.

Which of the following is the most likely diagnosis?

A. Inevitable abortion

**B. Incomplete abortion

C. Threatened abortion

D. Complete molar pregnancy

A woman presents at her 9th week of pregnancy with severe vaginal bleeding, lower abdominal pain and passage of the fetus through the vagina. On vaginal examination; cervix is open and tissue seen in the cervix.

Which of the following the most appropriate management?

**A. Fluid replacement and evacuation and curettage

B. Fluid replacement and expectant management

C. Fluid replacement and uterine massage

D. Fluid replacement and hysterectomy

A 40-year-old woman has just delivered her 7th child at 38 weeks with 4 kg baby boy vaginally 10 minutes ago. The placenta is still in place and she starts to bleed profusely. The estimated amount of blood loss visually is around 800 ml.

Which of the following best describes this case?

Early
< 24 hours

Late
24 hr – 12 wk

A. Secondary post-partum hemorrhage

B. Iatrogenic post-partum hemorrhage

Cause: Uterine Atony (80% cases)

**C. Primary post-partum hemorrhage

Rx: bimanual compression, massage
Oxytocin

D. Tertiary post-partum hemorrhage

A 38-year-old G9 P8008 woman presented at 38 weeks gestation in labor and diagnosis of prolonged 2nd stage of labor was entertained and finally delivered 4.3 Kg baby by vacuum extraction. Anticipated management was taken because of risk of postpartum hemorrhage and hypovolemic shock.

Which of the following is considered a best reliable indicator of above complications?

A. Visual estimation of blood loss

**B. Maternal pulse rate

C. Hemoglobin level

D. Hematocrit level

A 37-year-old woman G8 P7017 at 36 weeks' gestation has history of recurrent postpartum that required blood transfusion. She has no significant medical problem.

Which of the following is the most appropriate preventive measure at delivery?

A. Deliver the patient in the operating room

B. Perform an elective cesarean section at 38 weeks gestation

**C. Perform active management of 3rd stage of labor / Reduce maternal stress & Labour duration

D. Give the patient preload of crystalloid fluids while in labor to overcome the possible post-delivery hypovolemia

A 14-year-old healthy girl has painless vaginal bleeding occurring at interval of 3 weeks to 2 months. The bleeding usually lasts 2 to 4 days, not preceded by premenstrual symptoms and not associated with clots. Review of systems is not significant. Physical examination shows a normal appearing pubertal girl along with normal development of secondary sex characteristics (see lab results).

Test Result Normal Values
Hemoglobin 120 112-165 g/L
RBC 6 4.6-4.8 x 1012/L
WBC 4.8 4.5-10.5 x 109/L
Platelets count 220 150-400 x 109/L
Pregnancy test Negative

Which of the following is the most appropriate management?

A. Follicle stimulating hormone and prolactin

B. Oral contraceptives pills

C. Metformin

**D. Reassure

A 50-year-old woman presented with amenorrhea for the last 6 months and has unwanted hot flushes disturbing her night sleep.

Which of the following serum levels would confirm the diagnosis?

**A. Follicle stimulating hormone

B. Luteinizing hormone

C. Progesterone

D. Oestrogen

A 22-year-old primigravida presented at 38 weeks' gestation in labor. Vaginal examination showed 7cm dilated cervix, full effacement and vertex. An hour later the obstetrician noticed a loop of the umbilical cord below the fetal head.

Foetal Heart Rate 120 beat/min

Which of the following is the most appropriate immediate management?

A. Vacuum extraction

**B. Cesarean section

C. Forceps delivery

D. Fetal monitoring

Labour
Oxytocin

A 30-year-old woman G2 P1002 admitted at 40 weeks' gestation with onset of labor and ruptured membranes. Her cervix was 5 cm dilated and 100% effaced with 0 station vertex for 3 hours. A fetal monitoring strip showed 2 contractions in 10 minutes with a reassured non-stress test.

Which of the following is the most appropriate management?

**A. Augmentation with oxytocin

B. Prostaglandin E1 analogue

C. Continue observation

D. Dinoprostone

A 33-year-old woman presents with a history of amenorrhea for a year following dilatation and curettage because of abnormal uterine bleeding. She underwent to both progesterone and combined estrogen and progesterone withdrawal tests with no response. Her serum FSH level was normal.

Which of the following syndromes is the most likely diagnosis?

A. Kallman

6th June Exam DHA

B. Sheehan

**C. Asherman

D. Polycystic ovarian

A 25-year-old woman was brought to the Emergency Department 7 weeks after her last menstruation with positive pregnancy test. Abdominal and transvaginal ultrasound showed no intrauterine pregnancy sac. She has lower abdominal pain, mostly on the left side and mild vaginal bleeding.

Which of the following is the most probable diagnosis?

A. Ruptured corpus luteum

**B. Extra uterine pregnancy

C. Twisted ovarian cyst

D. Molar pregnancy

A 29-year-old woman G7 P5015 is admitted at 30 weeks' gestation in labor room with leaking liquor for observation.

Which of the following most likely confirm the diagnosis?

A. Chemical examination of liquor

B. Bimanual vaginal examination

**C. Sterile speculum examination

D. Ultrasound examination

Antenatal visit

A 28-year-old woman G5 P3013 is seen in the Antenatal Clinic. Her previous pregnancies were term normal deliveries. Currently, she is 10 weeks' gestation confirmed by a pregnancy test and ultrasound examination.

Which of the following is the most important purpose of the first antenatal visit?

A. Identify the risk factors

B. Confirm viable pregnancy

**C. Confirm the gestational dating

D. Estimate the hemoglobin level

A 28-year-old healthy woman presents to her gynecologist with history of inability to conceive after 2 years of trying. Menarche at 13-year-old, regular cycles every 36-40 days and 5-day periods. Not on any medications. Semenanalysis of husband showed normospermia. Cervical component examination is required. The basal body temperature showed a monophasic pattern.

Which of the following is the most probable cause of the infertility?

A. Pelvic inflammatory disease

B. The coital factor

C. Vaginal factor

**D. Anovulation

A 25-year-old woman G5 P2022 presented to the clinic at 10 weeks' gestation with painless vaginal bleeding. During her hospital admission, she developed heavy vaginal bleeding and lower abdominal pain. She has noticed passage of tissue. On examination, mild pain, vital signs normal. Pelvic examination showed trickling blood through cervix and os is open.

Which of the following is most likely diagnosis?

A. Inevitable abortion

**B. Incomplete abortion

C. Threatened abortion

D. Septic incomplete abortion

A 45-year-old woman who has had last normal pregnancies 15 years ago presents with amenorrhea for 7 months duration. Pregnancy test is negative. She expresses her desire to become pregnant again.

Which of the following is most appropriate investigation?

**A. LH and FSH levels

B. Endometrial biopsy

C. Hysterosalpingogram

D. Thyroid function tests

Superimposed Pre eclampsia

A 39-year-old primigravida attended her routine prenatal visit at 39 weeks' gestation. She denied any headache, visual changes, nausea, vomiting or abdominal pain. Urinalysis was negative for protein (see lab results).

Vital signs at this visit: Blood pressure 160/90 mmHg
Heart rate 84 /min

Vitals signs at all other visits: Blood pressure 120/70 mmHg
Heart rate 68 /min

Test Result Normal Values

HCT 0.34 0.37-0.48
Platelets count 165 150-400 x 109/L
Alanine aminotransferase 12 5-40 IU/L
Aspartate aminotransferase 22 12-40 IU/L

Which of the following is the most likely diagnosis?

A. Eclampsia

B. Chronic hypertension

**C. Gestational hypertension

D. Superimposed preeclampsia

A 33-year-old woman presented to the Emergency Department with severe lower abdominal pain. On examination, abdomen was diffuse tenderness, more in the lower quadrants. Bimanual pelvic exam showed bilateral adnexal masses and palpable. A diagnosis of bilateral tubo-ovarian abscesses was entertained.

Blood pressure 130/70 mmHg
Heart rate 100 /min
Respiratory rate 22 /min
Temperature 39.9° C

TOAs are usually polymicrobial and contain a mixture of aerobic, facultative, and anaerobic bacteria.

Which of the following is the most appropriate next step in management?

Rx I/V Antibiotics
cefoxitin and doxycycline
or in penicillin-allergic patients: clindamycin and gentamicin
- If there is no improvement with antibiotics alone in 48–72 hours or
- when abscess is large (>9 cm)
do image-guided percutaneous drainage.

A. Exploratory laparotomy

**B. Intravenous antibiotic therapy

C. Emergent laparoscopic drainage

D. CT-guided percutaneous drainage

Labour
Face presentation

A 25-year-old woman G2 P1001 was admitted at 39 weeks' gestation in Labor Suite with labour pains. On Abdominal examination, 3 moderate contractions every 10 minutes. The cervix was 6 cm dilated, 80% effaced. Mouth, lips, nose and orbital hollows were palpable.

Which of the following is the most appropriate next step in management?

A. Advise CT pelvimetry

B. Emergency caesarean section

C. Augment labour with oxytocin

**D. Monitor partographic progress

A 26-year-old woman presented to the clinic with secondary amenorrhea of 6 months duration. She gave history of breast tenderness. On examination; bilateral breast whitish discharge from nipples. Her urine pregnancy test was negative and elevated serum prolactin levels.

Which of the following radiological assessment is most appropriate?

A. Lumbar spine

**B. Sella-turcica

C. Kidneys

D. Pelvis

A 20-year-old pregnant woman presented with loss of fetal movements, followed by decreased urinary output and difficulty breathing (see lab results and report).

Test Result Normal Values
Hb 100 120-160 g/L
DLCO 70 75-140%
Platelets count 75 150-400 x 109/L
Creatinine 105 44-115 µmol/L
Prothrombin time 24 10-13 sec
APTT 60 30-40 sec
Fibrinogen 1.6 2-4 g/L

Chest X-ray:
Diffuse ground glass opacities. → Grey Hazy areas (Embolism one of cause)

Which of the following is the most appropriate diagnosis?

A. Acute glomerulonephritis

**B. Acute amniotic embolism

C. Disseminated intravascular coagulation

D. Autoimmune thrombocytopenic purpura

- Acute Amniotic Embolus
- Abruptio Placenta

} can lead to DIC

A 16-year-old presented to the clinic for evaluation of primary amenorrhea. Examination showed normal adult-size breasts. But coarse pubic and axillary hair (see lab result).

Androgen insensitivity

Test Result Normal Value
Testosterone 13.86 0.7-2.8 nmol/L

Which of the following is the most likely diagnosis?

A. Mayer-Rokitansky-Kuster-Hauser syndrome

**B. Complete androgen insensitivity syndrome

C. Asherman's syndrome

D. Turner syndrome

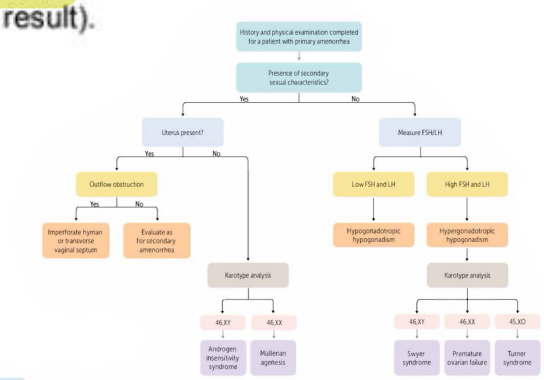

FIGURE 2.11-2. **Workup of primary amenorrhea.** (Reproduced with permission from USMLE-Rx.com.)

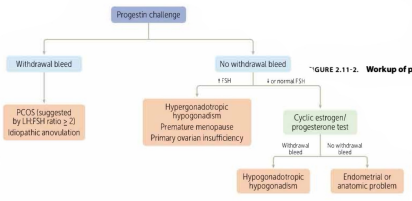

FIGURE 2.11-3. **Workup of secondary amenorrhea.** (Reproduced with permission from USMLE-Rx.com.)

A 14-year-old child presented to the clinic after being sexually abused 6 hours earlier. Genital examination confirmed anogenital erythema and mild bleeding vaginally, and labia majora was swollen and bruised.

Blood pressure 120/70 mmHg
Heart rate 90 /min

Respiratory rate 20 /min
Temperature 36.6° C

What is the most likely site of hymeneal tear that is suggestive of penile penetration?

A. 2 o'clock

B. 4 o'clock

**C. 6 o'clock

D. 8 o'clock

Infertility
Progesterones
Day 21

A young couple has been trying to conceive a baby for 6 months with no success. The wife has regular cycles every 23 days and 4-day periods.

Which of the following is most appropriate investigation?

A. Serum TSH

B. Serum prolactin

C. Urinary FSH / LHS

**D. Day 21 progesterone

A 19-year-old woman presented with crampy, lower abdominal pain beginning with the onset of menses every month, and lasting for 2 to 3 days. There was no pain between menses, but reported radiation of pain to the lower back and upper thighs, along with nausea, fatigue, and headache which has been present for several years and progressively getting worse. Physical examination normal.

Which of the following is the most likely diagnosis?

A. Secondary dysmenorrhea

B. Premenstrual syndrome

**C. Primary dysmenorrhea

D. Endometriosis

Nodularity
Regular and heavy
Endometriosis

A 24-year-old married nulliparous has an 18-month history of cyclic, debilitating pelvic pain related to menses which are regular and heavy requiring 10-15 thick pads on the days of heaviest flow. For the past year, the patient has been engaging in regular intercourse without contraception in an attempt to conceive. Pelvic examination showed normal-size, immobile, retroverted uterus with nodularity and tenderness on palpation of the uterosacral ligaments.

Which of the following is the most likely diagnosis?

A. Pelvic inflammatory disease

B. Uterine fibroids

**C. Endometriosis

Endometriosis presents with:

- Cyclical pelvic pain that starts 1–2 weeks before menstruation, peaks 1–2 days before menstruation, and ends with menstruation
- Abnormal bleeding (common)
- Physical exam finding of nodular uterus and adnexal mass

D. Adenomyosis

A 27-year-old nulliparous presents for a routine examination. Her gynecological history indicates a 5-year history of oligomenorrhea with only about 2-3 menses a year. She denies inter-cycle spotting or premenstrual symptoms. The last menses was 3 months ago. The physical examination confirmed a moderate amount of facial hair and inflammatory acne while the pelvic examination is normal.

Weight 60 kg
Blood pressure 120/75 mmHg
Heart rate 72 /min
Respiratory rate 17 /min

Which of the following is the most likely diagnosis?

**A. Polycystic ovary syndrome

B. Hyperprolactinemia

C. Hypothyroidism

D. Hypopituitarism

A 27-year-old nulliparous is concerned about not having conceived after a year of regular, unprotected intercourse. The patient denied any major medical illnesses and takes no medications. The patient's spouse is reported to be healthy but has never fathered a child.

What is the most appropriate initial step in evaluation after history and examination?

**A. Referral to a reproductive specialist

B. Basal body temperature charting

C. Hysterosalpingogram

D. Semen analysis

A 25-year-old nulliparous presented with an 18-month history of cyclic and debilitating pelvic pain related to menses. Menses is regular and heavy, requiring 10-15 thick pads on the days of heaviest flow. The patient has been engaging in regular intercourse without contraception for 1 year in an attempt to conceive. Pelvic examination revealed a normal-sized, immobile, retroverted uterus with nodularity and tenderness on palpation of the uterosacral ligaments.

Which of the following would most likely help in the diagnosis?

A. Ultrasound

**B. Laparoscopy

C. Hysteroscopy

D. Hysterosalpingogram

A 48-year-old woman nulliparous presented to the Emergency Department with heavy vaginal bleeding associated with slight dizziness. No other significant past medical history except heavy menstruation in the past few months. The examination was normal apart from the presence of a

large amount of blood in the vaginal vault (see lab results).

Supine
Blood pressure 110/70 mmHg
Heart rate 90 /min

Standing
Blood pressure 104/66 mmHg
Heart rate 100 /min
Temperature 36.6° C

Test Result Normal Values
Hb 10 120-160 g/L
Pregnancy test -ve

- > 45 with abnormal uterine bleeding --> endometrial Biopsy by D&C --> normal endometrial biopsy? Give OCP
- <45 --> o start therapy by COCP or medroxyprogestine.

Which of the following is the first step in management?

In Acute Hemorrhage: D & C (to stop bleeding)

A. Non-steroidal anti-inflammatory agents

B. Medroxyprogesterone

**C. Conjugated estrogen

D. Blood transfusion

- If Anemic
- Not controlled on OCPs → Endometrial Ablation / Hysterectomy

Dysfunctional uterine Bleeding

A 41-year-old patient presents to the Gynaecological Clinic with heavy bleeding. After a complete evaluation, the gynaecologist determines the patient has dysfunctional uterine bleeding.

Which of the following is the first step in management?

A. Dilation and curettage

**B. Oral contraceptive pill

C. Endometrial ablation

D. Hysterectomy

NSAIDS

A 14-year-old girl has a 6-month history of lower mid-abdominal pain colicky in nature, radiates to the back and upper thighs. It often begins with onset of menses which lasts for 2-4 days. She has missed several days of school during the last 2 months because the severity of pain. Physical examination is normal for abdomen and pelvis. Normal secondary sexual development is also noted.

Which of the following is the first step in management?

**A. Nonsteroidal anti-inflammatory drugs

B. Oral contraceptive pills

C. Acetaminophen

D. Clomiphene

SSRI

A 23-year-old woman presented with breast tenderness, abdominal bloating, and food cravings. She has a 6-month history of tiredness, anxiety, emotional lability, difficulty concentrating and insomnia. There are no menstrual irregularities or prodromal life stressors. The symptoms recurred on a regular basis during the week leading up to the menstrual period but completely resolve within the first 3 days of menses. The patient felt totally incapacitated when symptomatic, and the symptoms adversely affect personal and professional life.

Which of the following is the best-evidenced treatment?

**A. Selective serotonin uptake inhibitors

B. Oral medroxyprogesterone acetate

C. Progesterone vaginal suppositories

D. Transdermal estrogen patches

A 22-year-old married woman has had severe, recurrent depression associated with multiple suicide attempts. She has been stabilized for the past 3 months on paroxetine and is now pregnant.

Which of the following is the most appropriate management?

A. Discontinue paroxetine due to avoid prematurity

**B. Continue paroxetine and monitor for depression

C. Discontinue paroxetine to avoid fetal damage

D. Continue paroxetine and add lithium

Abruption

A 32-year-old primigravida at 34 weeks' gestation presents for urgent care after falling down a flight of stairs. The patient complains of uterine tenderness and reduced fetal movement in the 45 minutes since the fall. There has been a small amount of dark red vaginal bleeding. The fetal heart monitoring revealed a heart rate of 150 bpm with irregular uterine contractions every 3 to 4 minutes. Her pregnancy has been uncomplicated. She has positive history of cigarettes smoking.

Which of the following is the most likely diagnosis?

A. Placenta previa

B. Uterine rupture

**C. Placental abruption

D. Latent phase of labor

A 34-week pregnant woman presents in labor with contractions occurring every 4 minutes, she also has vaginal bleeding which is heavier than normal menstrual flow. The fetus is in a back-down position, transverse lie, and the cervix is dilated 3 cm with bulging membranes. The fetal heart rate is 170 bpm. The sonography showed a posterior fundal placenta with a retroplacental sonolucent area.

Which of the following is the most appropriate initial management?

A. Administration of a tocolytic agent

B. Oxytocin augmentation

**C. Caesarean section

D. Amniotomy

34weeks GA pregnant she had **uterine contractions** every -mins the **cervix dilated 3cm** and the **membranes intact** ,the **fetus lying transverse** and has normal FHR, she **had vaginal bleeding on us** the **placenta attached to the posterior fundus** but with retroplacental isolucent, what you will do:
A. Give her tocolytic B. Give her oxytocin C. Cs✔✔ D. Amniotomy

HPV TYPES

A 40-year-old sexually active patient presents for cervical cancer screening. Physical examination is unremarkable, menstruation is regular with a 28-day cycle and last menstrual period was 5 days ago.

Which of the following is the best advice about Pap smear?

**A. Yearly screening recommended

B. Every 5 years is recommended

C. No routine screening recommended

D. Three negative results and no further screening

PAP — ROUTINE SCREEN
↓
- 20–24 yrs (21 yrs)
- EVERY 3 years

* HPV VACCINE
↓
11 – 45 yr

PAP + HPV
- (30 – 65 yrs)
- EVERY 5 YEARS

A 42-year-old obese nulligravida patient with polycystic ovary syndrome has had irregular vaginal bleeding since menarche. She has used no medication to control her periods (see lab results and report).

Test Result Normal Values
Cortisol 8 a.m. 335 138-635 nmol/L
Estrogen 630 90-550 pmol/L
Follicle-stimulating hormone 38 5-20 IU/L
Testosterone 3.1 0.7-2.8 nmol/L
Prolactin 590 < 870 pmol/L
T3 (Total serum) 1.2 0.9-2.8 nmol/L
Thyroxine (T4 Total serum) 82 64- 155 nmol/L
Thyroid-Stimulating Hormone 4.5 0.4 - 5.0 µU/L

HPV types and associations:

- Cervical cancer: 16 and 18
- Condyloma acuminata (genital warts): 6 and 11

Estrogen
Adenomatous hyperplasia

Endometrial Biopsy:
Adenomatous hyperplasia.

Which of the following is the most likely cause of the adenomatous hyperplasia?

A. Human papilloma virus

**B. Unopposed estrogen

C. Cellular apoptosis

D. Menopause

A 42-year-old obese woman presented with a 5-year history of irregular vaginal bleeding. Thyroid studies are normal. She noticed that her irregular in menstruation has started to put on weight (see report).

Body mass index 35 kg/m2

Endometrial Biopsy:

Adenomatous hyperplasia.

Which of the following is the most likely cause?

A. Adrenal hyperplasia

B. Hepatic dysfunction

C. Local genetic mutation of the endometrium

**D. Peripheral conversion of precursors to estrogen

A 43-year-old woman gravida 2 para 2 has had oligoovulation due to polycystic ovary syndrome and used cyclic progesterone for withdrawal bleeding. Approximately 5 years ago, she discontinued taking progesterone.

Which of the following risks is increased?

A. Hip fracture

B. Cervical dysplasia

C. Ectopic pregnancy

**D. Endometrial carcinoma

Hypothyroidism

A 30-year-old woman P1+0 presented to Obstetrics and Gynaecology Clinic complains of inability to conceive for the last 3 years. During that time, she was not on contraceptive and her menstrual periods every 45 days but no period for the last 6 months (see lab results).

Test Result Normal Values
Thyroid-Stimulating Hormone 9.2 µU/L 0.4 - 5.0 µU/L
Follicular phase 5-20 IU/L
Mid cycle peak 15-35 IU/L
Follicle-stimulating hormone 5.3 µU/L Luteal phase 5-15 IU/L
Postmenopausal women 50-100 IU/L
Men 5-20 IU/L
Men 3-15 U/L
Luteinizing hormone 7.2 µU/L Follicular phase 5-22 U/L
Luteal phase 5-22 U/L
Ovulatory phase 30-250 U/L
Postmenopausal Women > 30 U/L
Prolactin 140 ng/ml < 25 ng/ml

Which of the following is the most likely diagnosis?

**A. Hypothyroidism

B. Hypopituitarism

C. Hyperprolactinemia

D. Polycystic ovary syndrome

A young primigravida presents with significant edema of the lower extremities and hands. The patient was admitted for evaluation and management.

Blood pressure 150/95 mmHg
Heart rate 76 /min
Respiratory rate 18 /min
Temperature 36.6° C

Which of the following would be the most appropriate management?

A. Diuretics

B. Low-salt diet

C. Oral labetalol

**D. Continued evaluation

A 30-year-old woman with a history of infertility for 6 years complains of severe dysmenorrhea unrelieved by naproxen.

Which of the following is the most likely diagnosis?

A. Endometritis

B. Leiomyomata

**C. Endometriosis

D. Pelvic congestion

A 40-year-old woman complains of Post-coital bleeding. Speculum examination reveals cervical mass.

Which of the following is the most appropriate next investigation?

A. Pap smear

B. Cone biopsy

C. RNA analysis

**D. Directed biopsy

A 48-year-old obese woman complains of nausea. Patient LMP was 2 months ago. She is using barrier method (condoms) as a birth control method. Examination is normal except for a slight dusky discoloration of her cervix.

Which of the following is the next step in management?

A. Progesterone challenge

B. Pelvic ultrasound

**C. Beta-hCG test

D. Huhner's test

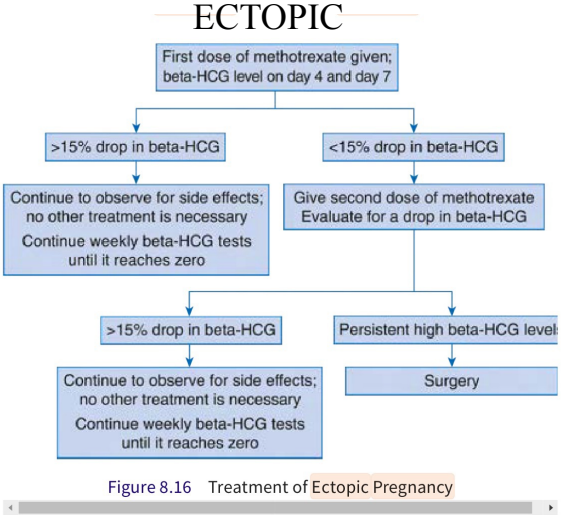
ECTOPIC
First dose of methotrexate given; beta-HCG level on day 4 and day 7
>15% drop in beta-HCG
<15% drop in beta-HCG
Continue to observe for side effects; no other treatment is necessary
Continue weekly beta-HCG tests until it reaches zero
Give second dose of methotrexate
Evaluate for a drop in beta-HCG
>15% drop in beta-HCG
Persistent high beta-HCG level
Continue to observe for side effects; no other treatment is necessary
Continue weekly beta-HCG tests until it reaches zero
Surgery
Figure 8.16 Treatment of Ectopic Pregnancy

A hemodynamically stable woman has a tubal, ectopic pregnancy measuring 2.5 x 3 cm by ultrasound (see lab result).

Test Result Normal Value
Human chorionic gonadotropin N 5000 < 5 mIU/mL

Which of the following is the most appropriate treatment?

A. Laparoscopy

B. Observation

C. Laparotomy

**D. Medical

< 3.5 cm – Medical Rx
> 3.5 cm – Salpingostomy
> 5 cm – Salpingectomy

* Stable → Medical Rx
If fail Medical Rx → Elective Surgery (-ostomy)

* Unstable → IV Fluids → Salpingectomy

Smoking

A 25-year-old woman in her first trimester of pregnancy has come for a routine prenatal visit. She used to smoke one pack of cigarettes per day, and is now being advised to quit smoking.

Which of the following is the greatest risk to her unborn child?

A. Macrosomia

**B. Low birth weight

C. Transient tachypnea

D. Neonatal hypoglycemia

Hydatidiform mole

A 32-year-old woman 16 weeks pregnant presents to the clinic with vaginal bleeding, abdominal enlargement and vomiting for the past 4 days. On examination, the uterine size is larger than expected for the gestational age (see lab result and report).

Test Result Normal Value
Human chorionic gonadotropin 80,000 < 5 mIU/mL

Ultrasound:
"Snowstorm-like" appearance.

Which of the following is the most likely diagnosis?

**A. Complete hydatidiform mole

B. Chorioadenoma destruens

C. Partial hydatidiform mole

D. Choriocarcinoma

Tender mass
Calcification
Laparoscopy

A 30-year-old woman presents to the Gynaecology Clinic with diffuse lower right-sided abdominal pain and low back pain that has been progressively worsening for the past month. The pain intensity worsens after sexual intercourse. Patient menstrual periods occur irregularly and with heavy bleeding. Palpation reveals a tender mass in the lower right quadrant. Ultrasound pelvis scan shows a 9X9 centimetre heterogeneous mass filled with a calcifications.

Which of the following is most appropriate method of treatment?

A. Watchful waiting

B. Dilation and curettage

**C. Operative laparoscopy

D. Methotrexate administration

Spontaneous rupture Membranes

A 28-year-old gravida 3, para 2 presents to Obstetric Triage Unit at 37 weeks' gestation following spontaneous rupture of the amniotic membranes confirmed by physical examination. On admission to labour and delivery room she was complaining of abdominal pain. Digital examination shows a cervical dilation of 4 cm and 80% effacement with the presenting part at 0 station. CTG is reactive with baseline fetal heart of 170 bpm.

Blood pressure 138/78 mmHg
Heart rate 111 /min
Respiratory rate 24 /min
Temperature 38.4° C oral

Which of the following is the next step in management?

A. Provide spinal analgesia

**B. Intravenous intrapartum antibiotics

C. Urgent delivery by caesarean section

D. Administer intramuscular dexamethasone

Mitral stenosis Forcep

A 24-year-old multiparous woman is in the second stage of labour. She has a history of asthma and she uses an albuterol inhaler as needed. She has a prior herpes simplex virus infection and reports outbreaks about once per year. As a child, she contracted rheumatic fever and takes prophylactic antibiotics when needed for mitral valve stenosis.

Which significant medical history indicates beneficial use of forceps?

A. Herpes

B. Asthma

**C. Mitral stenosis

D. Prolonged labour

Herpes

A 30-year-old woman presents to the Women's Health Clinic after a spontaneous rupture of membranes occurred at home 1 hour before. Patient medical records indicate a positive history of recurrent vaginal herpes simplex.

Which of the following is the next best step in management?

**A. Pelvic speculum examination

B. Prepare for instrumental delivery

C. Proceed to caesarean section deliver

D. Intravenous acyclovir administration

A gravida 3, para 2 is 16 weeks' pregnant presents to the obstetrics Clinic concerned about outbreak of illness in her child's school and the potential effects on the fetus.

Which of the following vaccines is recommended at this time?

A. Rubella

B. Varicella

C. Smallpox

**D. Influenza

41 week
Cervical ripening
Oxytocin

A 32-year-old multiparous woman is admitted for induction of labour at 41 weeks and 2 days' gestation. She had prior 2 uneventful vaginal deliveries. A pelvic examination shows the cervix is dilated at 2 cm and is 50% effaced with a medium consistency and mid-anterior position. The presenting part is at -2 station.

Which of the following methods would be most appropriate for labour induction?

A. Artificial rupture of membranes

B. Intravenous oxytocin infusion

C. Indwelling catheter insertion

**D. Cervical ripening agent

IUGR

A 30-year-old woman gravida 4, para 3 woman presents to Antenatal Clinic at 32 weeks' gestation with headache and swelling of the feet. At the initial antenatal visit, there was +2 pitting edema of the lower extremities and the face appears swollen. Dipstick of the urine shows proteinuria. The fundal height is 28 cm and fetal heart rate was 140-150 beats per minute with good variability. She reports regular fetal movements.

Blood pressure 150/100 mmHg
Heart rate 90 /min
Respiratory rate 26 /min
Temperature 37.1° C

Which additional clinical finding would be associated with intrauterine growth restriction?

A. Elevated maternal liver enzymes

B. Gestational diabetes

**C. Oligohydramnios

D. Polyhydramnios

Terbutaline

A nulliparous woman is admitted to the hospital at 42 weeks' gestation for induction of labour with cervical prostaglandin gel. On admission, a pelvic examination shows the cervix is closed, thick and posterior facing. A non-stress test shows the fetal heart rate is 130-140 beats per

minute with good variability. There are 3 accelerations and 2 fetal movements during the examination. 1 hour after applying the prostaglandin gel, the fetal heart tones are 80 beats per minute and the contractions last for two minutes.

Which of the following intervention is the most important?

A. Administer oxygen at 10 L/min by facemask

B. Prepare for an urgent caesarean section

**C. Administer subcutaneous terbutaline

D. Assess for cord prolapse

The beta-adrenergic receptor agonist terbutaline also causes myometrial relaxation. It is not used as a tocolytic; however, it can be given to temporarily stop contractions in a laboring patient with a nonreassuring fetal heart tracing. Maternal effects include increase in heart rate leading to palpitations and hypotension.

Patient in labor with 5 cm cervix- after 5 hours still no change, fetal head +1 , ctg is reassuring and shows good uterine contraction. What is the management?
A. Sc terbutaline B. instrumental C. recheck after 2 hrs D. C section

IV ANTIBIOTICS rupture of membranes

A 25-year-old nulliparous woman at 37 weeks' gestation presents to the hospital with regular contractions and spontaneous rupture of membranes. A pelvic examination shows cervical dilation of 6 cm and 90% effacement. Fetal heart rate 130-140 bpm with good variability. Ultrasound examination shows the fetus in a breech position and the patient is admitted for a caesarean section.

When would be the optimal time to administer intravenous antibiotics?

**A. During pre-operative preparation

B. Upon closure of the skin wound

C. After umbilical cord is clamped

D. Postoperative

I/V Abx + STEROIDS (If < 34 weeks) ↑ for fetal lung maturity

Ovarian

A 30-year-old woman presented to the Emergency Department at 03:00 o'clock with right-sided abdominal pain in the lower quadrant. She rates the pain at a level 9 on the 1-10 pain scale. The pain was sudden, associated with nausea and vomiting. A human chorionic gonadotropin urine test was negative. On palpation, there is tenderness and a mass is noted. An ultrasound confirms a mass of 6 cm diameter.

Blood pressure 120/70 mmHg
Heart rate 110 /min
Respiratory rate 20 /min
Temperature 37.0° C oral

Which of the following is the most likely diagnosis?

A. Ectopic pregnancy

**B. Ovarian torsion

C. Ruptured cyst

D. Appendicitis

A 34-year-old woman presented to the hospital 7 days before with right-sided lower abdominal pain. In addition, she had slight bright red vaginal bleeding. A blood serum sample of B-human chorionic gonadotropin was 2900 IU/Liter. She was administered intramuscular methotrexate. A week later, she reported to the hospital with severe right-sided lower abdominal pain. A blood serum sample of B-human chorionic gonadotropin was drawn and shown to be 6,000 IU/Liter.

Which of the following would be most appropriate?

**A. Exploratory laparoscopy

B. Repeat methotrexate

C. Salpingectomy

Corrected

D. Salpingostomy

Ectopic with Bhcg 2500 and one week later 6000 whats next step in management?
A. Medical B. salpingectomy C. salpingotomy ✅ =
removal of a Fallopian tube. This may be done to treat an ectopic pregnancy or cance
Ruptured

ectopic pregnancy BHCG 3000 , medically treated. on follow up BHCG is rising ,next step? (nothing about the stability of the pt)
A. medical treatment B. salpingostomy ✅✅ C. salpingectomy

A 34-year-old multiparous woman presents at 37 weeks' twins gestation with regular contractions.

Which of the following fetal presentations is favourable for vaginal delivery?

A. Transverse-cephalic

**B. Cephalic-cephalic

C. Breech-breech

D. Breech-cephalic

A 26-year-old primigravida woman presented to the clinic at 37 weeks' gestation for a routine antenatal care. She reports feeling ill and has a frontal headache. A urine dipstick analysis is performed and shows proteinuria 2+. She is admitted to the hospital High Risk Unit and started on an intravenous infusion of magnesium sulfate.

Blood pressure 152/102 mmHg
Heart rate 72 /min
Respiratory rate 16 /min
Temperature 37.2° C oral

Which of the following is the primary reason for administering the intravenous medication?

A. Prevent pulmonary congestion

B. Control vascular vasospasms

6th June Exam DHA

C. Reduce blood pressure

**D. Prevent seizures

Chicken pox

A 28-year-old primigravida 8 weeks gestation woman attended her first antenatal appointment. During the history assessment, she reports that she never had chickenpox. A serum blood titer is drawn and is negative for antibodies.

Which of the following is the next best step in management?

**A. Avoid exposure

B. Varicella vaccination

C. Prophylactic acyclovir

D. Zoster immunoglobulin

IUGR
HTN

A 34-year-old gravida 2 para 1 woman 10 weeks gestation known to have a hypertension taking labetalol 100 milligrams twice per day. In her first pregnancy had no complications and resulted in a healthy infant.

During this pregnancy which of the following risks is increased?

**A. Intrauterine growth restriction

B. Abnormal fetal presentation

C. Adherent placenta

D. Uterine rupture

Cesarean

A multiparous woman presents to the Maternal Health Clinic at 37 weeks' gestation with regular contractions occurring every 2 minutes lasting for 45-60 seconds with moderate intensity. Last pregnancy ended up with low transverse incision caesarean section. She is now pregnant with twins. Twin A is breech and twin B is cephalic. There has been small amount of clear fluid leaking from the vagina for the past hour. A nitrazine paper test turns blue-green in color. Pelvic examination shows a cervical dilation of 4 cm and 80% effacement. The obstetrician informs her that a caesarean section is necessary.

Which of the following is the most likely reason for a caesarean section?

A. Ruptured membranes

**B. Previous caesarean

C. Fetal presentation

D. Fetal age

Chronic HTN
Pre eclampsia

A 35-year-old nulliparous woman presents to the Maternal Health Clinic at 24 weeks' gestation. The significant medical history includes insulin-dependent diabetes class F with nephritis. Additionally, she has chronic hypertension which is controlled with medication. The pregnancy has been uncomplicated so far. The uterine fundus measured 25 cm above the symphysis and fetal heart tones show a baseline of 160 beats per minute.

Which of the following complications is most likely to occur?

A. Stillbirth

**B. Pre-eclampsia

C. Shoulder dystocia

D. Large for gestational age infant

Epithelial

A 30-year-old para 1 woman presents to the Maternal Health Clinic at 20 days postpartum. She has delivered a full-term girl vaginally by forceps-assisted delivery. The weight at birth is 3.54 kg. She presents with a yellow-white colored vaginal discharge. The discharge is odorless and there is no itching or discomfort. An examination shows a pink cervix and absence of uterine tenderness. A microscopic analysis of the vaginal fluid is positive for leukocytes and epithelial cells.

Which of the following is the most appropriate management?

A. Dipstick urinalysis

B. Culture discharge

C. Metronidazole

**D. Reassurance

Depo provera

A 22-year-old woman attends the Women's Health Clinic for a postnatal examination. She delivered a full-term baby boy 6 weeks earlier and the infant is exclusively breastfeeding and shows a good latch and weight gain. She would like to have more children, but not within the next 2 years. She does not smoke cigarettes and not at risk for heart disease. She inquired about birth control methods.

Which of the following methods is most appropriate?

**A. Depo-provera injection

B. Transdermal patch

C. Combined oral pill

D. Vaginal ring

Adnexa
Tubal ligation

A 40-year-old woman underwent a laparoscopic tubal ligation during the postpartum period following the delivery of her 4th child 4 years ago. She presents to the Maternal Health Clinic complaining of bright red vaginal spotting. Patient last menstrual cycle was 6 weeks ago. A pelvic examination shows fullness over the right adnexa. There is no pain or tenderness. Her last pregnancy resulted in an emergency caesarean section with a mid-line incision.

Which of the following is the best next step in management?

A. Laparoscopy

**B. Pregnancy test

C. Pelvic ultrasound

D. Endometrial biopsy

Non stress test

A 24-year-old nulliparous woman presents to the Maternal Health Clinic in the evening at 34 weeks' gestation and complaining of decreased fetal movement. She says she had been at work all day and then came directly to the hospital when she noticed that the baby has not been moving as much as usual. There has been no leaking of amniotic fluid. There are no uterine contractions and also no vaginal bleeding.

Which of the following is the most appropriate next step in management?

**A. Non-stress test

B. Biophysical profile

C. Pelvic examination

D. Vibro-acoustic stimulation

A gravida 2 para 0 woman presents to the Maternal Health Clinic reporting that she has not menstruated for the past 2 months. The previous pregnancy had resulted in a stillbirth at 34 weeks' gestation. A human chorionic gonadotropin test is now positive. She has been trying to conceive for the past 6 months. She is afraid of having another stillbirth and asks to be vaccinated against everything.

Which of the following vaccines is most appropriate to administer?

A. Rubella

B. Measles

**C. Influenza

D. Varicella

PCOS
FSH LH

A 30-year-old woman presents to the Maternal Health Clinic with the inability to conceive despite trying for the past 18 months. Patient menstrual cycles were regular until 2 years ago, and since then she has had irregular vaginal bleeding. there is hair covering the upper lip and chin. A pelvic examination confirms bilaterally enlarged ovaries. DHEA and 17-OH progesterone values are normal.

Body mass index 30 kg/m2

Which of the following laboratory values is most likely finding?

A. Normal testosterone levels

B. Decreased free androgen index

C. Increased thyroid hormones

**D. A Follicle Stimulating Hormone to Leutenizing Hormone ratio of 1:3

PCOS

A 20-year-old woman presented to the Maternal Health Clinic with severe facial acne and irregular menstrual bleeding. Examination shows fine hair growth on the chin, upper back, breasts and lower abdomen. A pregnancy test is returned negative. She returns to the clinic on the 5th day of her menstrual cycle and has a serum sample drawn for analysis (see lab results).

Test Result Normal Values
Follicle-stimulating hormone 10 5-20 IU/L
Luteinizing hormone 28 5-22 U/L
Prolactin 890 < 870 pmol/L
Testosterone 3.2 0.7-2.8 nmol/L

PCOS is a "prediabetic" state—some of the same mechanisms that cause insulin resistance also interfere with aromatization of testosterone to estrogen, leading to higher androgen levels in these patients.
LH/FSH alterations occur later

Which additional laboratory values should be obtained?

A. Thyroid stimulating hormone and free T3 and T4

B. Progesterone and thyroid stimulating hormone

C. Dehydroepiandrosterone and androstenolone

**D. Glucose tolerance and lipid profile

APGAR

A paediatrician is called to attend a caesarean section delivery of 38 week's gestation baby. On delivery, the neonate does not cry immediately, appears cyanotic and floppy. After drying, suctioning and stimulating the baby under the radiant warmer, the following evidence is recorded at 5 minutes (see table).

2 Heart rate 120 beats per minute
1 Breathing Irregular, gasping
2 Reflex irritability Coughs, and cries with stimulation
1 Activity Arms and legs flexed, little movement
1 Appearance Rosy with blue extremities

Acronym	Criterion	0 points	1 point	2 points
Appearance	Skin color/complexion	Blue all over	Normal except extremities	Normal all over
Pulse	Pulse rate	<60 bpm or asystole	>60 bpm but <100 bpm	>100 bpm
Grimace	Reflex irritability	No response	Grimace/feeble cry	Sneeze/cough
Activity	Muscle tone	None	Some flexion	Active movement
Respiration	Breathing	Absent	Weak or irregular	Strong

APGAR SCORING

A rapid scoring system that helps evaluate the need for neonatal resuscitation (Table 2.12-8). Each of five parameters is assigned a score of 0 to 2 at 1 and 5 minutes after birth.

- **Scores of 8 to 10:** Typically reflect good cardiopulmonary adaptation
- **Scores of 4 to 7:** Indicate possible need for resuscitation; infants should be observed, stimulated, and possibly given ventilatory support
- **Scores of 0 to 3:** Indicate the need for immediate resuscitation

What is the most accurate Apgar score?

A. 6

B. 7

**C. 8

D. 9

A 31-year-old woman P2 presented to the Women's Health Clinic for a routine physical examination. She has presented to routine health examinations annually for the last 5 years. Records indicate that in the previous year, she has negative tests for both the human papilloma virus and the papanicolaou cervical smear. This year both tests are with no abnormal findings.

When should the tests be repeated?

A. 6 months

B. 1 year

C. 2 years

**D. 3 years

A patient is seen at 8 weeks' gestation in an Antenatal Clinic with a diagnosis of cervical incompetence.

Which of the following is the most appropriate management?

A. Insertion cervical suture the same week

B. Confirm the diagnosis by Hegar dilator

**C. Insert cervical suture at 14 -16 weeks

D. Begin beta mimetic drugs

A 15-year-old unmarried girl presents with history of pain during menstruation. Her menarche was at age of 13 and menses are regular. Physical and pelvic examinations are normal for her age.

Which of the following is the most appropriate management?

**A. Non-steroidal anti-inflammatory medication

B. Estrogen-progestin oral contraceptive

C. Cervical dilatation

D. Danazol

A 23-year-old nulligravida patient complains of inability to become pregnant after 3 months of trying. Patient periods are regular and normal. She had no prior reproductive problems. She currently is not on any contraception. Examination is normal. Her husband is 25-year-old healthy and has one autistic cousin and one with trisomy 21.

Which of the following is the best action?

A. Sperm count

6th June Exam DHA

**B. Continue trying

C. Genetic testing

D. Tubal patency test

A 24-year-old married woman presented to the clinic with severe abdominal pain followed by vaginal bleeding, for the last 6 hours. Patient's LMP was 8 weeks ago. On examination; she is drowsy and has a tense abdomen.

Blood pressure 90/60 mmHg
Heart rate 120 /min
Respiratory rate 20 /min
Temperature 36.8 ° C

Which of the following is the most likely diagnosis?

A. Threatened abortion

**B. Ectopic pregnancy

C. Complete abortion

D. Anovulatory cycle

A 24-year-old woman presents to the clinic with complaining of failure to conceive for more than 2 years of regular trials. Patient has history of irregular periods occurring once every 6 to 7 weeks and is usually scanty (see report).

Body mass index 35 kg/m2

Transvaginal ultrasound:
Revealed the presence of multiple small cysts; each is 3-5mm, lining the ovarian periphery, representing pearl necklace appearance.

Which of the following is the most likely factor contributing to her infertility?

A. Tubal factor

B. Cervical factor

**C. Ovulatory factor

D. Endometrial factor

RhoGAM

A 17-year-old woman comes at 39 weeks' gestation to the Emergency Department with no previous antenatal care. She delivered a healthy baby boy normally with no complications reported. Then she was given an injection of RhoGAM.

What is the indication of RhoGAM?

**A. Mother is Rh- and the baby is Rh+

B. Father is RH+ and the baby is Rh-

C. Mother is Rh+ and the baby is Rh-

D. Father is Rh- and the baby is Rh+

Hydatidiform mole

A 37-year-old primigravida presented to the clinic with amenorrhea for 12 weeks, hyperemesis gravidarum, and raised human chorionic gonadotropin levels. Uterus size is equivalent to 16 weeks' gestation (see report).

Ultrasound:
Fetus is small for dates.

Which of the following is the most likely diagnosis?

A. Choriocarcinoma

**B. Hydatidiform mole

C. Toxemia of pregnancy

D. Placental site trophoblastic tumor

Pudendal nerve block

A 26-year-old multiparous woman in labor is requesting pain relief. While in the lithotomy position, the obstetrician performs a pudendal nerve block, and injects a local anesthetic into the sacrotuberous ligament close to the ischial spine.

Which of the following structures will remain fully sensitive despite this pudendal nerve block?

A. Urogenital diaphragm

B. Perineal body

**C. Rectum

D. Vulva

A 45-year-old woman presents to the Gynaecological Clinic with history of genital warts that were treated by electrocautery 2 years back. The woman complained of recurrent occurrence of scanty fresh bleeding after intercourse.

Which of the following is the likely source of her bleeding?

**A. Uterine cervix

B. Uterine body

C. Vagina

D. Vulva

Clear colored
Phlegm
Allergic to dust
Asthma
Spirometry

A 34-year-old multiparous woman presents to the Maternal Health Clinic at 28 weeks' gestation with coughing and difficulty in breathing. She appeared restless and uncomfortable. Auscultation of the lung fields shows bilateral rhonchi. The nail beds and oral mucous membranes appear pale. She is allergic to dust, pollen, mold and animal hair. There is no history of smoking. She reports that the symptoms began 2 days prior and had started with coughing up clear-colored phlegm.

Blood pressure 124/72 mmHg
Heart rate 120 /min
Respiratory rate 24 /min
Temperature 37.5° C oral

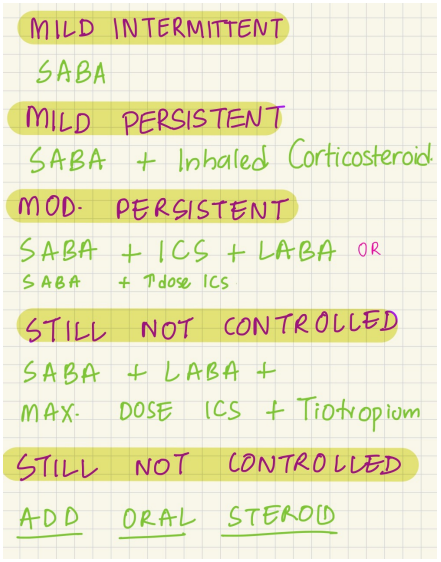

Which of the following tests is initially most appropriate?

**A. Spirometry

B. Chest X-ray

C. Arterial blood gas levels

D. Hemoglobin estimation

Asthma

A 28-year-old woman with mild intermittent asthma presents to the Health Clinic at 24 weeks' gestation and says that her symptoms have worsened as the pregnancy progresses. Prior to the pregnancy, she had an occasional exacerbation of asthma and used only an albuterol inhaler for treatment as needed. However, she now complains of daily symptoms and once per week symptoms at night time. A forced expiratory volume in 1 second test shows 70% of normal.

Which of the following medication regimen is now most appropriate?

A. Short-acting bronchodilators and oral glucocorticoids

B. Inhaled glucocorticoids and short-acting bronchodilators

**C. Inhaled glucocorticoids and long-acting bronchodilators

D. Long acting beta2 agonist and inhaled glucocorticoids

Cough productive
Chills
Immigrant
Crepitations
TB

A 28-year-old woman G 4 P2012 immigrant presented to the Maternal Health Clinic at 20 weeks' gestation with a cough and night chills for the past month. The cough is productive and produces thick sputum. She had been prescribed treatment by a general practitioner for the cough and it had not responded to treatment. Patient nail beds and conjunctiva appeared pale and the cervical lymph nodes are palpable. Auscultation of the chest shows crepitation over the upper left lobe. She had received a BCG vaccine as a child. A blood test is positive for interferon-gamma release assays.

Blood pressure 110/70 mmHg
Heart rate 84 /min
Respiratory rate 18 /min
Temperature 37.5° C oral

Which of the following is the next best step in obtaining a definitive diagnosis?

A. Chest X-ray

**B. Sputum culture

C. Tuberculin skin test

D. Sputum smear cytology

Episiotomy

A 23-year-old primigravida presented in labour. The mid wife advised mediolateral episiotomy during the 2nd stage of labour.

What is the advantage of a mediolateral episiotomy?

A. Easy repair

B. Less infection

C. Tighter introitus

**D. Less anal extension

A 23-year-old G2 P1001 at 22 weeks' gestation presented with a complaint of her abdomen is larger than her previous pregnancy (see report).

Ultrasound:
Showed dizygotic twin pregnancy.

Which of the following best described membranes and placenta of dizygotic twins?

A. Monochorionic and monoamniotic for conjoined twins

B. Monochorionic and diamniotic for the foetuses of same sex

C. Dichorionic and monoamniotic for the foetuses of same sex

**D. Dichorionic and diamniotic regardless of the sex of the foetuses

Umbilical cord
DM
Maternal DM

A 25-year-old woman has delivered a boy. On inspection of the umbilical cord, a single artery was noticed.

Which of the following is associated with the above finding?

A. African race

**B. Maternal diabetes

C. Low foetal mortality

D. Major foetal malformation in 80%

A 33-year-old pregnant woman G4 P2012 at 38 weeks' gestation presented with a complaint of dizziness, light-headedness and fainting sensation especially in bed for 2 weeks duration (see lab results).

Blood pressure 110/70 mmHg
Heart rate 100 /min
Respiratory rate 24 /min
Temperature 36.6° C

Test Result Normal Values
Hb 95 120-160 g/L
WBC 9 4.5-10.5 x 109/L
Platelet count 200 150-400 x 109/L

Which of the following is the best management?

A. Blood transfusion

B. Refer to a neurologist

**C. Avoid sleep on the back

D. ECG and echocardiography

Ectopic

A 28-year-old woman is diagnosed with an ectopic pregnancy.

Which of the following is the most likely predisposing factor?

6th June Exam DHA

A. Induction of ovulation

B. Previous tubal pregnancy

**C. Pelvic inflammatory disease

D. Use of an intrauterine contraceptive device

- PID (MC RF)
- IUD
- IVF
- previous Ectopic (strongest RF)

Acute appendicitis
Torsion.

A 21-year-old woman G2 P1001 presents to the Emergency Room with a severe lower abdominal pain for 1 day. Pain is dull and intermittent that last for 10-15 minutes and associated with nausea and vomiting. Examination confirms tenderness and guarding in the lower abdomen, it is more on right side and slight fullness in the right iliac fossa (see report).

Blood pressure 90/60 mmHg
Heart rate 110 /min
Respiratory rate 13 /min
Temperature 37.6° C

Pregnancy Test:
Negative.

Which of the following is the most likely diagnosis?

A. Acute cystitis

**B. Ovarian torsion

C. Acute appendicitis

D. Ectopic pregnancy

A 35-year-old pregnant woman at 34 weeks of gestation presented with labour pains. On physical examination, the cervix was 4 cm dilated. Cardiotocography was performed (see image).

Blood pressure 135/88 mmHg
Heart rate 89 /min
Respiratory rate 18 /min
Temperature 37.4° C

Which of the following is the most likely diagnosis?

A. Placenta previa

B. Head compression

C. Umbilical cord compression

**D. Uteroplacental insufficiency

Abortion
Chromosomal abnormality

A 28-year-old woman G3 P0020 at 5 weeks' gestation presents with vaginal bleeding associated with some blood clots that has started 3 hours ago. She had been diagnosed with cervical incompetence in her 2 prior second-trimester abortions. A history of dilatation and curettage in her last abortion declared. On examination; the cervical os is open and no on-going bleeding.

Which of the following is the most likely cause of her current diagnosis of vaginal bleeding?

A. Luteal phase defect

B. Asherman's syndrome

C. Cervical incompetence

**D. Chromosomal abnormality

HEMATOLOGY

A 59-year-old woman comes to the clinic with headache, dyspnea on exertion and occasional palpitations (see lab results).

Test Result Normal Values
Hb 95 130-170 g/L (Male)
120-160 g/L (Female)
MCV 68 80-95 fl
Platelets count 530 150-400 x 109/L
Total iron binding capacity 30 11.6-31.3 µmol/L (Male)
9-30.4 µmol/L (Female)
Ferritin 3 20-300 µg/L (Male)
20-120 µg/L (Female)

Which of the following is the most likely diagnosis?

A. B12 deficiency

B. Folate deficiency

**C. Iron deficiency anemia

D. Anemia of chronic disease

Iron deficiency anemia
Endoscopy

A 59-year-old woman comes to the clinic with headache, dyspnea on exertion and occasional palpitations (see lab reults).

Test Result Normal Values
Hb 95 130-170 g/L (Male)
120-160 g/L (Female)
MCV 68 80-95 fl
Platelets count 530 150-400 x 109/L
Total iron binding capacity 28 11.6-31.3 µmol/L (Male)
9-30.4 µmol/L (Female)
Ferritin 3 20-300 µg/L (Male)
20-120 µg/L (Female)

Apart from starting iron supplement, which of the following is the most appropriate next step in management?

A. Urea breath test

B. Stool occult blood

C. CT-scan abdomen and pelvis

**D. Endoscopy and colonoscopy

A 46-year-old man comes to the clinic with dyspnea on exertion and palpitations. On examination, he has patches of vitiligo (see lab results).

Test Result Normal Values
Hb 89 130-170 g/L (Male)
120-160 g/L (Female)
MCV 103 80-95 fl
Platelets count 128 150-400 x 109/L
Ferritin 105 20-300 µg/L (Male)
20-120 µg/L (Female)
Vitamin B12 (Men) 122 160-900 ng/L
Folic Acid (Men) 8 <4 µg/L

Which of the following is the most appropriate test to be ordered next?

A. Gastroscopy and antral biopsy

**B. Intrinsic factor antibodies

C. Anti-gliadin antibodies

D. Colonoscopy

A 59-year-old man has unsteady gait. On examination, he has decreased proprioception in the lower limbs with positive planter reflexes (positive Babinski) and absent ankle and knee's reflexes. He has anemia. Peripheral smear done (see image).

Which of the following is the most likely diagnosis?

A. Alcoholism

B. Iron deficiency

**C. B12 deficiency

D. Hypothyroidism

A 65-year-old-woman has decreased concentration (see lab results).

Macrocytic
MMA
Homocysteine

Test Result Normal Values
Hb 89 130-170 g/L (Male)
120-160 g/L (Female)
MCV 106 80-95 fl
Platelets count 129 150-400 x 109/L
Vitamin B12 (Women) 0.46 0.12-0.66 nmol/L
Folic Acid (Women) 0.03 <0.1 µmol/L

Vit B12	Folate
↑ homocystine	↑ homocystine
↑ MMA	–

Which of the following would be found on further testing?

A. High methyl malonic acid and normal homocysteine

B. High methyl malonic acid and high homocysteine

**C. Normal methyl malonic acid and high homocysteine

D. Low methyl malonic acid and low homocysteine

A 46-year-old man has dyspnea on exertion and palpitations. On examination, he has patches of vitiligo and has absent reflexes with positive Babinski in the lower limbs (see lab results).

Test Result Normal Values
Hb 91 130-170 g/L (Male)
120-160 g/L (Female)
MCV 103 80-95 fl
Platelets count 129 150-400 x 109/L
Ferritin 120 20-300 µg/L (Male)
20-120 µg/L (Female)
Vitamin B12 (Men) 124 160-900 ng/L
Folic Acid (Men) 6 <4 µg/L

Which of the following is the most appropriate management?

A. Oral iron supplement

B. Oral b12 supplement

C. Folate supplement

**D. Parenteral b12 supplement

TTP

A 35-year-old woman has fever and headache for 2 days. On examination, she has a scattered petichiae over her body. Her platelets are 32. Peripheral smear done (see image and lab results).

Temperature 38.6 °C

Test Result Normal Values
Platelets count 32 150-400 x 109/L
Hb 11.2 130-170 g/L (Male)
120-160 g/L (Female)
MCV 102 80-95 fl
Reticulocyte 4.9 0.2-1.2 %
Lactate dehydrogenase 690 60-160 IU/L
Indirect bilirubin 43 3.2-12.1 µmol/L
Total bilirubin 65 3.5-16.5 µmol/L
Creatinine 66 44-115 µmol/L
APTT 36 30-40 sec
INR 1.1 0.8-1.2
Prothrombin time 11 10-13 sec

History/PE

TTP: Associated with SLE, malignancy, pregnancy, cyclosporine, quinidine, clopidogrel, ticlopidine, and AIDS. TTP can also be hereditary. Classic description involves a pentad of features. The physician should suspect TTP if three of five of the following symptoms are present **(LMNOP):**

1. Low platelet count (thrombocytopenia)
2. Microangiopathic hemolytic anemia with schistocytes (severe, often with jaundice)
3. Neurologic changes (delirium, seizure, stroke, ↓ consciousness, ↓ vision)
4. "Obsolete" (impaired) renal function (acute kidney injury [AKI])
5. Pyrexia (fever)

↓ platelets ↑ BT
(N) PT, APTT
↑ LDH, ↑ bilirubin (due to Hemolysis)
↓ haptoglobin ↑ Cr. ~more typical of HUS

Low ADAMTS 13 level

Which of the following is the most likely diagnosis?

A. Immune thrombocytopenia (ITP)

B. Hemolytic uremic syndrome (HUS) — Children, without CNS symptoms, *E. COLI O157:H7

**C. Thrombotic thrombocytopenic purpura (TTP) — Adults

D. Disseminated intravascular coagulopathy (DIC)

TTP TREATMENT

A 38-year-old woman has fever and headache for 2 days. On examination, she has a scattered petichiae over her body. Peripheral smear done (see image and lab results).

Temperature 38.6 °C

Test Result Normal Values
Hb 112 130-170 g/L (Male)
120-160 g/L (Female)
Reticulocyte 5.6 0.2-1.2 %
Platelets count 32 150-400 x 109/L
Indirect bilirubin 48 3.2-12.1 µmol/L
Total bilirubin 76 3.5-16.5 µmol/L
Lactate dehydrogenase 690 60-160 IU/L
APTT 33 30-40 sec
INR 1.0 0.8-1.2
Prothrombin time 10 10-13 sec

Rx: Plasmapheresis
(or FFP transfusion if Plasmap. not in option)

Which of the following is the most appropriate treatment?

A. Intravenous immunoglobulin and prednisone

B. Transfuse platelets (CONTRA-INDICATED)

**C. Plasma exchange

D. Argatroban

A 48-year-old man develops right popliteal vein thrombosis post-sleeve surgery. He is started on enoxaparin and warfarin.

What is the target therapeutic international normalization ratio range for this patient?

A. 1-1.9

**B. 2-3

C. 3.1-4

D. No need for monitoring

LMWH
Unfractionated
Clearance

A 53-year-old woman admitted to the hospital with pneumonia. She has diabetes, hypertension and is on hemodialysis for end-stage renal disease (see lab results).

Test Result Normal Values
Hb 98 130-170 g/L (Male)
120-160 g/L (Female)
Platelets count 151 150-400 x 109/L
APTT 33 30-40 sec
INR 0.9 0.8-1.2
Prothrombin time 9.8 10-13 sec
Creatinine 460 44-115 µmol/L

LMWH → clearance through KIDNEY only

Unfract-Heparin → Hepatic & Renal clearance

Which of the following is the most appropriate venous thromboembolism prophylaxis for this patient?

A. Graded compression stockings

**B. Unfractionated heparin

C. Fondaparinux

D. Enoxaparin

Saddle embolus

A 38-year-old woman admitted with pyelonephritis. 2 days after admission, she develops sudden severe shortness of breath (see report).

Blood pressure 84/50 mmHg
Heart rate 124 /min
Oxygen saturation 84 %

CT-pulmonary angiogram:
A saddle embolus at the bifurcation of the pulmonary artery and multiple segmental pulmonary emboli bilaterally.

Which of the following is the most appropriate treatment?

A. Unfractionated heparin and warfarin

B. Enoxaparin

**C. Alteplase

D. Apixaban

HIT

A 59-year-old man has diabetes, hypertension, dyslipidemia and chronic renal impairment. He was admitted 5 days ago to the Coronary Care Unit for a non-ST-elevation myocardial infarction (NSTEMI). He is receiving unfractionated heparin. His labs upon admission were normal. Day 5 of his admission, labs as shown (see lab results).

Test Result Normal Values
Hb 13.1 130-170 g/L (Male)
120-160 g/L (Female)
Platelets count 65 150-400 x 109/L
WBC 10.3 4.5-10.5 x 109/L
Creatinine 88 44-115 µmol/L
APTT 36 30-40 sec
INR 1.1 0.8-1.2
Prothrombin time 11 10-13 sec

- Give fondaparinux or direct thrombin inhibitors (argatroban, bivalirudin); fondaparinux is easiest to use.
- Add warfarin only after a direct thrombin inhibitor has been started.

Which of the following is the most likely cause of his thrombocytopenia?

A. Immune thrombocytopenia (ITP)

**B. Heparin induced thrombocytopenia (HIT)

C. Thrombotic thrombocytopenic purpura (TTP)

D. Disseminated intravascular coagulopathy (DIC)

DIC

A 38-year-old woman has fever and headache for 2 days. Peripheral smear done (see image and lab results).

Heart rate 110 /min
Temperature 38.9 °C

Test Result Normal Values
Hb 112 130-170 g/L (Male)
120-160 g/L (Female)
Reticulocyte 3.2 0.2-1.2 %
Platelets count 123 150-400 x 109/L
Fibrinogen 1.1 2-4 g/L
APTT 68 30-40 sec
INR 1.8 0.8-1.2
Prothrombin time 24 10-13 sec
Direct bilirubin 24.5 1.5-6.5 µmol/L
Total bilirubin 48.3 3.5-16.5 µmol/L
Lactate dehydrogenase 390 60-160 IU/L

Which of the following is the most likely diagnosis?

A. Immune thrombocytopenia (ITP)

B. Heparin induced thrombocytopenia (HIT)

C. Thrombotic thrombocytopenic purpura (TTP)

**D. Disseminated intravascular coagulopathy (DIC)

A 62-year-old woman has atrial fibrillation for which she has started on warfarin. Few weeks after, she fell down and developed a subdural hematoma that requires evacuation (see lab result).

Test Result Normal Values
INR 3.9 0.8-1.2

Which of the following is the most appropriate management?

A. Vitamin K

B. Fresh frozen plasma

C. Activated factor VII (fviia)

**D. Fresh frozen plasma and vitamin K

ALL
Chemotherapy

An 18-year-old-boy is receiving chemotherapy for acute lymphoblastic leukemia. On day 17 of chemotherapy, he has fever. He has no focus of infection (see lab results).

Heart rate 110 /min
Temperature 38.9 °C

Test Result Normal Values
Platelets count 25 150-400 x 109/L
WBC 0.6 4.5-10.5 x 109/L
Neutrophils 60 40-60%
Lymphocytes 20 20-40 %

Which of the following is the most appropriate management?

A. Send blood, urine, sputum cultures

B. Send blood, urine, sputum cultures and start paracetamol

C. Send blood, urine, sputum cultures and start oral broad spectrum antibiotics

**D. Send blood, urine, sputum cultures and start intravenous broad spectrum antibiotics

Lymph node
Excision biopsy

A 43-year-old-woman has fever, night sweats and weight loss. She has lost 12 Kg in the last 3 month (unintentional). She had no contact with a tuberculosis patient. On examination, she has bilateral cervical lymph nodes, largest 3 cm X 2 cm. There is also inguinal lymphadenopathy and the spleen is palpable 3 fingers below the costal margin.

Which of the following is the most appropriate next step in management?

A. Fine needle aspiration of the lymph node

**B. Excisional biopsy of the lymph node

C. Bone marrow biopsy

D. Splenectomy

6th June Exam DHA

Tumor lysis syndrome

A 63-year-old man has chronic lymphocytic leukemia started on chemotherapy. His initial lynmphocyte count was 73,000. 2 days after chemotherapy, he presents with fatigue and dry mouth (see lab results).

Test Result Normal Values
WBC 5.7 4.5-10.5 x 109/L
Lymphocytes 60 20-40 %
Potassium 5.5 3.5-5.1 mmol/L
Phosphate, inorganic 1.48 0.82-1.51 mmol/L
Creatinine 139 44-115 µmol/L
Uric acid 620 200-410 µmol/L (Male)
140-360 µmol/L (Female)

KEY FACT

Watch for tumor lysis syndrome at the onset of any chemotherapy regimen.

Which of the following electrolyte abnormality is associated with the above condition?

TUMOR LYSIS SYNDROME
↑ PO_4^-, Uric Acid, K^+ (PUK)
↓ Ca^+

**A. Hypocalcimia

B. Hypercalcimia

C. Hyponatremia

D. Hypernatremia

NEUROLOGY

Lewy Bodies

A 65-year-old man presented with 6-month symptoms of Parkinsonism, early dementia, fluctuations in cognition and visual hallucinations.

Which of the following is the most likely diagnosis?

A. Parkinson disease

B. Alzheimer disease

C. Corticobasal syndrome

**D. Dementia with Lewy bodies

TYPE	TIME COURSE, KEY EARLY PRESENTATION	PATHOLOGIC FINDINGS	IMAGING/STUDIES
Dementia with Lewy bodies	Gradual, more rapid than Alzheimer disease; hallucinations, daily fluctuations in cognition; parkinsonism; REM sleep behavior disorder	Round, eosinophilic inclusions of α-synuclein in cerebral cortex (Image C) (dementia with Lewy bodies [DLB]) or subcortical (basal ganglia)/midbrain regions (Parkinson disease dementia)	MRI → cortical atrophy with limited hippocampal atrophy (vs Alzheimer disease)

Gradual Early Memory impairment
diffuse cortical atrophy (temporal, parietal, hippocampal) + ventriculomegaly on MRI / CT

An 81-year-old man with memory loss and difficulty recognizing his grandsons. He has no cardiovascular risk factors.

Which of the following is the most common cause of his cognitive impairment?

A. Alcohol-induced encephalopathy

B. Parkinson's associated dementia

C. Multi-infarct dementia

**D. Alzheimer's disease

A 65-year-old man who is asymptomatic and has no known allergies is seen for a general examination.

What is the best approach for pneumococcus immunization?

A. PPSV23

**B. PCV13 followed by PPSV23

C. PPSV23 followed by PCV13

D. No evidence supports vaccinating this patient

A 64-year-old man presents to the clinic after having first episode of right knee pain for 2 weeks duration. He asks for a medicine to relieve his pain. He does not have any other symptoms apart from epigastric burning. He has no history of injury to the knee. Examination of knee is normal.

Which is the most appropriate analgesic for this patient at this stage?

A. Aspirin

B. Codeine

C. Ibuprofen

**D. Paracetamol

Prebycusis
Rinne positive

An 82-year-old woman at long term nursing facility who wears hearing aids and is found to have bilateral cerumen impaction, a Weber test that lateralizes to the right, and a bilaterally positive Rinne test.

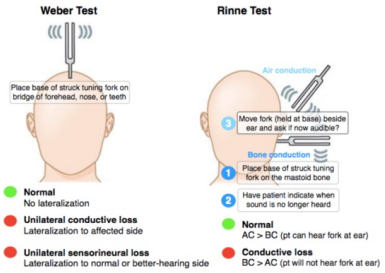
Weber Test
Rinne Test
Place base of struck tuning fork on bridge of forehead, nose, or teeth
Air conduction
Move fork (held at base) beside ear and ask if now audible?
Bone conduction
Place base of struck tuning fork on the mastoid bone
Have patient indicate when sound is no longer heard
Normal
No lateralization
Unilateral conductive loss
Lateralization to affected side
Unilateral sensorineural loss
Lateralization to normal or better-hearing side
Normal
AC > BC (pt can hear fork at ear)
Conductive loss
BC > AC (pt will not hear fork at ear)
Sensorineural
Involving the inner ear, cochlea, or the auditory nerve
Conductive
Involving any cause that limits the amount of external sound from gaining access to the inner ear (e.g., cerumen impaction)
Mixed
A combination of conductive and sensorineural hearing loss

Which of the following is the most likely explanation?

A. Right-sided acoustic neuroma

**B. Prebycusis that is greater on the right

C. Conductive hearing loss that is greater on the right

D. Chronic serous otitis media that is greater on the left

A 91-year-old man with poor performance status, dementia, and multiple medical problems who has been diagnosed with an adenocarcinoma of an unknown primary site and has upper abdominal lymphadenopathy, liver lesions, and pulmonary nodules.

Which of the following is the most appropriate management?

A. Exploratory laparotomy with biliary bypass procedure

B. Excisional biopsy to identify the primary site

C. Palliative systematic chemotherapy

**D. Comfort care

Alzheimer

A 79-year-old man comes to the clinic for a follow-up. He has a 1-year history of progressive memory impairment and clinical evidence of early Alzheimer dementia.

Which of the following is the most appropriate initial diagnostic tests?

**A. Brain imaging

B. Lumbar puncture

C. Carotid ultrasound

D. Electroencephalogram

Low back pain
Compression fracture
Acitaminophen

An 81-year-old woman reports low back pain that began after a forceful coughing episode. Lumbar radiographs reveal features of a lumbar compression fracture.

Which of the following is the most appropriate initial step in her care?

A. Prescribe nasal calcitonin

**B. Prescribe acetaminophen

C. Admit for vertebroplasty

D. Infuse zoledronate

Osteoarthritis

A 77-year-old woman with stage 3 chronic kidney disease and pain from osteoarthritis of the first carpometacarpal joint.

Which of the following is the best initial treatment for her pain?

A. Tendon-release surgery

**B. Splinting and occupational therapy

C. Ibuprofen 800mg 3 times daily with food

D. Glucocorticoid injection into the first carpometacarpal joint

Future Fall
Get up

Which of the following physical maneuvers is most likely to assist the risk of future falls for a healthy 68-year-old man?

A. Test for nystagmus

**B. Get-up-and-go test

C. Test for pulsus paradoxus

D. Lumbar spine flexibility test

COPD
Exacerbations
Tiotropium

A 76-year-old man with chronic obstructive pulmonary disease (COPD) comes to the clinic for a follow-up. He is currently taking salmeterol, using albuterol rescue inhaler 2 to 3 times per day for the past 3 months. He has been hospitalized for COPD exacerbations twice in the past 6 months.

Which of the following medications should be added to the maintenance regimen?

A. Montelukast

B. Prednisone

**C. Tiotropium

D. Formoterol

- Asthma not controlled with albuterol → inhaled steroid
- COPD not controlled with albuterol → anticholinergic (e.g., tiotropium) → inhaled steroid

A 78-year-old man was admitted to hospital with lethargy and back pain. He had a history of type 2 diabetes mellitus and rheumatoid arthritis (see lab results).

Test Result Normal Values
Calcium 2.72 2.15-2.62 mmol/L
Creatinine 196 44-115 µmol/L
Urinary protein: creatinine ratio 154 mg/mmol (<30)

Which of the following is most likely diagnosis?

A. Primary hyperparathyroidism

B. Membranous nephropathy

**C. Diabetic nephropathy

D. Primary amyloidosis

A 75-year-old man with difficulty walking and left-sided leg weaknesses due to osteoarthritis of the hip.

In which hand should a cane be used by this patient?

A. Left hand

**B. Right hand

C. Either hand

D. Both hands simultaneously

NSAIDS
Pseudoephdrine
Potassium

A 71-year-old man is referred to the Outpatient Clinic for advice on his antihypertensive treatment. He has a history of stroke and longstanding uncontrolled hypertension. 6 blood pressure recordings at home and at his surgery within the past 2 weeks were 188-216/103-112 mmHg. His therapy comprised ramipril, atenolol, and amlodipine (see lab results).

Test Result Normal Values
Sodium 138 134-146 mmol/L
Potassium 2.9 3.5-5.1 mmol/L
Urea 8 2.75-7.4 mmol/L
Creatinine 88 44-115 µmol/L

73 years old male with high BP recorded at home for 1 week and in hospital before his surgery 200/190 . He is on 3 antihypertensive medication what is the cause of his high BP
A. NSAID B. Pseudoephedrine If high K >> NSAID. If low K >> pseudo.

* NSAIDS are more likely to cause ↑ K^+ levels who already have ↓ renal function
* Pseudoephedrine ↓ K^+

Which of the following is most likely contributing to the treatment failure?

Analgesic nephropathy presents with:
- ATN from direct toxicity to the tubules
- AIN
- Membranous glomerulonephritis
- Vascular insufficiency of the kidney from inhibiting prostaglandins. Prostaglandins dilate the afferent arteriole. NSAIDs constrict the afferent arteriole and decrease renal perfusion. This is asymptomatic in healthy patients. When patients are older and have underlying renal insufficiency from diabetes and/or hypertension, then NSAIDs can tip them over into clinically apparent renal insufficiency.
- Papillary necrosis

A. Antacids

**B. NSAIDs

C. Table salt

Ibuprofen and all NSAIDs are renally toxic; they constrict the afferent arteriole and cause allergic interstitial nephritis and papillary necrosis. Eosinophils are not found in the urine with AKI from NSAIDs.

Corrected

D. Pseudoephedrine

Vascular congestive
Hyper intensities

A 75-year-old man comes to the clinic with hypertension and gradual loss of cognitive function. He has predominant executive function impairment (see report).

MRI:
Reveals diffuse periventricular white-matter hyperintensities. → Subclinical Infarcts

Which of the following is most likely diagnosis?

A. Alzheimer disease

B. Dementia with Lewy bodies

**C. Vascular cognitive impairment

D. Normal pressure hydrocephalus

Dementia

A 77-year-old man with a 7-years history of Parkinson disease reports hallucinations, confusion and worsening motor function. On physical examination, he is akinetic and rigid with no tremor. He has prominent gait disorder and postural instability.

Which of the following symptoms is most strongly associated with an increased risk for dementia?

A. Increase irritability

B. Word-finding difficulty

**C. Trouble recalling appointment times

D. Difficulty reading an article in a single sitting

Cognitive
Memory

A son of 78-year-old patient brought a medical report of his father cognitive function status stating that he has" mild cognitive impairment".

Which of the following is indicating mild cognitive impairment?

A. Low mood for 2 weeks

B. Localized motor dysfunction

**C. Objective evidence of memory decline

D. Impairment in at least 1 activity of daily living

A 78-year-old man presents with a 10-day history of intermittent colicky abdominal pain. The pain is low, central and seems to be worse after eating. He has no associated fever or vomiting but does feel nauseated when the pain is present. He says that prior to this episode he had hard stools once or twice a week that were difficult to pass. For the past several days, he has had only watery stools, several times a day. On examination, there is fullness in his left lower

quadrant with nonspecific tenderness diffusely and no guarding or rebound. A urine dipstick is normal.

Which of the following is the most likely diagnosis?

A. Acute colitis

**B. Constipation

C. Ureteric stone

D. Urinary tract infection

Best exercise
Resistance training

Which of the following is the best exercise to improve the function of a 68-year-old woman?

A. Walking

B. Swimming

**C. Resistance training

D. Stationary bicycling

A 72-year-old man complains of difficulty in getting up from the chair for the last 3 months. History reveals he has controlled type 2 diabetes and long standing hypertension.

Which of the following is the most leading type of injury in this patient?

A. Road traffic accidents

B. Fire-related injuries

C. Gunshot wounds

**D. Falls

HEART

Severe chest pain
MI

A 48-year-old man presents with central and severe chest pain, which started around 1 hour ago. There is no radiation of the pain or associated shortness-of-breath. He has had some similar fleeting pains over the past 2 weeks but these settled spontaneously after a few seconds.

↳ previous Anginas

Which of the following is the most likely diagnosis?

A. Gastro-oesophageal reflux disease

**B. Myocardial Infarction

C. Pneumothorax

D. Anxiety

A 64-year-old man, who has hypertension, presents with increasing shortness of breath. His symptoms are worse at night. On examination, there is bilateral basal crackles and a third heart sound (S3).

Which of the following is the most likely diagnosis?

**A. Heart failure

B. Bronchial asthma

C. Pulmonary fibrosis

D. Obstructive sleep apnea

Angina

A 39-year-old man presents with shortness of breath for 2 weeks. The symptoms associated with activity and relieved by rest. He is otherwise healthy, takes no medications and denies chest pain or pressure.

Which of the following is the most likely diagnosis?

A. Classical angina

**B. Anginal equivalent

C. Musclo-skeletal pain

D. Myocardial infarction

A 77-year-old man with poorly controlled hypertension presents with a 6-months history of fatigue and dyspnea on exertion. He denies edema, orthopnea, chest pain and palpitations. His only medication is hydrochlorothiazide (25 mg) once daily. On examination, he has a grade 2/6 midsystolic ejection murmur, which is loudest at the right upper sternal border. An S4 is heard at the apex, there is no S3. His lungs are clear and there is no peripheral edema.

Which of the following is the most likely diagnosis?

A. Aortic regurgitation

B. Mitral regurgitation

**C. Aortic stenosis

D. Mitral stenosis

Aspirin

A 49-year-old smoker man has type 2 diabetes mellitus, morbid obesity and a recent diagnosis of symptomatic peripheral arterial disease. He is started on atorvastatin (Lipitor), offered a supervised exercise program and discussed smoking cessation and interventions.

Which of the following should be recommended to prevent cardiovascular events?

**A. Aspirin

B. Warfarin

C. Atenolol

D. Enoxaparin SC injection

Prolonged QT
MYCIN

A 34-year-old woman with a history of prolonged QT syndrome presents with severe acute bacterial sinusitis.

Which of the following antibiotics should be avoided?

Clarithromycin
Azithromycin
Erythromycin
} can cause Prolong QT

A. Amoxicillin

B. Moxifloxacin

**C. Clarithromycin

D. Amoxicillin/clavulanate

A 75-year-old man has lung cancer comes to the clinic to manage his back pain. A month ago, his oncologist told him that the prognosis was poor and that he is unlikely to survive for more than a year (see lab result).

Test Result Normal Values
Calcium ionised 3.2 1.1-1.3 mmol/L

Which of the following is the most appropriate next step in management?

**A. Intrvenous isotonic saline

B. Subcutaneous morphine

C. Oral alendronate

D. Oral furosemide

A 68-year-old woman is admitted to the hospital with first episode of acute heart failure. She has a history of hypertension treated with a thiazide diuretic. An echocardiogram reveals no evidence of valvular disease and no segmental wall motion abnormalities. Left ventricular hypertrophy is noted, and her ejection fraction is 55%. 6th June Exam DHA

Which of the following is the most likely cause of her heart failure?

A. Hypertrophic cardiomyopathy

**B. Diastolic dysfunction

C. Systolic dysfunction

D. High-output failure

A 76-year-old woman with a history of hypertension and osteoporosis presents to the clinic for preoperative clearance for an upcoming eye surgery. She complains of progressively worsening fatigue over the past 8 to 10 months. She states she often feels dizzy but denies syncope. Her current medications include alendronate and hydrochlorothiazide.

Which of the following is the most appropriate action?

A. An exercise treadmill test

B. A 48-hour holter monitor

**C. Referral to a cardiologist for evaluation

D. Clearance for eye surgery with no further evaluation

SOB
S4
Jugular veins
Diuretics

A 61-year-old man complains of shortness of breath. He has a history of hypertension, type 2

diabetes and hyperlipidemia. He was a smoker for more than 30 years but he quit 4 years ago. On physical examination, he is not in respiratory distress, but he has diffuse wheezing bilaterally over lower lobes of his lungs. His cardiac examination demonstrates an S4 and distended jugular veins.

Which of the following is the best treatment to relieve his symptoms?

A. Anticoagulant therapy

B. Steroid therapy

**C. Diuretics

D. Aspirin

Ischemia ECG

A 38-year-old man has episodic chest pain. He states that the pain feels like tightness, located right behind his sternum, lasts less than 3 minutes and is relieved with rest. He takes no medications. He has no family history of coronary disease and has never smoked. His ECG in the office is normal.

What is the most appropriate test to exclude cardiac ischemia?

A. Cardiac CT

**B. Exercise ECG

C. Resting echocardiogram

D. Creatine kinase enzyme

Systolic

A 55-year-old man has congestive heart failure due to left ventricular systolic dysfunction. He has no history of medications allergy or interaction.

Which of the following is the best first-line treatment option?

**A. ACE inhibitors and diuretics

B. Hydralazine and β-Blockers

C. β-Blockers and diuretics

D. Nitrates and β-Blockers

Atrial fibrillation

A 58-year-old man has chronic atrial fibrillation.

Pt with atrial fibrillation, **what is the most common cause of death**
A. MI. **B. sudden cardiac death**

Which of the following is this patient at increased risk for?

A. Acute myocardial infarction

**B. Cerebrovascular accident / Stroke

C. Sudden cardiac death

D. Ventricular fibrillation

Q. When asked about MCC of Death.

Which of the following is the most common cause of death from CHF? / MCC of Death in pt ē Afibrillation.
↓
Sudden cardiac Death

a. Pulmonary edema
b. Myocardial infarction
c. Arrhythmia/sudden death
d. Emboli
e. Myocardial rupture

A 55-year-old man presents to the clinic with history of atrial fibrillation.

What is the drug of choice to prevent complications of his condition?

**A. Prophylactic warfarin

B. Prophylactic heparin

C. Prophylactic lidocaine

D. No drug is recommended

MI

Metoprolol

A 59-year-old man is admitted to the hospital with infero-lateral myocardial infarction.

Which of the following medications would improve his survival?

A. Hydrochlorothiazide

**B. Metoprolol

C. Morphine

D. Warfarin

MI → β-blocker

HF → ACE

A 56-year-old man has a low-pitched diastolic rumble heard at the apex, a widened pulse pressure and a grade 3/6 diastolic decrescendo murmur at the left sternal border.

Which of the following is the most likely diagnosis?

A. Hypertrophic cardiomyopathy

B. Pulmonic insufficiency

**C. Aortic regurgitation

D. Mitral stenosis

MI

A 60-year-old man, with type 2 diabetes, presents with persistent diffuse neck pain for the past hour, diaphoresis, shortness of breath, a normal troponin I level, and an electrocardiogram that reveals only nonspecific ST-segment and T-wave changes.

Which of the following is the most appropriate next step in management?

A. Administer oral ibuprofen

B. Recheck the troponin I level in 6 hours

C. Perform a right-sided electrocardiogram

**D. Administer aspirin and sublingual nitroglycerin

A 42-year-old man presented with worsening pleuritic, positional chest pain. Examination revealed pericardial rub, a clear lung examination, and no evidence of lower-extremity edema. ECG shows non-diagnostic findings.

Which of the following is the most appropriate next step for diagnosis?

A. D-dimer testing

B. Exercise stress testing

C. Referral to echo-cardiograph specialist

**D. Reassure the patient about insignificant symptoms

A 26-year-old woman had 2 episodes of syncope in the past 2 months during micturition and coughing. Physical examination and electrocardiogram are unremarkable.

Tilt table
Syncope

Which of the following is the most appropriate management options?

A. Transthoracic echocardiogram

**B. Reassurance and education

C. Holter monitor

D. Tilt-table test

A 22-year-old woman with vasovagal syncope comes to the clinic. She has a normal physical examination and a normal electrocardiogram.

Which of the following management approaches is most appropriate?

**A. Reassurance and explanation

B. Echocardiogram

C. Tilt-table study

D. Holter monitor

GIT

Hematemesis
Spider angiomata

A 60-year-old man admitted to the Emergency Room with 1-day history of hematemesis. He has multiple spider angiomata on his chest with bilateral gynecomastia. Abdominal examination showed splenomegaly (see lab results).

Blood pressure 100/60 mmHg
Heart rate 100 /min
Respiratory rate 18 /min
Temperature 36.6 °C
Oxygen saturation 95 %

Test Result Normal Values
Hb 8.5 130-170 g/L (Male)
120-160 g/L (Female)
HCT 0.23 0.42-0.52 (Male)
0.37-0.48 (Female)

Which of the following is the most appropriate next step in management after the initial fluid resuscitation?

A. Blood transfusion

**B. Upper GI endoscopy

C. Selective angiography

D. Nasogastric tube insertion

A 22-year-old man presented with 6-month history of non-bloody diarrhoea, recurrent abdominal cramps and weight loss. On examination, he looked pale with oral ulcers. Abdominal examination showed tender right lower quadrant.

Blood pressure 110/70 mmHg
Heart rate 100 /min
Temperature 38.1 °C

Which of the following is the most likely diagnosis?

A. Celiac disease

**B. Crohn's disease

C. Ulcerative colitis

D. Chronic appendicitis

A 35-year-old woman presented with chronic vague gastric pain for several years. The pain is revealed by food. Serum immunoglobulin studies for IgG against helicobacter pylori was positive. Upper GI endoscopy showed antral gastritis with small clean bases ulcer at duodenum. The patient was treated for H.pylori.

Which of the following is the most appropriate test to ensure h pylori eradication?

A. Rapid urease test

**B. Urea breath test

C. Culture of gastric mucosa

D. Repeat IgA and IgG against H.pylori

TABLE 2.6-6. Tests for *H pylori*

TEST	DESCRIPTION	TEST CHARACTERISTICS
Urea breath test	*H pylori* urease converts radio-labeled urea (C14 or C13) to CO_2 and ammonia; this test detects CO_2 formed from urea metabolism	High specificity, lower sensitivity PPIs may cause false ⊖ results
Stool antigen test	Stool antigen test detects *H pylori* antigens in stool	High specificity, high sensitivity Cost-effective initial test for *H pylori* Must be off PPI ×2 weeks prior to testing
Endoscopic biopsy	Endoscopic biopsy detects *H pylori* on histology or culture; it can also detect intestinal metaplasia, mucosa-associated lymphoid tissue (MALT), or widespread gastritis	Gold standard for diagnosis of gastritis and *H pylori* Most invasive test Must be off PPI ×2 weeks prior to endoscopy

Nodular enlarged liver

A 60-year-old man presented with jaundice for 2 months. Physical examination revealed a nodular enlarged liver (see report).

CT Scan:
Showed cirrhotic liver with 2 lesions at right lobe measuring 4 x 5 cm.

Which of the following risk factors is strongly associated with this condition?

A. Aflatoxin

B. Lead toxin

C. Wilson disease

**D. Hepatitis B infection

🌹liver **nodules what is the cause?**

A. Aflatoxin B. Lead toxin C.**Hepatitis b** ✅✅ D. Wilson disease

PSC
strictures
ALP

A 35-year-old man with a 7-year history of ulcerative colitis, presented with insidious onset of progressive fatigue, pruritis and jaundice. He underwent MRCP, which demonstrates multiple short strictures of biliary tree at both intrahepatic and extrahepatic ducts (see lab results).

↑ ALP, ↑ GGT, ↑ Bilirubin

Next Step: PT, INR (to see liver damage)

Most Accurate: ERCP / MRCP

Test Result Normal Values
Alkaline phosphatase 785 39-117 IU/L
Alanine aminotransferase 60 5-40 IU/L
Aspartate aminotransferase 40 12-40 IU/L
Creatinine kinase 34 24-170 IU/L (Female)
24-195 IU/L (Male)

Which of the following is the most likely diagnosis?

A. Liver cirrhosis

B. Bile duct atersia

C. Primary biliary cholangitis

**D. Primary sclerposing cholangitis → 80% associated ē IBD

Pancreatitis
Hypertriglyceride

A 40-year-old man with a history of hypertriglyceridemia presents to Emergency Room with 4-hour of sever epigastric pain, nausea, and vomiting. The pain was steady and radiate to the back. The patient was in pain and agitated (see lab results and report).

Blood pressure 100/70 mmHg
Heart rate 110 /min
Respiratory rate 23 /min
Temperature 38.3 °C
Oxygen saturation 94 %

Test Result Normal Values
RBC 5 4.7-6.1 x 1012/L (Male)
4.2-5.4 x 1012/L (Female)
Hb 12 130-170 g/L (Male)
120-160 g/L (Female)
HCT 39 0.42-0.52 (Male)
0.37-0.48 (Female)
Platelets count 344 150-400 x 109/L
WBC 16 4.5-10.5 x 109/L
Alanine aminotransferase 97 5-40 IU/L
Aspartate aminotransferase 87 12-40 IU/L
Amylase 150 24-151 IU/L
Lactate dehydrogenase 169 60-160 IU/L
Lipase 30 0-160 IU/L

Plain Abdominal X-ray:
Showed an air-filled intestinal loop at left upper quadrant.

Which of the following is the most likely diagnosis?

**A. Acute pancreatitis

B. Bowel perforation

C. Mesentric ischemia

D. Diverticular disease

Hep C
Ascites
Neutrophils

A 62-year-old patient known case of chronic hepatitis C presented with abdominal pain and swelling. Examination showed ascites, abdominal tenderness and peripheral edema. Diagnostic ascitic tap done and revealed a neutrophil count of 400/mm (<250 mm)

Blood pressure 110/70 mmHg
Heart rate 90 /min
Temperature 37.6 °C

Which of the following is the appropriate next step in the management?

A. Fluid restriction

B. Oral spironolactone

**C. Intravenous antibiotics

D. Therapeutic paracentesis

A 69-year-old man seen in Outpatient Clinic for a routine check-up. No relevant history, apart from occasionally low back pain on non-steroidal anti-inflammatory drugs as needed. No chronic medical history. On examination, his abdomen was soft with no masses. Rectal examination was normal (see lab results).

Test Result Normal Values
RBC 4 4.7-6.1 x 1012/L (Male)
4.2-5.4 x 1012/L (Female)
Hb 8 130-170 g/L (Male)
120-160 g/L (Female)
HCT 38 0.42-0.52 (Male)
0.37-0.48 (Female)
MCH 23 28-33 pg/cell
MCV 70 80-95 fl
Platelets count 456 150-400 x 109/L
WBC 5 4.5-10.5 x 109/L

Which of the following is the most important next step?

A. Sigmoidoscopy

B. Ultrasound abdomen

C. Stool for occult blood

**D. Upper and lower GI endoscopy

Which of the following is the best indicator that a pregnant woman will transmit infection to her child?

a. Bilirubin
b. e-Antigen
c. Surface antigen
d. Core IgM antibody
e. ALT
f. Anti-hepatitis B, e-antibody

Answer: B. The correct answer is e-antigen. The exam question may offer DNA polymerase or PCR for viral load as a choice instead of e-antigen. The only difference is that e-antigen is a qualitative test, meaning it is simply positive or negative. DNA viral load is a quantitative test, meaning it gives a level that is highly variable. It is like the gas tank in your car. Hepatitis B e-antigen tells you, "Gas present: yes or no." DNA viral load is like the gauge on your tank: It tells an amount. If a woman is positive for surface antigen, but the e-antigen is negative, only 10% of children will become infected with hepatitis B at birth. When both surface antigen and e-antigen are positive, 90% of children will be infected at birth. This is why perinatal transmission is the most common method of transmission worldwide.

Hep B vaccine
Immunoglobulins

A 34-year-old pregnant woman, known case of chronic hepatitis B, comes to the clinic for counselling regarding the risk of hepatitis B transmission to her baby (see lab results and report).

Test Result Normal Values
Alkaline phosphatase 198 39-117 IU/L
Alanine aminotransferase 120 5-40 IU/L
Aspartate aminotransferase 67 12-40 IU/L

Hepatitis B viral load:
1 million copies/ml.

Which one of the following the baby should receive to reduce the vertical transmission risk?

A. Hepatitis b vaccine

B. Hepatitis b immunoglobulin

**C. Hepatitis b vaccine and immunoglobulin

D. Hepatitis b vaccine, immunoglobulin and entecavir

Cholestasis Pregnancy

A 32-year-old woman 30-week pregnant G1+0+0, presented to the clinic with pruritus and jaundice. There is no fever, abdominal pain, or vomiting. She is not on any medications and no chronic medical illness (see lab results).

Test Result Normal Values
Hb 11 130-170 g/L (Male)
120-160 g/L (Female)
Platelets count 160 150-400 x 109/L
WBC 7 4.5-10.5 x 109/L
Alkaline phosphatase 700 39-117 IU/L
Alanine aminotransferase 79 5-40 IU/L
Aspartate aminotransferase 100 12-40 IU/L

Which of the following is the most likely diagnosis?

A. Viral hepatitis

B. Hellp syndrome

C. Budd chiari syndrome

**D. Cholestasis of pregnancy

A 47-year-old alcoholic patient presented with 6-week history of weight loss, fever, and rt hypochondrium pain (see lab result and report).

Test Result Normal Values
Alpha fetoprotein 120 0-40 ng/mL

Abdominal Ultrasound:
Showed ascites and focal liver lesion in a cirrhotic liver.

Which of the following is the most likely diagnosis?

A. Liver abscess

B. Pancreatic cancer

C. Hydatid liver disease

**D. Hepatocelluar carcinoma

A 23-year-old woman was informed that her husband has chronic hepatitis B infection. She was worried that he had transmitted the virus to her. She is currently asymptomatic apart from fatigue.

What is the first evidence of acute infection in her case?

A. HBeAg

**B. HBsAg

C. Anti-HBc

D. Anti-HBs

Needle stick

A surgeon was performing a procedure on a patient with chronic hepatitis C infection. He accidentally had a needle stick injury.

What is the likelihood of hepatitis C transmission?

A. 0.03 %

B. 0.3 % — HIV

**C. 3 % — Hep C

D. 30 % — Hep B

Celiac

A 16-year-old man presented to the Outpatient Department complaining of diarrhoea for 3 years. He was passing 3-4 large volume stool per day, which was foul smelling and contained undigested food but no blood or mucus. He was also complaining of postprandial bloating and easy fatigability. On examination, he looked pale and has no secondary sexual characteristics (see lab results).

BMI 14 kg/m2

Test Result Normal Values
Hb 10 130-170 g/L (Male)
120-160 g/L (Female)
MCV 70 80-95 fl
Platelets count 433 150-400 x 109/L
Alanine aminotransferase 90 5-40 IU/L
Aspartate aminotransferase 60 12-40 IU/L
ESR 12 2-10 mm/h (Male)
3-15 mm/h (Female)

Which of the following is the most appropriate diagnostic test?

A. Stool for fat content

B. Barium follow through

C. Lactose hydrogen breath test

Unique tests for celiac disease: Gluten sensitive enteropathy

- Anti-tissue transglutaminase (TTG) is the first test (can be falsely negative in IgA deficiency).
- Antiendomysial antibody
- IgA antigliadin antibody

Most Accurate: Endoscopic Biopsy (of bowel)

↓

also rules out T-cell lymphoma in Celiac

Rx: Gluten free diet

**D. IgA antiendomysial antibodies

Bloody diarrhoea
Ulcerative colitis
Mesalamine

A 24-year-old man presented with 2-month of bloody diarrhoea. He passes 3-4 loose motions /day associated with blood and mucus. He gave history of left lower quadrant pain. No fever or weight loss. He underwent sigmoidoscopy, which showed loss of normal vascular pattern with erosions up to splenic flexure (see lab results).

Test Result Normal Values
RBC 5
4.7-6.1 x 1012/L (Male)
4.2-5.4 x 1012/L (Female)
Hb 10.9 130-170 g/L (Male)
120-160 g/L (Female)
Platelets count 488 150-400 x 109/L
WBC 6 4.5-10.5 x 109/L
ESR 32 2-10 mm/h (Male)
3-15 mm/h (Female)
Consistency LIQUID (soft or tight)
Color YELLOW Brown
Mucus and blood ++ absent
Leukocytes +++ solitary

Which of the following is the best treatment option?

A. Mesalamine enema

B. Mesalamine suppository

**C. Mesalamine oral and enema

D. Mesalamine oral and suppository

A 60-year-old man with chronic history of heartburn for several years, presented with occasional hematemesis. Upper GI endoscopy revealed intestinal-type metaplasia at the distal oesophagus.

Which of the following is the most likely diagnosis?

A. Oesophagitis

B. Mallory-weiss tear

**C. Barretts oesophagus

D. Plummer vinson syndrome

Acute
Ulcerative colitis
Prednisolone

A 30-year-old woman with left-sided ulcerative colitis presented to Emergency Room with 7-8 bloody diarrhoea /day associated with low-grade fever, abdominal pain and joint pain at her knees. On examination, she looks ill and in pain. All stool cultures were negative.

Blood pressure 90/70 mmHg
Heart rate 120 /min
Respiratory rate 18 /min
Temperature 37.3 °C
Oxygen saturation 95 %

Test Result Normal Values
Hb 9 130-170 g/L (Male)
120-160 g/L (Female)
Platelets count 456 150-400 x 109/L
WBC 10 4.5-10.5 x 109/L
ESR 122 2-10 mm/h (Male)
3-15 mm/h (Female)

After fluid resuscitation what is the best next step in management?

A. Azathioprine

B. Sulphasalazine

C. Oral budesonide

**D. Iv methylprednisolone

Hepatitis IgM

A 28-year-old man who was previously healthy, presented to the Emergency Department with 5-days history of right upper quadrant abdominal pain, which was associated with nausea and 2 episodes of vomiting. 2 days later, his family noticed yellowish discolouration of his eyes and skin. No history of alcohol or drug use. On examination, he was jaundiced. Abdominal exam showed tender right upper abdomen (see lab results).

Test Result Normal Values
Alkaline phosphatase
109 39-117 IU/L

Alanine aminotransferase 990 5-40 IU/L
Aspartate aminotransferase 789 12-40 IU/L

Which of the following is the most appropriate next step in diagnosis?

A. Hepatitis A IgG

**B. Hepatitis A IgM

C. Hepatitis B antigen

D. Hepatitis C antibodies

A 17-year-old man with no previous medical history, presented with 3-weeks history of bloody diarrhoea. He reported frequent urges to defecate, associated with mild lower abdominal cramps. He had experienced similar attacks in the past, but milder associated with bloating and loose stool, which was mucus with few blood drops. Abdominal examination was soft with mild tenderness at left lower quadrant but no guarding.

Blood pressure 110/70 mmHg
Heart rate 76 /min
Temperature 36.6 °C
Oxygen saturation 95 %

Which of the following is the most likely diagnosis?

A. Diverticulitis

B. Ischaemic colitis

C. Crohn's disease

**D. Ulcerative colitis

Wilson Ring

A 20-year-old man with a history of high liver function test in the past presents, with tremors and dysarthria and dyskinesia. Slit-lamp examination reveals a greenish-brown ring at corneoscleral junction.

Which of the following is the most likely diagnosis?

A. Antitrypsin deficiency

B. Hepatic hemangioma

C. Hemochromatosis

**D. Wilsons disease

A 22-year-old woman with chronic diarrhoea and malabsorption is suspected of having coeliac disease, a jejunal biopsy taken.

Which of the following histological finding is expected?

A. Flattened crypts

**B. Subtotal villous atrophy

C. Epithelial cells with fat globules

D. Fissures and ulcers penetrating into submucosa

Bronze colored Hemochromatsis

A 50-year-old man presents with 3-months history of jaundice, arthralgia, increase in skin pigmentation, and upper abdominal discomfort. He is on oral hypoglycemic medications for recently diagnosed diabetes mellitus. His viral hepatitis screening was negative. Examination revealed a bronze coloured skin, enlarged liver with span of 15 cm, no splenomegaly, and testicular atrophy. Cardiac examination revealed a 3rd heart sound (see lab results).

Test Result Normal Values
Direct bilirubin 24 1.5-6.5 µmol/L
Total bilirubin 31 3.5-16.5 µmol/L
Aspartate aminotransferase 79 12-40 IU/L
Alanine aminotransferase 112 5-40 IU/L
Alkaline phosphatase 109 39-117 IU/L
Random Glucose 7 3.9-5.5 mmol/L
Ferritin 400 20-300 µg/L (Male)
20-120 µg/L (Female)

Which of the following investigations is the most appropriate next step?

A. Alpha 1-antitrypsin

B. 24 hours urinary copper

C. Antimitochondrial antibodies

**D. Hepatic iron load in liver biopsy

A 31-year-old patient came to Emergency Room with 1-day history of melena and dizziness. He has no significant medical history and takes no medications apart from ibuprofen for dental pain for 5 days. Examination revealed cold extremities, and faint peripheral pulses. Per-rectal examination revealed maroon coloured stool (see lab results).

Blood pressure 90/60 mmHg
Heart rate 120 /min
Respiratory rate 18 /min
Temperature 36.6 °C
Oxygen saturation 95 %

Test Result Normal Values
RBC 4.3 4.7-6.1 x 1012/L (Male)
4.2-5.4 x 1012/L (Female)
Hb 8.7 130-170 g/L (Male)
120-160 g/L (Female)
Platelets count 343 150-400 x 109/L
WBC 8 4.5-10.5 x 109/L

Which of the following is the most appropriate next step in the management?

**A. Normal saline

B. Colloid solution

C. Blood transfusion

D. Albumin and ringer lactate

Calprotectin
Ulcerative

A 25-year-old woman came to the clinic for an advice. She is planning to get pregnant; she is a known case of distal ulcerative colitis diagnosed 3 years ago on 3 grams of mesalamine granules. Her last exacerbation was a year ago required a short course of steroid. Currently she has a 2-3 bowel motions a day, occasionally seen a streaks of blood once every 4-5 weeks. Her latest fecal calprotectin is 90 (normal 0-50).

Which one of the following is the most appropriate advice?

A. It is difficult to get pregnant now

**B. She can get pregnant as her disease is controlled

C. Her risk of abortion is high and should be counselled

D. It is advisable to postpone the pregnancy for 3 years

A 65-year-old man known case of diabetes mellitus and hypertension presents to Emergency Room with 1-day history of vomiting fresh blood and melena. He is taking aspirin 81 mg daily. After fluid resuscitation, he was started on IV PPI. He underwent upper GI endoscopy, which revealed a 2 cm duodenal ulcer at the bulb with visible vessel seen, endoscopic hemostasis

was done using endo clip

Which of the following is the recommended duration for IV PPI post endoscopic management?

A. 24 hours

B. 36 hours

C. 48 hours

**D. 72 hours

Crohns
Vaccine live
Time duration

A 30-year-old woman a known case of fistulizing crohn's disease on biological therapy and azathioprine. She is pregnant on her third trimester. Her physician is planning to communicate with her obstetrician prior to her delivery about her delivery method and the vaccination of the child.

Which of the following is the recommended advice for the child vaccinations?

A. All vaccines can be given safely

B. Live attenuated vaccines are contraindicated

C. All vaccines should be postponed till 6 months

**D. Live attenuated vaccines should be postponed for 12 months

A 65-year-old man presented with melena and hematemesis. He is a known case of diabetes mellitus, hyperlipidaemia, and he is on aspirin 81 mg, lipitor 20 mg, diamicron 80 mg and warfarin 3 mg a day. Underwent upper GI endoscopy and showed multiple superficial ulcers at the antrum and duodenal bulb.

Which of the following medications is most strongly associated with his presentation?

**A. Aspirin

B. Lipitor

C. Warfarin

D. Diamicron

A 21-year-old patient presented with 4-months history of itchy skin rash over his elbows with abdominal bloating and diarrhoea. No other medical problems. He has a cousin with similar condition. He underwent upper and lower GI endoscopy. Multiple duodenal erosions seen at the 1st and 2nd part with scalloping (see lab results and reports).

Test Result Normal Values
RBC 4 4.7-6.1 x 1012/L (Male)
4.2-5.4 x 1012/L (Female)
Hb 10.9 130-170 g/L (Male)
120-160 g/L (Female)
Alkaline phosphatase
112 39-117 IU/L

Alanine aminotransferase 123 5-40 IU/L
Aspartate aminotransferase 79 12-40 IU/L

Calcium 1.9 2.15-2.62 mmol/L
Random Glucose 6 3.9-5.5 mmol/L

Ileocolonoscopy:
Normal.

Duodenal biopsy:
Showed subtotal villous atrophy.

Which of the following is the best treatment option?

A. Oral steroid

B. Iv pantoprazole

**C. Start gluten free diet

D. Oral iron tablets and repeat endoscopy in 3 months

Crohn
Osteoporosis

Osteoporosis is one of common extra-intestinal manifestations of crohn's disease, which carries a concomitant fracture risk.

Which of the following risk factors are more likely to be strongly associated with increase osteoporosis risk in crohn's disease?

A. Age 20-40

B. Premenopausal

**C. Long steroid use

D. Extensive colonic involvement

GERD
Ranitidine

A 35-year-old woman with heartburn and regurgitation for 6 months is referred for evaluation of chronic GERD symptoms. The patient states that she notes burning in her chest primarily after meals and occasionally experiences episodes of chest pain. She denies change in weight or lifestyle. She often consumes dinner 2 hours before going to bed. Her heartburn occurs mainly during the night. Physical examination is normal except for a body mass index (BMI) of 28 kg/m2. A complete blood count and metabolic panel are normal. The patient has been taking omeprazole 20 mg daily. An upper endoscopic examination is performed, and the appearance of distal esophagitis

Which of the following is the best next step?

A. Add antacid twice/day

**B. Ranitidine at bed time

C. Advise her to lose weight

D. Refer her for Nilsson Fundoplication

Crohns
Fistula

A 32-year-old man came to the clinic for follow-up visit. He is diagnosed of iloecolonic crohn's disease started on steroid and pentasa for 3 months. He noticed perineal pain and discharges for 3 weeks duration. His abdominal symptoms are well controlled with no abdominal pain or diarrhoea. Examination was normal apart from 2 perianal fistula were seen (see lab results and

report).

Test Result Normal Values
RBC 4 4.7-6.1 x 1012/L (Male)
4.2-5.4 x 1012/L (Female)
Hb 11 130-170 g/L (Male)
120-160 g/L (Female)
Platelets count 421 150-400 x 109/L
WBC 7 4.5-10.5 x 109/L
ESR 36 2-10 mm/h (Male)
3-15 mm/h (Female)

MRI Pelvis:
Confirmed the presence of perianal fistulae.

Which of the following is the best next step in management?

A. Methotrexate

B. Azathiporine

C. Budesonide

**D. Infliximab

Colonoscopy screening

A 40-year-old healthy man came to the clinic requesting a screening colonoscopy. He is asymptomatic with no family history of colon cancer. Clinical examination is unremarkable (see lab results).

Test Result Normal Values
RBC 4 4.7-6.1 x 1012/L (Male)
4.2-5.4 x 1012/L (Female)
Hb 13.3 130-170 g/L (Male)
120-160 g/L (Female)
Platelets count 321 150-400 x 109/L
WBC 4 4.5-10.5 x 109/L

Based on the latest recommendation from local and international gastroenterology associations, what is the recommended age of screening colonoscopy for this average risk patients?

**A. 45

B. 55

C. 65

D. Order for him now

Routine Screening: 50 yrs – Every 10 years

1 Family memb : 10 yr earlier at which
ē colon CA family mem. developed CA.

Previous Colon CA: 1yr, 3yr, 5yr (post resection)
resection Hx

HPYLORI ERADICATION
Quadruple

A 40-year-old man presented with several months history of dyspepsia. He denies any history of dysphagia, vomiting, or weight lost. He has no significant past medical history and not on any medications. He received helicopter pylori eradication (PPI standard dose, clarithromycin 500mg, and amoxil 1g bid for 10 days) with partial response. Basic routine lab was normal (see reports).

Rattafy

Endoscopy:

TRIPLE : PPI + Clarithromycin + Amoxicillin

Showed gastric erosions.

Biopsy:
Showed h pylori organism.

QUADRUPLE : PPI + Bismuth + Metronidazole + Tetracycline

Which of the following is the best treatment regimen?

A. Repeat the same regimen for a longer duration 14 days

B. PPI , nitromidazole 500mg bid, doxacyclin 100mg qid for 14 days

C. PPI, levofloxacin 500mg qid, amoxil 1 g bid, nitromidazole 500mg bid for 14 days

**D. PPI, bismuthsubcitrate 300mg qid, tertacycline 500mg oid , metronidazole 500mg tid for 14 days

A 45-year-old woman presented with 9-months history of worsening dysphagia for both solid and liquid. Recently she had episodes of ill-defined central chest discomfort and nocturnal cough. Clinical examination was unremarkable (see lab results).

Test Result Normal Values
RBC 5 4.7-6.1 x 1012/L (Male)
4.2-5.4 x 1012/L (Female)
Hb 11.8 130-170 g/L (Male)
120-160 g/L (Female)
Platelets count 300 150-400 x 109/L
WBC 7 4.5-10.5 x 109/L
ESR 13 2-10 mm/h (Male)
3-15 mm/h (Female)

Which of the following is the most likely diagnosis?

**A. Achalasia

B. Esophageal web

C. Pharyngeal pouch

D. Squamous cancer of oesophagus

A 45-year-old man with several months of worsening dyspepsia. He denies any history of diarrhoea, fever, or weight loss. He has no medical problems. He was prescribed pantoprazole 40 mg daily with no relieve of his symptom (see reports).

Upper GI endoscopy:
Showed multiple antral superficial ulcers.

Biopsy:
Revealed mucosa-associated lymphoid tissue (malt) lymphoma with numerous H.pylori organism.

CT scan of abdomen and chest:
Normal.

Which of the following is the best management option?

A. Chemotherapy

B. Radiotherapy

C. Gastrectomy

**D. H.pylori eradication

HCV HEPATITIS

A 45-year-old healthy man recently diagnosed with hepatitis C virus (HCV) infection and was referred to the clinic for initiation of HCV therapy. HCV RNA viral load quantitation was 2 million IU/ml and a Genotype 4, a Liver ultrasound that was normal with no cirrhosis or focal liver lesions (see lab results and report).

Test Result Normal Values
RBC 5 4.7-6.1 x 1012/L (Male)
4.2-5.4 x 1012/L (Female)
Hb 13 130-170 g/L (Male)
120-160 g/L (Female)
Platelets count 233 150-400 x 109/L
WBC 5 4.5-10.5 x 109/L
Alanine aminotransferase 89 5-40 IU/L
Aspartate aminotransferase 56 12-40 IU/L
Creatinine 100 44-115 µmol/L

Fibroscan:
Showed fibrosis score of F3.

Which of the following is the recommended treatment?

A. Entacavir

B. Peg-interferon

**C. Ledipasvir/sofosbuvir OR Sofosbuvir + Velpatasvir

D. Observe and repeat lab in 3 months

Carcinoid

A 50-year-old woman presented with few months history of feeling dizziness when getting out of bed she also feels very warm and flushed. She visited the Emergency Room several times with frequent episodes of abdominal cramps and watery diarrhoea over the past year. She gave a history of itchy skin. On examination, she has a 2/6 systolic murmur at left lower sternal border, chest examination reveals wheezing, abdomen was unremarkable. Laboratory results and stool cultures were normal.

Which of the following is the most appropriate next step

A. Ultrasound abdomen and pelvis

B. Double contrast barium enema

C. Serum lipase and amylase level

**D. Urine for 5-hydroxindoleacetic acid

CARCINOID SYNDROME

Carcinoid syndrome presents with intermittent diarrhea in association with:

- Flushing
- Wheezing
- Cardiac abnormalities of the right side of the heart

The best initial diagnostic test is the urinary 5-hydroxyindoleacetic acid (5 HIAA) test. Treatment is octreotide, a synthetic version of somatostatin, to control the diarrhea.

A 30-year-old man presented with 1-day of sever epigastric pain radiating to the back with vomiting. He gave a history of alcohol drinking occasionally. No other medical problems and not

on any medications. On examination, tender upper abdomen without guarding (see lab results).

Blood pressure 98/70 mmHg
Heart rate 110 /min
Respiratory rate 18 /min
Temperature 37.2 °C

Test Result Normal Values
Hb 11.6 130-170 g/L (Male)
120-160 g/L (Female)
Platelets count 311 150-400 x 109/L
WBC 13 4.5-10.5 x 109/L
Alkaline phosphatase
120 39-117 IU/L

Alanine aminotransferase 65 5-40 IU/L
Aspartate aminotransferase 89 12-40 IU/L
Lipase 770 0-160 IU/L

Which of the following is the most appropriate next step?

**A. Normal saline

B. Order urgent ercp

C. Broad spectrum antibiotic

D. CT scan of the abdomen with contrast

A 34-year-old man diagnosed of ileocolonic crohn's disease on infliximab and azathioprine came to the clinic complaining of perianal pain and discharge with low-grade fever for 3 weeks durations. He has a 3-4 non-bloody bowel motions /day. He has a perianal induration and purulent discharge on pressure.

Blood pressure 110/70 mmHg
Heart rate 76 /min
Temperature 37.9 °C

Which of the following is the appropriate next step in the patient management?

**A. Order MRI pelvis

B. Broad spectrum antibiotics

C. Swab from the perianal discharge

D. Increase infliximab dose and reduce the frequency

IBD

A 23-year-old woman complaining of 4-months history of abdominal discomfort with alternating bowel habit. Recently she gave a history of bloating and passing mucus with stool and noticed increase in bowel motions 3-4/day. The abdominal pain was relieved by defecation with no nocturnal symptoms. She has no weight loss or fever. She is worried about serous diagnosis as her uncle was diagnosed as colon cancer at the age of 60. Clinically is unremarkable (see lab results).

Test Result Normal Values
RBC 3.7 4.7-6.1 x 1012/L (Male)
4.2-5.4 x 1012/L (Female)
Hb 11 130-170 g/L (Male)
120-160 g/L (Female)
Platelets count 332 150-400 x 109/L
WBC 5 4.5-10.5 x 109/L
ESR 10 2-10 mm/h (Male)
3-15 mm/h (Female)
Alanine aminotransferase 34 5-40 IU/L
Aspartate aminotransferase 23 12-40 IU/L
Amylase 122 24-151 IU/L

Which of the following is the most likely diagnosis?

A. Gastroenteritis

B. Ulcerative colitis

C. Colo-rectal cancer

**D. Irritable bowel disease

Triphasic CT

A 62-year-old woman with long standing history of pruritis and fatigue presented to the clinic with a 2-months history of jaundice and abdominal swelling. On examination, scratch marks seen. She was jaundiced with clubbing of her fingers. Abdominal examination revealed splenomegaly with ascites (see lab results and report).

Test Result Normal Values
RBC 4 4.7-6.1 x 1012/L (Male)
4.2-5.4 x 1012/L (Female)
Hb 11 130-170 g/L (Male)
120-160 g/L (Female)
Platelets count 102 150-400 x 109/L
WBC 3 4.5-10.5 x 109/L
INR 1.5 0.8-1.2
Alkaline phosphatase
170 39-117 IU/L
Alanine aminotransferase 78 5-40 IU/L
Aspartate aminotransferase 112 12-40 IU/L

US Abdomen:
Showed coarse liver with 3 cm focal lesion at rt lobe.

Which of the following is the most appropriate next step?

A. Alpha- fetoprotein

B. Biopsy for the lesion

C. Doppler ultrasound of liver

**D. Triphasic CT scan of the abdomen

SLE
Interphase hepatitis

A 34-year-old woman presented with 2-months history of jaundice and upper abdominal discomfort. She is known case of SLE on hydroxycholorquine. She also gave history of pruritis and fatigue. Clinical examination revealed obesity and hepatomegaly (see lab results and reports).

Test Result Normal Values
Direct bilirubin 32 1.5-6.5 µmol/L
Total bilirubin 43 3.5-16.5 µmol/L
Aspartate aminotransferase 654 12-40 IU/L
Alanine aminotransferase 734 5-40 IU/L
Alkaline phosphatase 129 39-117 IU/L
Gamma glutamyltransferase 60 6 to 37 IU/L
Random Glucose 7 3.9-5.5 mmol/L
Globulin 43 21-36 g/L

US Abdomen:
Showed enlarged liver with bright coarse echogenicity.

Viral Hepatitis:
Negative.

ANA:
1:640

Liver Biopsy:
Inter phase hepatitis with plasma cells.

Which of the following is the most appropriate next step in management?

**A. Prednisolone

B. Methotrexate

C. Vitamin e with weight loss

D. Ursodeoxycholic acid

A 33-year-old man with 2-years history of heartburn and food regurgitation, he was taking 40 mg of pantoprazole daily with good response. He stopped it 4 months ago and started to have recurrence of his symptoms and becoming worse. No dysphagia or weight loss or nocturnal symptoms. Clinically was normal. All routine laboratory workup was normal.

Which of the following is the best next step in his management?

A. PPI high dose (80 mg)

B. Ranitidine twice a day

**C. Resume PPI at the same dose

D. PPI high dose and ranitidine

A 40-year-old patient presented with chronic constipation. No alarm symptoms. No other medical problems and not on any medication. Examination was normal including rectal examination. All lab workup, thyroid function, calcium, and fasting glucose were normal. Stool for occult blood was negative.

Which of the following is the most appropriate treatment?

A. Senna

B. Lactulose

C. Magnesium phosphate

**D. Bulking agent (psyllium)

A 34-year-old man patient a known case of ulcerative colitis on azathioprine 100mg/day and tapering dose of steroid presented to the clinic with 6-7 bloody bowel motions, lower abdomen pain and low grade fever. On abdominal examination, there is mild tenderness at left lower abdomen. Stool culture was negative. Stool for colostrum difficile toxins was positive (see lab results).

Blood pressure 110/70 mmHg
Heart rate 100 /min
Temperature 38.4 °C
Oxygen saturation 95 %

Test Result Normal Values
RBC 5 4.7-6.1 x 1012/L (Male)
4.2-5.4 x 1012/L (Female)
Hb 11 130-170 g/L (Male)
120-160 g/L (Female)
Platelets count 456 150-400 x 109/L
WBC 16 4.5-10.5 x 109/L
ESR 67 2-10 mm/h (Male)
3-15 mm/h (Female)
Albumin 29 34-56 g/L

Which of the following is the most appropriate treatment?

A. Oral tinidazole

B. IV cefuroxime

**C. Oral vancomycin

D. IV metronidazole

Achalasia

A 34-year-old woman with progressive dysphagia diagnosed as a case of achalasia. She has no medical problem and not on any medications. She is clinically unremarkable (see lab results).

Test Result Normal Values
RBC 4 4.7-6.1 x 1012/L (Male)
4.2-5.4 x 1012/L (Female)
Hb 10 130-170 g/L (Male)
120-160 g/L (Female)
Platelets count 455 150-400 x 109/L
WBC 9 4.5-10.5 x 109/L
Urea 5 2.75-7.4 mmol/L
Creatinine 98 44-115 µmol/L

Which of the following is the best treatment option?

A. Fundoplication

**B. Pneumatic dilatation

C. Oral isosorbide dinitrate

D. Botulinum toxin injection

ENDOCRINOLOGY

A 35-year-old woman 9 weeks pregnant presented with a history of palpitations, heat intolerance and anxiety for several weeks, otherwise she feels well. Her only medication is a prenatal vitamin. On physical examination, she has warm and moist skin with fine tremor. There is no ophthalmology. Examination of the neck shows a diffusely enlarged thyroid with an audible bruit. Cardiopulmonary and abdominal examinations are unremarkable (see lab results).

Blood pressure 120/70 mmHg
Heart rate 115 /min
Respiratory rate 18 /min
Temperature 36.6 °C
Oxygen saturation 95 %
BMI 22 kg/m2

Test Result Normal Values
Thyroid-Stimulating Hormone < 0.01 0.4 - 5.0 µU/mL
Triiodothyronine (T3 free serum) 14 3.5 - 6.5 pmol/L
Thyroxine (T4 free serum) 35 8.5 - 15.2 pmol/L

Which of the following is the most appropriate treatment?

A. Observation

**B. Propylthiouracil

C. Radioactive iodine

D. Thyroidectomy

Cushing
Adrenal

A 60-year-old man came for follow-up evaluation of Cushing syndrome. He presented with new-onset diabetes mellitus and a 15.1-kg weight gain over the last 6 months. Medical history is otherwise unremarkable. He is currently taking no medications and has had no exposure to exogenous glucocorticoids in the past year. On physical examination, he has facial plethora, central obesity, and bilateral supraclavicular fat pads. There are purple abdominal striae measuring 1 cm wide and multiple ecchymoses on the extremities. Initial laboratory studies as following and a 24-hour urine free cortisol level was greater than 3 times the upper limit of normal (see lab results).

Blood pressure 165/92 mmHg
Heart rate 88 /min
Respiratory rate 15 /min
Temperature 36.9 °C
BMI 29 kg/m2

KEY FACT

Cushing syndrome: Too much cortisol.
Cushing disease: Too much cortisol from an ACTH-producing pituitary adenoma.

KEY FACT

In Cushing disease, cortisol secretion remains elevated with the low-dose (1 mg) dexamethasone test but is suppressed with the high-dose (8 mg) dexamethasone test.

Test Result Normal Values
ACTH < 1 2-11 pmol/L
Cortisol 8 a.m. 248 nmol/l post 138-635 nmol/L
1 mg overnight
dexamethasone
test

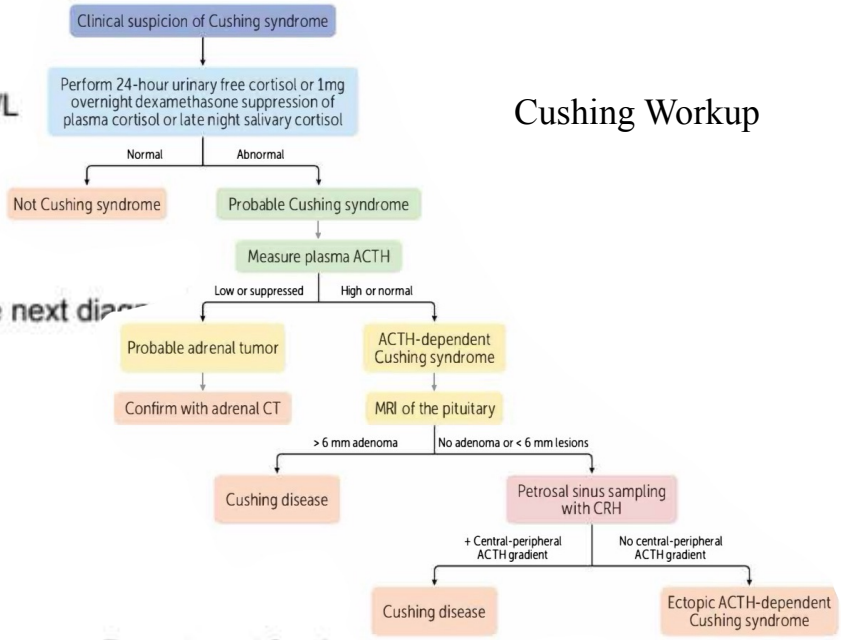
Clinical suspicion of Cushing syndrome
Perform 24-hour urinary free cortisol or 1mg overnight dexamethasone suppression of plasma cortisol or late night salivary cortisol
Normal
Abnormal
Not Cushing syndrome
Probable Cushing syndrome
Measure plasma ACTH
Low or suppressed
High or normal
Probable adrenal tumor
ACTH-dependent Cushing syndrome
Confirm with adrenal CT
MRI of the pituitary
> 6 mm adenoma
No adenoma or < 6 mm lesions
Cushing disease
Petrosal sinus sampling with CRH
+ Central-peripheral ACTH gradient
No central-peripheral ACTH gradient
Cushing disease
Ectopic ACTH-dependent Cushing syndrome

Cushing Workup

Which of the following is the most appropriate next dia

A. Inferior petrosal sinus sampling

B. Late night salivary cortisol level

**C. CT scan of the adrenal glands

D. MRI pituitary

Pituitary haemorrhage
Sheehan
Cortisone

A 33-year-old woman is evaluated in the Emergency Department for the sudden severe headache, vomiting and right eye vision loss she has had mild headaches that come and go over the past 2 years and for amenorrhea for the past 2 years. On physical examination, she has loss of vision in her right eye, other cranial nerves are intact. Strength and sensation in all extremities are normal, as are her speech and gait (see reports).

CT of the head:
Shows acute pituitary hemorrhage.

Pituitary MRI:
Shows a 4.1 x 2.5 x 3.2-cm pituitary mass compressing the optic chiasm and the right cavernous sinus with central haemorrhage.

Blood pressure 120/65 mmHg
Heart rate 99 /min
Respiratory rate 15 /min
Temperature 37 °C
BMI 25 kg/m2

Which of the following is the most appropriate immediate management in the Emergency Room?

**A. IV hydrocortisone

B. Assess pituitary function

C. Repeat imaging in 2 weeks

D. Urgent transsphenoidal pituitary decompression

Thyroid Nodule

6th June Exam DHA

A 39-year-old man found to have thyroid nodule during an annual physical examination. He has no personal or family history of any chronic medical disease, and he takes no medications. On physical examination, vital signs are normal. Palpation of the thyroid reveals left non-tender thyroid nodule, the remainder of the gland is unremarkable, and there is no palpable cervical lymphadenopathy. Other physical examination findings are normal (see lab results and report).

Test Result Normal Values

Thyroid-Stimulating Hormone 1.7 0.4 - 5.0 µU/mL
Thyroxine (T4 free serum) 13.5 8.5 - 15.2 pmol/L

When a patient has a nodule:

1. Perform thyroid function tests (TSH and T4).
2. If tests are normal, biopsy the gland.

Ultrasound of the neck:
Shows a left 3-cm hypoechoic nodule with internal microcalcifications.

Which of the following is the most appropriate next step in management?

**A. Fine-needle aspiration of the nodule

B. CT with contrast of the neck

C. Levothyroxine therapy

D. Thyroid scan

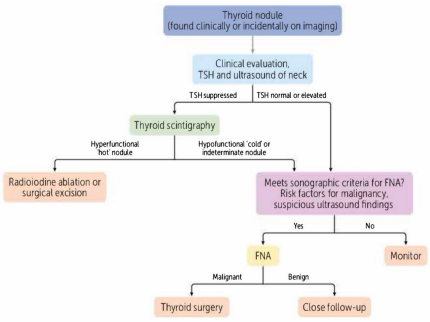

Thyroid Storm.
Thyrotoxicosis

A 29-year-old woman is evaluated for a 10-day history of severe neck pain with heat intolerance, palpitations, and insomnia. Medical history is significant only for a viral upper respiratory tract infection 4 weeks ago. She takes no medications. On physical examination, she appears anxious and she has sinus tachycardia. There is no proptosis or lid lag. Examination of the thyroid show a normal-sized tender gland. 24-Hour radioactive iodine 5% (low) uptake (see lab results).

Test Result Normal Values
Thyroid-Stimulating Hormone < 0.01 0.4 - 5.0 µU/mL
Triiodothyronine Reverse (RT3) 4.8 0.9 - 2.8 nmol/L
Thyroxine (T4 free serum) 34 8.5 - 15.2 pmol/L

TABLE 2.3-6. **Diagnoses Indicated by Radioactive Iodine Findings in Hyperthyroidism**

DIAGNOSIS	RADIOACTIVE IODINE (RAI) % UPTAKE	RAI SCAN FINDINGS	THYROGLOBULIN (LEVEL IN BLOOD)
Graves disease	↑	Diffuse uptake	N/A
Multinodular goiter	Normal/↑	Multiple nodules of ↑ uptake	N/A
Toxic adenoma	Normal/↑	One area of ↑ uptake	N/A
Thyroiditis, iodine exposure, extraglandular production	↓	Low uptake	↑
Exogenous thyroid hormone	↓	Low uptake	↓

Which of the following is the most appropriate treatment?

**A. Propranolol

B. Methimazole

C. Propylthiouracil

D. Radioactive iodine

- Acute hyperthyroidism and "thyroid storm"
  - Propranolol: blocks target organ effect, inhibits peripheral conversion of T4→T3
  - Thiourea drugs (methimazole [preferred] or PTU [preferred only in pregnancy]): block hormone production
  - Iodinated contrast material (iopanoic acid and ipodate): blocks the peripheral conversion of T4 to the more active T3; also blocks the release of existing hormone. Beta blockers must always be given before iodine replacement.
  - Steroids (hydrocortisone)
  - Radioactive iodine: ablates the gland for a permanent cure

A 70-year-old woman was admitted 1 week ago to the Intensive Care Unite with pneumonia requiring intubation, intravenous fluids, and dopamine support for her blood pressure. On physical examination, her skin is warm and dry, no proptosis, examination or the neck shows a normal-sized thyroid without nodules. Cardiovascular examination reveals regular tachycardia otherwise unremarkable systemic examination (see lab results).

Blood pressure 90/57 mmHg
Heart rate 120 /min
Respiratory rate 18 /min
Temperature 39 °C

Test Result Normal Values
Thyroid-Stimulating Hormone 0.1 0.4 - 5.0 µU/mL
Triiodothyronine (T3 free serum) 2 3.5 - 6.5 pmol/L
Thyroxine (T4 free serum) 11 8.5 - 15.2 pmol/L

Which of the following is the most likely cause of this patients abnormal thyroid function?

A. Grave's disease

B. Subacute thyroiditis

C. Hashimoto thyroiditis

**D. Euthyroid sick syndrome

Hashimoto Thyroid

A 49-year-old woman is evaluated because of fatigue and weight gain although she follows a daily diet control and exercises 3 times per week for 45 minutes. She has hypercholesterolemia requiring statin therapy. Her mother had hypothyroidism. On physical examination, she has dry skin, thyroid gland mildly enlarged with a diffusely nodular texture. Laboratory studies are with similar results for TSH and T4 were obtained 4 months ago (see lab results).

Blood pressure 143/93 mmHg
Heart rate 66 /min
BMI 29 kg/m2

When TSH is very high (more than double the upper limit of normal) with normal T4, replace hormone.
When TSH is less than double the normal, get antithyroid peroxidase/antithyroglobulin antibodies. If antibodies are positive, replace thyroid hormone.

High TSH (double normal) + Normal T4 = Treatment

Test Result Normal Values
Thyroid-Stimulating Hormone 7.0 0.4 - 5.0 µU/mL
Thyroxine (T4 free serum) 9.5 8.5 - 15.2 pmol/L
Thyroid peroxidase antibody (TPOAb) 150 <35 IU/mL

Antithyroid peroxidase antibodies tell who needs thyroid replacement when T4 is normal and TSH is high.

Which of the following is the most appropriate next step in management?

Hypothyroidism

Hashimoto thyroiditis Most common cause of hypothyroidism in iodine-sufficient regions; an autoimmune disorder with antithyroid peroxidase (antimicrosomal) and antithyroglobulin antibodies. Associated with HLA-DR3, HLA-DR5, ↑ risk of non-Hodgkin lymphoma (typically of B-cell origin).
May be hyperthyroid early in course due to thyrotoxicosis during follicular rupture.
Histology: Hürthle cells A, lymphoid aggregates with germinal centers.
Findings: moderately enlarged, **nontender** thyroid.

A. Thyroid ultrasound

**B. Start levothyroxine therapy

C. Repeat serum TSH measurement in 12 months

D. Schedule thyroid radioactive iodine uptake and scan

Primary Hyperparathyroid

A 29-year-old man is evaluated for a diagnosis of hypercalcemia. 5 days ago, he was treated of a kidney stone in the Emergency Department. Physical examination is unremarkable (see lab results).

Blood pressure 140/79 mmHg
Heart rate 85 /min
Respiratory rate 13 /min
BMI 30 kg/m2

Test Result Normal Values
Sodium 139 134-146 mmol/L

Potassium 4.0 3.5-5.1 mmol/L
Chloride 99 97-108 mmol/L
Bicarbonate 23 21-28 mmol/L
↑ Calcium 2.95 2.15-2.62 mmol/L
Phosphate, inorganic 0.76 0.82-1.51 mmol/L
↑ Parathyroid hormone (intact PTH levels) 200 1.1-5.3 pmol/L

Blood urea nitrogen 9.5 2.8 to 8.9 mmol/L
Creatinine 125 44-115 µmol/L

Which of the following is most likely cause for his hypercalcemia?

A. Milk alkali syndrome

**B. Primary hyperparathyroidism

C. Secondary hyperparathyroidism

D. Elevated 1,25-dihydroxyvitamin D levels

Cushing

A 35-year-old woman is evaluated for amenorrhea, weight gain, facial hair, alopecia, difficulty walking and easily bruising for the last 6 months. Her medical history is significant for psoriasis for which she is using clobetasol cream (topical steroid). On physical examination, vital signs all normal, she has round face, hirsutism, mild facial acne, central obesity, and a few wide purple striae on the back of her arms as well as her psoriatic skin lesions (see lab results).

Test Result Normal Values
Sodium 139 134-146 mmol/L
Potassium 3.5 3.5-5.1 mmol/L
Blood urea nitrogen 6.7 2.8 to 8.9 mmol/L
Creatinine 96 44-115 µmol/L
ACTH 1.4 2-11 pmol/L
Cortisol 8 a.m. 55 138-635 nmol/L

Which of the following is the most likely diagnosis?

A. Ectopic adrenocorticotropic hormone production

**B. Iatrogenic cushing syndrome

C. Adrenocortical carcinoma

D. Cushing syndrome

A 17-year-old man is evaluated in the Emergency Department for polyuria, polydipsia, polyphagia and an unintentional weight loss over the past month. He has abdominal pain and drowsiness for the last 12 hours. His medical and family history are unremarkable. He is not of any medications. On physical examination, he looks sick with dry mucous membrane, tachypnea, and tachycardia with clear chest auscultation. Abdominal examination shows diffuse mild tenderness with normal bowel sounds. Intravenous 0.9% saline is initiated. An electrocardiogram shows sinus tachycardia 120/min. Chest radiograph is normal (see lab results).

Blood pressure 95/53 mmHg
Heart rate 119 /min
Respiratory rate 20 /min
Temperature 37.2 °C
Oxygen saturation 95 %
BMI 19 kg/m2

Test Result Normal Values

Sodium 130 134-146 mmol/L
Potassium 4.4 3.5-5.1 mmol/L
Chloride 96 97-108 mmol/L
Bicarbonate 10 21-28 mmol/L
Blood urea nitrogen 15 2.8 to 8.9 mmol/L
Creatinine 115 44-115 µmol/L
Random Glucose 25 3.9-5.5 mmol/L
ABG HCO3- 10 22-28 mmol/L
pH 7.10 7.36-7.45
RBC 5 4.7-6.1 x 1012/L (Male)
4.2-5.4 x 1012/L (Female)
Hb 130 130-170 g/L (Male)
120-160 g/L (Female)
WBC 14 4.5-10.5 x 109/L

Which of the following is the most appropriate next step in the management?

A. Administer intravenous ceftriaxone

**B. Initiate intravenous insulin therapy

C. Administer intravenous potassium chloride

D. Administer intravenous sodium bicarbonate

A 45-year-old man is evaluated for recent onset type 2 diabetes mellitus and hypertension for the last 1 year. On physical examination, he has moon like face, dorsocervical fat pad and striae measuring 8 to 12 mm wide are noted on his upper arms and abdomen. Laboratory studies reveals the following as well as 24-Hour urine cortisol excretion which was 5 times upper the normal cut value and CT scan of the abdomen with and without contrast reveals a 5-cm right adrenal mass with contrast washout at 10 minutes is 60% (see lab results).

Blood pressure 162/93 mmHg
Heart rate 88 /min
Respiratory rate 14 /min
Temperature 36.8 °C
Oxygen saturation 96 %
BMI 30 kg/m2

Test Result Normal Values
ACTH 1.3 2-11 pmol/L
Cortisol 8 a.m. 1400 138-635 nmol/L

Which of the following is the most appropriate next step in the management?

A. Chemotherapy

**B. Surgical excision

C. Mitotane therapy

D. Radiation therapy

A 54-year-old man presents for follow-up evaluation after diagnosed with type 2 diabetes

mellitus 12 weeks ago. He was managed with lifestyle modifications and he come back with blood glucose log for the past 2 weeks. On physical examination, there is no evidence of diabetic retinopathy or peripheral neuropathy. Except for his blood glucose parameters, basic laboratory studies obtained at the time of her initial diagnosis were normal (see lab results).

Blood pressure 124/79 mmHg
Heart rate 84 /min
Respiratory rate 13 /min
Temperature 36.9 °C
Oxygen saturation 95 %
BMI 27 kg/m2

Initial test before lifestyle modifications: Test Result Normal Values
HbA1C 8.5% 4.7-5.6 %

Blood glucose log for the past 2 weeks: Test Result
preprandial blood glucose 150 to 160 mg/dL (8.3-8.9 mmol/L)
2-hour postprandial blood glucose 190 to 200 mg/dL (10.5-11.1 mmol/L)

In addition to lifestyle modifications, which of the following is the most appropriate initial management?

A. Dapagliflozin

**B. Metformin

C. Sitagliptin

D. Glipizide

DM
Hypoglycaemia

A 37-year-old man with type 1 diabetes mellitus presents to the office with history of prolonged hypoglycemia during intense exercise, despite eating a meal prior to the activity. He is using insulin glargine and insulin aspart with meals (see lab result).

Test Result Normal Value
HbA1C 7.0 4.7-5.6 %

Which of the following is the most appropriate management of this patient's hypoglycemia on the days that he exercises?

**A. Decrease meal-time insulin aspart dose prior to exercise, continue insulin glargine dose

B. Increase meal-time protein prior to exercise, continue current insulin doses

C. Switch insulin aspart to a sliding-scale regimen, continue insulin glargine dose

D. Discontinue insulin glargine, continue insulin aspart dose

A 60-year-old man is evaluated because of fatigue, constipation and cold intolerance for the last 8 months. Medical history is significant for Hodgkin lymphoma treated with radiation therapy 3 years ago and there is no family history of thyroid disorders. On physical examination, he has dry skin with mild periorbital edema and normal thyroid exam (see lab results).

Test Result Normal Values
Hb 120 130-170 g/L (Male)
120-160 g/L (Female)
Sodium 129 134-146 mmol/L
Thyroid-Stimulating Hormone 5.0 0.4 - 5.0 µU/mL

Which of the following will establish diagnosis of hypothyroidism?

A. Repeat TSH measurement in 4 weeks

**B. Free thyroxine (T4) measurement

C. Thyroid ultrasound

D. Thyroid scan

Adrenalectomy
Hydrocortisone

A 30-year-old woman is admitted to the hospital for an elective adrenalectomy for non-ACTH dependent Cushing syndrome confirmed by a contrast-enhanced adrenal CT scan finding of benign right adrenal adenoma.

Which of the following is the most appropriate perioperative management?

A. Postoperative mitotane

**B. Perioperative hydrocortisone

C. Postoperative fludrocortisone

D. Preoperative phenoxybenzamine

Give alpha blocker Phenoxybenzamine before operating on Pheocromocytoma

Hypothyroidism
Pregnant

A 36-year-old woman is evaluated during her first prenatal visit for Medical history of hypothyroidism, for which she has taken levothyroxine 125 g/d, for the last 2 years. On physical examination, no goiter or cervical lymphadenopathy. Cardiovascular, pulmonary and abdominal examinations are unremarkable (see lab results).

Blood pressure 100/73 mmHg
Heart rate 87 /min
Respiratory rate 13 /min
Temperature 36.5 °C
Oxygen saturation 97 %
BMI 23 kg/m2

Test Result Normal Values
Thyroid-Stimulating Hormone 4.4 0.4 - 5.0 µU/mL } controlled
Thyroxine (T4 free serum) 9.5 8.5 - 15.2 pmol/L

Which of the following is the most appropriate treatment of this patient's hypothyroidism now?

**A. Increase levothyroxine dose

B. Continue levothyroxine dose

C. Decrease levothyroxine dose

D. Discontinue levothyroxine dose

Chest pain

A 59-year-old man is admitted to the hospital for evaluation of chest pain. His medical history is significant for type 2 diabetes mellitus, coronary artery disease, hypertension, and hyperlipidemia. He manages his diabetes as an outpatient with diet, exercise, and metformin. His other medications are aspirin, metoprolol, atorvastatin, and sublingual nitroglycerin as needed (see lab results).

Sliding scale DM

Test Result Normal Values
HbA1C 8.5 4.7-5.6 %
Plasma Glucose 9.4-14.9 mmol/L

Which of the following is the most appropriate diabetes treatment for this patient while hospitalized?

A. Glipizide

B. Metformin

C. Sliding-scale insulin

**D. Basal and prandial insulin

PCOS
irregular menses
Hirsutism
OCP

A 23-year-old woman is evaluated after a recent diagnosis of polycystic ovary syndrome. She is concerned about hirsutism and irregular menses. She is not planning for pregnancy at this time and takes no medications. On physical examination, she has mild hirsutism and the remaining of her physical examination, including pelvic examination, are normal.

Blood pressure 120/70 mmHg
Heart rate 76 /min
Respiratory rate 15 /min
Temperature 36.7 °C
BMI 36 kg/m2

...
woman in her 30s with irregular cycles and anovulatory cycles since several years endometrial biopsy was done and showed atypical hyperplasia what is the best treatment? A. oral progestin B. Tamoxifen Endometrial Hyperplasia with atypia is treated with progestine if women want to to conceive.
....

Which of the following is the most appropriate treatment?

A. Metformin

B. Spironolactone therapy

**C. Combined oral contraceptive pills

D. Levonorgestrel intrauterine system

Irregular menstruation is a problem in PCOS because a woman's uterine lining must be shed regularly; otherwise, there may be conversion to uterine hyperplasia (premalignant). Treatment is OCPs containing progesterone to regulate menstruation.

Neuropathy
Diabets

A 61-year-old man with a 20-year history of type 2 diabetes mellitus is evaluated for bilateral burning sensation in his feet for the last 8 months, which worsens at night. His haemoglobin A1c levels have remained less than 7.0% for the last 1 years but were between 9.0% and 10.0% before adding insulin therapy to metformin 1 years ago. His medical history includes coronary artery disease, non-proliferative diabetic retinopathy, hypertension, and hyperlipidemia. Medications are aspart insulin, glargine, aspirin, metoprolol, atorvastatin, and lisinopril. On physical examination, findings are compatible with distal symmetrical polyneuropathy.

Which of the following is the most appropriate management of this patient's neuropathy?

**A. Amitriptyline

Diabetic Neuropathy

1st line: Amytriptyline or Pregabalin
→ Imipramine if Orthostatic Hypotension
2nd line: Amy + Pregabalin

B. Physiotherapy

C. Tight blood sugar control

D. Vitamin B12 supplements

Galactorrhoea
Hypothyroidism
Prolactin

A 34-year-old woman is evaluated for history of galactorrhea, worsening fatigue, malaise and irregular excessive menses for the last 5 months. She complains of headaches that occur about 2 to 3 times per week. Her physical examination is unremarkable. Pregnancy test was negative (see lab results).

Blood pressure 120/86 mmHg
Heart rate 62 /min
Respiratory rate 13 /min
BMI 28 kg/m2

TRH
TSH Prolactin

Test Result Normal Values
↑ Thyroid-Stimulating Hormone 16 0.4 - 5.0 µU/mL
Thyroxine (T4 free serum) 9.2 8.5 - 15.2 pmol/L
Prolactin 1000 < 652 pmol/L (Male)
< 870 pmol/L (Female)
Human chorionic gonadotropin 0.0 < 5 mIU/mL

HYPOTHYROIDISM
↓
↑ Prolactin

Which of the following is the most appropriate management?

A. Begin cabergoline

**B. Begin levothyroxine

C. Order pituitary MRI

D. Observation and retest thyroid function test in 6 months

DM Type 1
Hypoglycemia
Glargine
Aspart

A 19-year-old woman is evaluated for management of type 1 diabetes. She was diagnosed 4 months ago after presenting to the Emergency Department with diabetic ketoacidosis. Her hemoglobin A1c level at the time of diagnosis was 14.5%. She was discharged from the hospital on a basal and prandial insulin regimen with minor adjustments required as an outpatient. Recently she started to have episodes of both fasting and postprandial hypoglycemia. Medications are insulin glargine and insulin aspart. Her systemic examinations are unremarkable (see lab results).

Blood pressure 115/77 mmHg
Heart rate 80 /min
BMI 22 kg/m2

Test Result Normal Values
HbA1C 6.0 4.7-5.6 %
Random Glucose 4.5 3.9-5.5 mmol/L

Which of the following is the most appropriate management for her hypoglycemia?

**A. Decrease insulin glargine, decrease insulin aspart

B. Continue same doses of insulin glargine and aspart

C. Discontinue insulin glargine, discontinue insulin aspart

D. Discontinue insulin glargine, change insulin aspart to a sliding-scale regimen

Prolactin

A 44-year-old man is evaluated for an 8-month history of decreased libido and severe erectile dysfunction, including absence of morning erections. He and his wife would like to conceive. His medical history is otherwise unremarkable, and he takes no medications. On physical examination, vital signs are normal with unremarkable clinical examination (see lab results and report).

Test Result Normal Values
Thyroid-Stimulating Hormone 2.5 0.4 - 5.0 µU/mL
Follicle-stimulating hormone 1.2 5-20 IU/L (Follicular phase)
15-35 IU/L (Mid cycle peak)
5-15 IU/L (Luteal phase)
50-100 IU/L (Postmenopausal women)
5-20 IU/L (men)
Testosterone 4.2 10.4-41.6 nmol/L (Male)
0.7-2.8 nmol/L (Female)
Luteinizing hormone 1.0 3-15 U/L (Male)
5-22 U/L (Follicular phase)
5-22 U/L (Luteal phase)
30-250 U/L (ovulatory phase)
> 30 U/L (Postmenopausal)
Prolactin 1500 < 652 pmol/L (Male)
< 870 pmol/L (Female)

Prolactin inhibits FSH, LH

MRI of the pituitary:
Reveals a 0.8-cm anterior pituitary mass consistent with an adenoma.

Which of the following is the most appropriate treatment?

A. Testosterone replacement therapy

B. Clomiphene citrate

**C. Cabergoline

D. Sildenafil

Sick Euthyroid syndrome

A 79-year-old man was admitted to the Intensive Care Unit with features of septicaemia due to severe urinary tract infection. His blood tests showed thyroid dysfunction that was attributed to a non-thyroidal illness or sick euthyroid state.

Which one of the following is the common typical pattern of thyroid dysfunction seen in a sick euthyroid illness?

A. Elevated levels of T3 and T4; low levels of reverse T3

B. Elevated levels of T3, T4, and reverse T3

**C. Low levels of T3 and T4; elevated levels of reverse T3

↓ Reverse T_3 in Euthyroid Sick Synd.

Euthyroid sick syndrome	Normal/↓ TSH	Normal/↓ T4	↓ T3	Caused by any serious illness; will have ↑ reverse T_3 (nonfunctional), as T_4 is converted to rT_3 instead of T_3; thought to be protective (avoids excess catabolism in acute illness); thyroid hormone supplementation is not indicated.

D. Low levels of T3 and T4; normal level of reverse T3

Graves opthalmology

A 24-year-old man presented to thyroid clinic with a 5-month history of feeling unwell, weight loss, anxiety, and panic attacks. He also complained of redness and grittiness of eyes, with painful eye movements. On examination, he had bilateral tremors, proptosis, and lid retraction.

Which one of the following factors is associated with increased risk for the development of severe Grave's orbitopathy?

A. No response to thionamides

B. Free T4 and T3 levels

C. Male sex

**D. Smoking

A 39-year-old man incidentally found to have a 2-cm left adrenal gland mass while she underwent CT of the abdomen to investigate the cause of her pelvic pain.

Which one of the following is the most common cause of an incidentally detected adrenal mass?

A. Sub-clinical cushing's disease

B. Adrenocortical carcinoma

**C. Non-functional adenoma

D. Conn's syndrome

Favoring Benign Status	Suspicious for Malignancy
• Size <4 cm • Low density (<10 Hounsfield units) • High/rapid contrast washout	• Size >4 cm • High density (>10 Hounsfield units) • Low/slow contrast washout • Rapid rate of growth (>1 cm/year)

Features of Incidental Adrenal Masses

A 40-year-old woman was incidentally detected to have a 13-mm pituitary macro-adenoma on a CT of the head arranged to evaluate cause for her recurrent headaches. Apart from the headaches that she had suffered for the last 8 months, she had no history of any significant medical illness and was not on any regular medications. Her general physical and systemic examination was unremarkable.

Which of the following is the most appropriate next step in her management?

**A. Anterior pituitary hormone profile

B. Discharge from follow-up

C. Neurosurgical referral

D. Insulin tolerance test

Hyperpigmentation ACTH

A 25-year-old woman complains of dizziness and feeling light-headed. She is a teacher and most frequently experiences this when she stand up in the class. She has never fainted. She lost 5 kg, but attributes this to eating healthy food. She has noticed a recent scar on the back of her hand, which has started to turn very dark as well as generalized skin hyperpigmentation.

What is the most appropriate investigation to confirm the diagnosis?

**A. Synacthen test (ACTH stimulation test)

B. Abdominal ultrasound (US) scan

C. Low-dose dexamethasone test

D. Am cortisol measurement

Dipeptidyl peptidase inhibitors 4 (DPP4) are novel oral hypoglycaemic agents that inhibit the enzyme DPP4 and prevent breakdown of endogenous incretins, which will improve blood sugar control in patients with diabetes mellitus type 2.

Which of the following DPP4 inhibitor does not require any dose modification in renal disease?

A. Vildagliptin

Lina is the best drug.

**B. Linagliptin

C. Saxagliptin

D. Sitagliptin

A 50-year-old woman recently diagnosed with papillary thyroid carcinoma.

Counselling

Which of the following is an example of positive communication skill while explaining the management option of her disease?

A. Forgetting to say thank you

**B. Ask a patient to repeat your instructions

C. Interrupt a patient when she ask questions

D. Inform patients when you cannot spend any more time with them

A 30-year-old woman recently diagnosed with Cushing's syndrome.

Which of the following will be considered as negative communication skill while explaining for her the course of her disease?

A. Speaking slowly with clear language

B. Looking directly at a patient when speaking

**C. Interrupt a patient when he/she does not understand

D. Encouraging the patient to ask questions

At which estimated GFR level, metformin should be stopped in diabetic patients?

A. GFR between 45-60

B. GFR between 30-45

**C. GFR less than 30

D. GFR less than 15

METFORMIN — First line
* inhibits Gluconeogenesis
* doesn't cause weight gain
=> metformin accumulate ^ cause METABOLIC ACIDOSIS in Renal Dysfunction.

Which of the following osteoporosis treatment has FDA approval to treat malignancy induced hypercalcemia?

**A. Denosumab → Monoclonal Antibody to RANK-L

B. Alendronate

C. Ibandronate

D. Recombinant human 1-34 PTH (teriparatide)

Gestational DM
Sulfonylureas
Glyburide

A 35-year-old pregnant woman with gestational age of 30-weeks comes for a follow-up. She was diagnosed to have gestational diabetes mellitus (GDM) at week 24, she was maintained on diet control but unfortunately her blood sugar reading between (150-200 mg/dl). The physician decided to start insulin but she is totally refusing injections and she asks about any safe oral medication to be used in pregnancy.

Which of the following oral hypoglycemic agents has safety data and recommended to be used in pregnancy?

Sulfonylureas (glipizide, glyburide, glimepiride)	↑ endogenous insulin secretion	Hypoglycemia and weight gain—avoid use in older patients

A. Glipizide

B. Sitagliptin

**C. Glyburide

D. Rosiglitazone

Exercise

A 44-year-old man with a strong family history of type 2 diabetes and cardiovascular disease was recently diagnosed with pre-diabetes. He came for advice regarding healthy eating patterns and physical activity that will help him to prevent type 2 diabetes (see lab result).

BMI 31 kg/m2

Test Result Normal Values
HbA1C 6.1 4.7-5.6 %

In helping this individual to achieve and maintain his target weight loss, which of the following is the best advice?

A. Reducing caloric intake

B. Exercising 30 minutes per day on 5 days per week

C. Diet low in protein and relatively higher in carbohydrates

**D. Exercise for at least 30 minutes most days of the week and low carbohydrate diet

GDM

A 29-year-old woman comes to the clinic for a follow-up. She is diagnosed with gestational diabetes mellitus (GDM) at week 24. She is asking for an advice regarding the best dietary habits she can follow to control her blood sugar and avoid insulin injection.

Which of the following is the best diet option?

A. Low fat diet

B. Mediterranean diet

**C. Low glycemic index diet

D. Energy restriction is not recommended during pregnancy

Low fat diet
Prediabetes

A 62-year-old woman receives a diagnosis of prediabetes based on routine lab work showing mildly elevated glycated hemoglobin (HbA1c). She has had obesity for many years. She eats a diet rich in processed foods. She rarely exercises. Physical exam reveals mildly elevated blood pressure along with trace acanthosis nigricans at the nape of the neck.

Blood Pressure 145/87 mmHg
BMI 30 kg/m2

What advice should be given to reduce her risk of developing diabetes, in addition to increasing her physical activity to >150 minutes per week?

A. Low glycemic index diet to produce 5-10 % weight loss

**B. Low fat diet to produce 5-10 % weight loss

C. Diet is less effective than metformin to reduce the risk of diabetes

D. Low carbohydrate diets are more likely than low fat diets to prevent diabetes in the long-term

Referral

A 40-year-old man comes to the clinic for evaluation and management of obesity. His obesity is complicated by type 2 diabetes mellitus (T2DM), hypertension, sleep apnea, dyslipidemia, chronic low back pain, osteoarthritis of the knees, and depression. He was prescribed medications for these problems but that he is not compliant to treatments. His wife accompanied him to the visit was anxious about his health and she want the doctor to council him for the best solutions he can do.

BMI 55 kg/m2

Which of the following is the most appropriate advice will help in treating this patient?

A. Emphasizing the importance of adherence to his medications

B. Referral to an orthopedic surgeon for knee arthroplasties

C. Addition of pharmacotherapy for obesity

**D. Referral for bariatric surgery

A 39-year-old woman with type 1 diabetes for 20 years was married recently; she and her husband want to get pregnant. The woman has hypertension treated with an angiotensin converting enzyme (ACE) inhibitor and a diuretic with maintenance of blood pressure at 118/80 mmHg. Her insulin doses are all administered through a continuous insulin infusion pump using insulin aspart. She reported that she would try to become pregnant next month (see lab results).

Test Result Normal Values
24 hr urine protein
2000 0.8-14 mg/dl (Male)
2.5-11 mg/dl (Female)
Creatinine 88 44-115 µmol/L
HbA1C 8.0 4.7-5.6 %

What is the best advice at this moment to control her blood sugar and prevent congenital malformation?

A. Eliminate snacks and begin to take 3 heavy meals daily

B. Substitute an angiotensin receptor blocker for her ACE inhibitor

C. Her age and risk factors indicate the need to begin taking a statin at this time

**D. Delay conception until her HbA1c is as close to normal as possible, if this can be safely achieved

Counselling

A 25-year-old woman pregnant at 15 weeks presents to the clinic complaining of palpitation, tremor and diarrhoea for the last 3 weeks. On examination, she looks anxious, she has graves ophthalmopathy and goiter. Other systemic examination are unremarkable. Diagnosis of grave's disease was confirmed but she is refusing to start any treatment while she is pregnant (see lab results).

Blood pressure 110/65 mmHg
Heart rate 125 /min
Respiratory rate 18 /min
Temperature 37.6 °C
BMI 20 kg/m2

Test Result Normal Values
Thyroid-Stimulating Hormone < 0.01 0.4 - 5.0 µU/mL
Triiodothyronine (T3 free serum) 10.0 3.5 - 6.5 pmol/L
Thyroxine (T4 free serum) 35.0 8.5 - 15.2 pmol/L

Which of the following is the most appropriate action?

A. Agree with her opinion and discharge her from the clinic

B. Call her husband and force her to start the treatment

C. Give her follow up after 2 months and repeat her thyroid function test

**D. Explain clearly the risk for her and the fetus and try to convince her to start the treatment immediately

Ethics
Counselling

A 45-year-old man presented to the clinic with large thyroid nodule otherwise asymptomatic, that was proven to be papillary thyroid carcinoma. The physician is planning to send him for total thyroidectomy but the patient is afraid from the surgical complication. The treating physician needs to create a lasting impression at the end of the consultation.

Which of the following is the most appropriate action?

**A. Avoid answering all patient's questions

B. Patient's agreement for referral is not required

C. Avoid discussing the serious surgical complications

Corrected

D. Briefly explain the action plan with possible expected and unexpected outcome

A 22-year-old man developed traumatic paraplegia secondary to a road traffic accident about 8 months ago, requiring prolonged immobilization. His general physical and systemic examination were unremarkable and intact PTH levels (see lab results).

Test Result Normal Values
Calcium 2.75 2.15-2.62 mmol/L
Phosphate, inorganic 0.9 0.82-1.51 mmol/L
Parathyroid hormone 1.0 1.1-5.3 pmol/L

Which of the following is the most probable underlying aetiology for his hypercalcaemia?

A. Malignancy

**B. Immobilization

C. Multiple myeloma

D. Primary hyperparathyroidism

A 40-year-old man was referred to the endocrine clinic with symptoms of reduced libido and lack of energy for the last 10 months. On examination, he had normal general physical and systemic examination (see lab results and report).

BMI 40 kg/m2

Test Result Normal Values
Thyroid-Stimulating Hormone 0.3 0.4 - 5.0 µU/mL
Thyroxine (T4 free serum) 7.5 8.5 - 15.2 pmol/L
Follicle-stimulating hormone 2.5 5-20 IU/L (Follicular phase)
15-35 IU/L (Mid cycle peak)
5-15 IU/L (Luteal phase)
50-100 IU/L (Postmenopausal women)
5-20 IU/L (men)
Testosterone 8.0 10.4-41.6 nmol/L (Male)
0.7-2.8 nmol/L (Female)
Luteinizing hormone 1.3 3-15 U/L (Male)
5-22 U/L (Follicular phase)
5-22 U/L (Luteal phase)
30-250 U/L (ovulatory phase)
> 30 U/L (Postmenopausal)
Prolactin 450 < 652 pmol/L (Male)
< 870 pmol/L (Female)

MRI brain:
Showed 2.5 cm pituitary adenoma.

Which of the following is the most likely diagnosis?

A. Morbid obesity

B. Macroprolactinoma

C. Primary hypothyroidism

**D. Non-functioning pituitary adenoma

MRI pituitary

An 18-year-old boy was referred to the Endocrine Clinic with features of short height and weight gain. On examination, he had increased BMI and central adiposity together with purple striae on lower abdomen (see lab results).

Test Result Normal Values
ACTH 20 2-11 pmol/L
Cortisol 8 a.m. 600 138-635 nmol/L
Cortisol 4 p.m. 550 83-441 nmol/L
Cortisol 1 hr after cosyntropin > 500 > 498 nmol/L

Which of the following is the most appropriate next step in his management?

A. Bilateral inferior petrosal sinus sampling

B. CT abdomen and thorax

**C. MRI of the pituitary

D. Octreotide scan

A 25-year-old man was referred to the Endocrine Clinic with a recent history of fragility fracture. He had no significant past medical history and was on no medication. On examination, he had sparse facial and axillary hair growth. His systemic examination was unremarkable.

BMI 23 kg/m2

Which of the following investigations useful in establishing the aetiology of his fragility fractures?

A. Calcitonin level

B. DEXA bone densitometry scan

C. Insulin like growth factor (IGF1)

**D. Testosterone and gonadotrophin levels ← LH, FSH, Testosterone

Adrenal adenoma

A 40-year-old man was incidentally detected to have a benign 2.0-cm right adrenal adenoma on CT of the abdomen, which was done to evaluate his symptom of abdominal pain. On examination, he had unremarkable general physical and systemic examination.

Blood pressure 130/70 mmHg
BMI 26 kg/m2

Which of the following is the most appropriate next step in management?

A. MIBG scan

B. MRI adrenals

C. Surgical referral

↓ check Metanephrine levels to rule out Pheochromocytoma

Rx: α blockers (phenoxybenzamine)

**D. Dexamethasone suppression test (overnight) and urinary metanephrines

A 35-year-old man was found to have a 5.5-cm left adrenal mass with irregular borders and a density of >10 HU on non-contrast CT of the abdomen. On contrast-enhanced CT of the abdomen, there is <30% contrast wash out at 15 minutes. In view of the suspicious radiological features of the mass, the patient was referred to the endocrine surgical team for an elective adrenalectomy.

Which of the following investigations should be done prior to an elective adrenalectomy?

**A. 24-hour urinary fractionated metanephrines → to role out Pheochromocytoma as you need to give α - blockers pre-operatively.

B. Aldosterone to plasma renin activity ratio

C. Fine needle aspiration cytology

D. PET scan

A 30-year-old woman presents with recurrent attacks of dyspnea and cough when exposed to dust and perfumes. Physical examination is normal except for mild expiratory wheeze on lung auscultation (see report).

RESPIRATORY

Spirometry:
Reversible bronchospasm.

Which of the following is most appropriate to initiate at this stage?

A. Inhaled tiotropium

**B. Inhaled salbutamol Short acting beta agonist

C. Inhaled budesonide

D. Montelukast

A 60-year-old man with a history of 20-pack-year smoking presents with exertional dyspnea and productive cough for 3 months. He had similar attack last year. On examination, he has central cyanosis and expiratory wheeze on lung auscultation (see lab results)

Test Result Normal Values
ABG HCO3- 36 22-28 mmol/L
ABG PCO2 7.7 4.7-6.0 kPa
pH 7.35 7.36-7.45
ABG PO2 8.4 10.6-14.2 kPa

Which of the following is the most likely diagnosis?

A. Bronchial asthma

**B. Chronic bronchitis

C. Pulmonary embolism

D. Interstitial pulmonary fibrosis

A 70-year-old man heavy smoker, presents with left sided chest pain and hemoptysis for 2 days. Recently his son has noticed change in the quality of his father's voice. On examination, he has early digital clubbing and both of his wrists are painful and tender.

Blood pressure 110/70 mmHg
Heart rate 85 /min
Respiratory rate 22 /min
Temperature 36.6 °C
Oxygen saturation 92 %

Which of the following is the most likely diagnosis?

A. Tuberculosis

B. Bronchiectasis

C. Pulmonary embolism

**D. Bronchogenic carcinoma

In a patient with acute asthmatic attack, which of the following is the most recommended tool to assess the response to therapy?

A. Chest radiography

B. Arterial blood gas

C. Pulsus paradoxus

**D. Peak flow meter

Effusion

A 65-year-old smoker is being evaluated for pleural effusion. He has cough, dyspnea and hemoptysis. On examination, signs of massive pleural effusion are present on right side but the trachea and apex beat are not shifted.

Which of the following explains these clinical findings?

A. Heart failure

B. Tubercular pleural effusion

C. Effusion due to esophageal rupture

**D. Carcinoma, obstructing ipsilateral main bronchus

TB Drugs
Side effects

6th June Exam DHA

A 45-year-old man is diagnosed to have pulmonary tuberculosis for which he was started on 4 anti-tuberculous drugs 2 months ago. During routine follow up, his blood work shows hyperuricemia (see lab result).

Test Result Normal Values
Uric acid 600 200-410 µmol/L (Male)
140-360 µmol/L (Female)

What anti-TB drug is responsible for this finding?

A. Isoniazid

B. Rifampicin

C. Ethambutol

**D. Pyrazinamide

TB Meds Side Effects

Drug	Toxicity	Management
Rifampin	Red color to body secretions	None, benign finding
Isoniazid	Peripheral neuropathy	Use pyridoxine to prevent / Bc
Pyrazinamide	Hyperuricemia	No treatment unless symptomatic
Ethambutol	Optic neuritis/color vision	Decrease dose in renal failure

A 32-year-old man is seen in the clinic for evaluation of primary infertility. Past medical history is significant for recurrent sinusitis. Sperm analysis shows normal number of sperms, but they are immotile (see report).

Chest radiography:
shows situs inversus.

Which of the following is the most likely diagnosis?

A. Cystic fibrosis

**B. Kartagener's syndrome (A/R)

C. Wegner's granulomatosis

D. Good pasture's syndrome

A 40-year-old man presents to the Emergency Department complaining of progressive dyspnea over 5 days. Past medical history is significant for road traffic accident 2 week ago. Lung auscultation revealed absent breath sounds in the right side (see image and lab results).

Blood pressure 100/70 mmHg
Heart rate 90 /min
Respiratory rate 24 /min
Temperature 36.6 °C
Oxygen saturation 90 %

Test Result Normal Values
Hb 90 130-170 g/L (Male)
120-160 g/L (Female)
WBC 6 4.5-10.5 x 109/L

Which of the following is the most appropriate management?

A. Antibiotics

B. Anticoagulation

**C. Chest tube insertion

D. Salbutamol nebulizer

Schistosomiasis
Pulmonary HTN
Parasternal heave

A male farmer with chronic liver disease secondary to repeated infections of schistosoma mansoni complains of progressive dyspnea. Examination revealed elevated JVP, clear lung fields and left parasternal heave.

What is the likely complication that has occurred?

A. Bronchiectasis

B. Pulmonary embolism

C. Constrictive pericarditis

**D. Pulmonary hypertension

A 45-year-old man presents with 5-year history of cough, productive of large volume of sputum associated with dyspnea and hemoptysis. On examination, he has clubbing and course crackles in the right base.

Which of the following tests has the highest diagnostic value?

A. X-ray chest

B. Bronchoscopy

**C. High resolution CT chest

D. Pulmonary function tests

A 50-year-old woman with pulmonary hypertension is being evaluated for a possibility of chronic thromboembolic disease.

Which of the following investigations has the highest diagnostic value?

A. Echocardiogram

B. Electrocardiography

C. Spiral CT chest with contrast

**D. Ventilation-perfusion lung scan

Which of the following drugs is a leukotriene receptor antagonist?

A. Infliximab

B. Tenofovir

**C. Montelukast

D. Voriconazole

Pulmonary HTN

According to the World Health Organization classification of pulmonary hypertension, which of the following conditions falls under group 3?

A. Portal hypertension

B. Left ventricular failure

C. Chronic thromboembolic disease

**D. Lung fibrosis with chronic hypoxemia

Pulmonary Hypertension

PULMONARY HYPERTENSION/COR PULMONALE

- **Pulmonary hypertension (PH):** Elevated mean pulmonary arterial pressure (>20 mm Hg) at rest
- Classified into the following groups:
  - Group 1: Pulmonary arterial hypertension (PAH)
  - Group 2: ↑ pulmonary venous pressure from left-sided heart disease
  - Group 3: Hypoxic vasoconstriction secondary to chronic lung disease
  - Group 4: Chronic thromboembolic disease
  - Group 5: Pulmonary hypertension with a multifactorial etiology
- **Core pulmonale (group 3):** Alteration in structure and function of the right ventricle (RV) of the heart caused by a primary disorder of the respiratory system. Right-sided heart failure can occur in severe cases.

Small cell carcinoma

A 55-year-old man presents with progressive dyspnea and cough for 6 weeks. He is a heavy smoker. 2 weeks ago, he started having headaches and noticed swelling of his face. Physical examination reveals prominent non-pulsating neck veins, puffiness of the face and edema of the upper limbs (see report).

Chest X-ray:
Shows a prominence of the right hilum.

Which of the following types of lung cancer is the most commonly associated with this clinical presentation?

A. Adenocarcinoma of the lung

B. Carcinoid tumor of the lung

C. Squamous cell lung cancer

**D. Small cell lung cancer

- ***Hx*:** COPD, ILD, heart disease, sickle cell anemia, emphysema, and pulmonary embolism
- ***PE*:** Loud, palpable S_2 (often split), a flow murmur, an S_4, or a parasternal heave; patient may also be hypoxemic, especially on exertion

Diagnosis

- Best **initial test:** Echocardiogram that estimates pulmonary artery (PA) pressure and assesses RV function
- **CXR:** Shows enlargement of central pulmonary arteries with rapid tapering of the distal vessels (pruning)
- **ECG:** Demonstrates right ventricular hypertrophy (RVH)
- **Diagnostic test of choice:** Right heart catheterization; mean pulmonary artery pressure >20 mm Hg (normal: 8–20 mm Hg)

An asymptomatic 60-year-old man, non-smoker presents for a routine annual physical check-up. A chest X-ray showed an opacity, which is less than 3 cm in the left upper lobe.

Which of the following is the next best step in the management?

A. Surgical resection

**B. Review old chest X-ray

C. CT chest with IV contrast

D. CT-guided transthoracic needle biopsy

Pneumothorax

A 55-year old man with stable COPD, presents with sudden onset left-sided pleuritic chest pain and exertional dyspnea. On examination, he is not in distress, the trachea is central and breath sounds are equal in both sides with occasional mild expiratory wheezes (see report).

Blood pressure 130/70 mmHg
Heart rate 80 /min
Respiratory rate 22 /min
Temperature 36.6 °C
Oxygen saturation 93 %

Chest X-ray:
Shows a left sided pneumothorax measuring 2 cm between the lung and chest wall.

Which of the following is the most appropriate next step in management?

A. Needle aspiration

B. Chest tube insertion

C. Perform pleurodesis

**D. Oxygenation and observation

Pneumothorax

Collection of air in the pleural space that can lead to pulmonary collapse. Etiologies are the following:

- **Primary spontaneous pneumothorax:** Due to rupture of subpleural apical blebs (usually found in tall, thin, young males).
- **Secondary pneumothorax:** Due to COPD, trauma, infections (TB, *P jirovecii*), and iatrogenic factors (thoracentesis, subclavian line placement, positive-pressure mechanical ventilation, bronchoscopy with biopsy).
- **Tension pneumothorax:** A pulmonary or chest wall defect acts as a one-way valve, causing air trapping in the pleural space. Buildup of air pushes the mediastinum to the opposite side of the chest, which can obstruct venous return to the heart, leading to hemodynamic instability and even cardiac arrest unless immediately treated.

Treatment

- Tension **pneumothorax:** Requires immediate needle decompression (second intercostal space at the midclavicular line) followed by chest tube placement.
- **Small pneumothorax (≤2 cm):** Observation ± supplemental O_2. It may resorb spontaneously.
- **Large (>3 cm), symptomatic pneumothorax:** Needle aspiration or small-bore chest tube placement.
- **Patients who are unstable or who have recurrent pneumothorax:** Chest tube placement.

Erythematous Nodule

A 20-year-old woman presents to the Out-Patient Department with mild dyspnea, malaise, low-

grade fever and arthralgia. Physical examination showed tender erythematous nodules measuring 2-3 cm in both shins. Chest auscultation revealed fine basal crackles.

Which of the following is the next best action in management?

A. Blood culture

B. Oral steroids

**C. Chest X-ray

D. Skin biopsy

Which of the following is the best oxygen delivery system in a patient with Chronic Obstructive Pulmonary Disease?

A. Simple face mask

B. Rebreathing bag

C. Nasal cannula

**D. Venturi mask

COPD

A 65-year-old man known to have COPD presented to the Emergency Department with increasing dyspnea, cough, expectoration and fever. Initial assessment revealed fully conscious patient with mild distress, central cyanosis and bilateral wheezing on chest auscultation. The patient was started on high flow oxygen and salbutamol nebulizer but 1 hour later, his level of consciousness is reduced (see lab result)

Test Result Normal Values
ABG HCO3- 36 22-28 mmol/L
ABG PCO2 9 4.7-6.0 kPa
pH 7.18 7.36-7.45
ABG PO2 15 10.6-14.2 kPa

pO_2 = 75 – 100 mmHg
10·5 – 13·5 kPa

15 kpa = 112 mmHg

Improves Survival : O_2 therapy
Improves Mortality & delays progression of COPD
Smoking cessation

Which of the following is the best initial step in management?

A. Start mechanical ventilation

**B. Reduce oxygen flow

C. Order brain CT scan

D. Give naloxone

Loud P2
Lungs clear
Enoxaprin
Pulmonary Embolism

A 30-year-old postpartum woman is admitted to the General Ward with diagnosis of right leg DVT. She was started on enoxaparin 80 mg bid, but in the same day of admission, she developed sudden onset dyspnea and right pleuritic chest pain. On examination, she was dyspneic and apprehensive. Heart sounds showed loud P2 and lungs were clear to auscultation (see lab results and report).

Blood pressure 125/70 mmHg
Heart rate 100 /min
Respiratory rate 22 /min
Temperature 36.6 °C

Oxygen saturation 95 %

Test Result Normal Values
ABG HCO3- 22 22-28 mmol/L
ABG PCO2 4.2 4.7-6.0 kPa
pH 7.48 7.36-7.45
ABG PO2 12 10.6-14.2 kPa

Spiral CT chest:
Thrombus in the right lower pulmonary artery.

Which of the following is the most appropriate step in management?

A. Change enoxaparin to sodium heparin

B. Treat with thrombolytic therapy

**C. Continue the same management

D. Perform invasive thrombectomy

Loud P2
parasternal heave
Massive
Embolism

A 40-year-old man with paraplegia following road traffic accident one year ago is brought to the Emergency Department because of sudden onset dyspnea and chest pain. On examination, he is in severe distress and cyanosed. He has left parasternal heave and loud P2. Chest is clear to auscultation (see lab results and reports).

Blood pressure 80/55 mmHg
Heart rate 110 /min
Respiratory rate 30 /min
Temperature 36.6 °C
Oxygen saturation 86 %

Test Result Normal Values
ABG HCO3- 22 22-28 mmol/L
ABG PCO2 4.2 4.7-6.0 kPa
pH 7.4 7.36-7.45
ABG PO2 8.6 10.6-14.2 kPa

Echocardiogram:
Dilated right ventricle with pulmonary artery pressure of 55 mmHg.

Venous Doppler:
Confirmed DVT in the left leg extending to the thigh.

Which of the following is the best line of management?

A. Insertion of vena-caval filter

**B. Alteplase infusion

C. Enoxaparin

D. Warfarin

TABLE 2.14-20. Causes of Pleural Effusions

TRANSUDATES	EXUDATES
Congestive heart failure	Pneumonia (parapneumonic effusion)
Cirrhosis (hepatic hydrothorax)	TB
Nephrotic syndrome	Malignancy
	Pulmonary embolism
	Collagen vascular disease (SLE)
	Pancreatitis
	Trauma
	Chylothorax (triglycerides)

A 50-year-old woman presented with fever, dyspnea and weight loss. Physical examination showed evidence of pleural effusion in the left hemithorax (see report)

Pleural Effusion

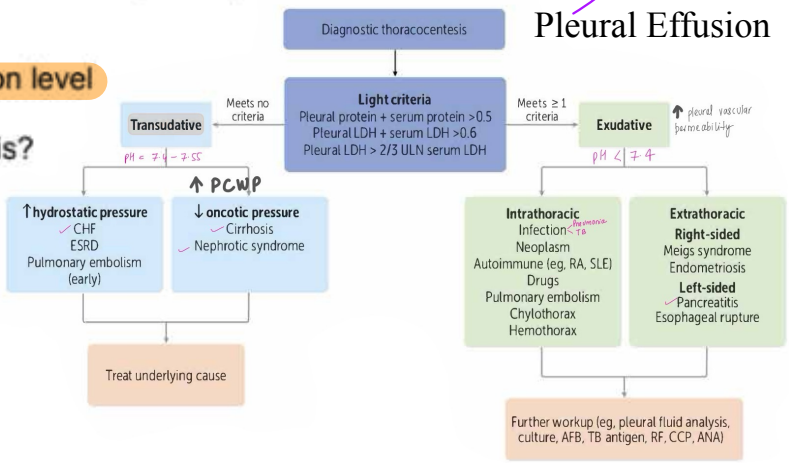

Pleural fluid analysis:
Shows exudative fluid with high gamma interferon level

Which of the following is the most likely diagnosis?

A. Empyema

B. Mesothelioma

C. Parapneumonic effusion

**D. Tuberculous pleural effusion

A 55-year-old man with COPD, presented with increasing dyspnea, cough and bilateral lower limb swelling. Physical examination showed elevated JVP, hepatomegaly and pitting edema in both lower limbs. Chest auscultation revealed scattered rhonchi in both sides.

Which of the following is the most appropriate next step in management?

A. Spirometry

**B. Echocardiogram

C. Venous Doppler of lower limbs

D. High resolution CT scan of chest

In a patient with COPD and cor pulmonale, which of the following improves survival?

A. Montelukast

B. Inhaled steroids

**C. Long term oxygen therapy

D. Long acting beta agonist inhaler

A 30-year-old woman is evaluated for a 6-month history of recurrent dyspnea, cough, and wheezing. She is awakened with asthma symptoms 6-8 nights a month. Her current medication is salbutamol inhaler. On examination, there are wheezes in both lung fields.

MILD INTERMITTENT
SABA
MILD PERSISTENT
SABA + Inhaled Corticosteroid
MOD. PERSISTENT
SABA + ICS + LABA OR
SABA + 1dose ICS
STILL NOT CONTROLLED
SABA + LABA +
MAX. DOSE ICS + Tiotropium
STILL NOT CONTROLLED
ADD ORAL STEROID

Which of the following is the most appropriate next best step in management?

A. Montelukast

B. Long-acting β-agonist

**C. Inhaled budesonide/formoterol

D. Inhaled budesonide and inhaled albuterol as needed

A 30-year-old woman complains of recurrent attacks of sudden onset dyspnea, chest and throat tightness. Inhaled salbutamol is of little help; however, her symptoms improves suddenly. On

examination, she is found to have inspiratory wheeze during dyspnea spells.

Which of the following is the likely cause of symptoms?

A. Bronchial asthma

B. Endobronchial foreign body

C. Gastroesophageal reflux disease

**D. Vocal cord dysfunction syndrome

A 55-year-old obese non-smoker man with hypertension presents with exertional dyspnea for 2 years. His wife stated that he is uncomfortable while sleeping at night and produces loud snores. Examination revealed central cyanosis, suffused conjunctivae and clear chest.

BMI 40 kg/m2

Which of the following has the highest diagnostic value?

A. Spirometry

B. Spiral CT chest

**C. Polysomnography

D. Methacholine challenge test

OSA

A 55-year-old obese non-smoker man presents with loud snoring, daytime somnolence and exertional dyspnea for 4 years. Examination revealed central cyanosis; suffused conjunctivae and clear chest (see lab results).

BMI 40 kg/m2

Test Result Normal Values
ABG HCO3- 38 22-28 mmol/L
ABG PCO2 6.9 4.7-6.0 kPa
pH 7.38 7.36-7.45
ABG PO2 9 10.6-14.2 kPa

Which of the following is the best treatment after polysomnography?

A. Home oxygen by venturi mask

B. Inhaled tiotropium

**C. Home nasal CPAP

D. Oral prednisone

A 65-year-old man with idiopathic bronchiectasis presents with persistent cough of large amount of mucoid sputum and dyspnea on exertion. He is compliant with his medications, which include azithromycin. Physical examination showed finger clubbing and mild bilateral coarse crackles.

Which of the following is the most appropriate treatment option?

A. Prednisone

B. N-Acetylcystine

C. Saline nebulizer

**D. Postural sputum drainage

A 60-year-old man known to have COPD refused the advice to stop smoking.

What is the best statement should be given to him during a communication session?

A. "You better stop smoking otherwise you will die"

**B. "We will do everything to help you stop smoking"

C. "We have to talk to your family about this refusal"

D. "If you don't stop smoking we will stop seeing you in the clinic"

A 56-year-old man who has chronic productive cough underwent a CT chest, which was consistent with bronchiectasis. He came today to discuss his disease.

Which of the following would convey the diagnostic information to him?

A. Read to him the CT report

B. Show him the chest X-ray film

C. Inform him that he has bronchiectasis

**D. Tell him that his air tubules are inflamed and damaged

A young patient has poorly controlled asthma and her doctor decided to start her on oral steroids. She is uncomfortable about that decision.

When counselling this patient, what is the most important communication aspect should be addressed?

A. Her living conditions

**B. The patient's concerns

C. Dealing with her anger

D. The scientific basis of using steroids

A 74-year-old man, who smokes for 40 years, underwent a CT chest, which showed a large lung mass.

Which of the following is the most appropriate way to break the bad news?

A. Avoid wasting time and tell him directly that he has lung cancer

B. Inform him that this is nothing to worry about

C. Inform him that he should stop smoking

**D. Deliver the information in small steps

A patient with interstitial lung disease has repeated admissions for pneumonia. His son is worried about antibiotics induced diarrhoea.

Which of the following is the most appropriate way to address this situation?

A. Tell him that the diarrhoea is not serious

**B. Stress that the hospital infection control policy will be implemented

C. Agree with him that the antibiotics should be stopped

D. Apologize for repeatedly using antibiotics to treat his father

A 28-year-old man, who is a known drug addict, is found in deep coma and cyanosed.

Blood pressure 100/55 mmHg
Heart rate 55 /min
Respiratory rate 8 /min
Oxygen saturation 85 %

Which of the following is the most important initial management?

A. Obtain detailed history from the family

**B. Mechanical ventilation

C. Do gastric lavage

D. Brain CT scan

A 53-year-old man with liver cirrhosis presents with several episodes of vomiting of blood and black tarry stool.

Blood pressure:
Supine 105/60 mmHg
Sitting 85/50 mmHg

Heart rate: Supine 90 /min
Sitting 110 /min

Which of the following is the most appropriate next step in management?

A. Nasogastric tube placement

B. Urgent upper GI endoscopy

**C. Resuscitation with adequate IV fluids

D. Intravenous infusion of H2 receptor antagonists

An elderly man, known to have COPD is brought to Emergency Department with severe respiratory distress, cyanosis and drowsiness. His upper airways were full of secretions (see lab results).

Blood pressure 90/60 mmHg
Heart rate 110 /min
Respiratory rate 18 /min
Temperature 38.0 °C
Oxygen saturation 74 %

Test Result Normal Values
ABG HCO3- 36 22-28 mmol/L
ABG PCO2 7.99 4.7-6.0 kPa
pH 7.24 7.36-7.45
ABG PO2 8.99 10.6-14.2 kPa

Which of the following is the best option in management?

A. Nasal CPAP

**B. Mechanical ventilation

C. Aminophylline infusion

D. Oxygen administration via face mask

GBS

A 40-year-old woman is admitted with diagnosis of Guillain Barre Syndrome.

Which of the following would be the most appropriate method for monitoring ventilatory impairment?

A. Rapid shallow breathing index

B. Serial arterial blood gas measurements

**C. Bedside measurement of vital capacity

D. Continuous monitoring of oxygen saturation

A 60-year-old man with diabetes mellitus and ischemic heart disease is admitted to the Critical Care Unit in shock. The following parameters are obtained from pulmonary artery catheterization (see table).

Pulmonary Artery Catheter Test Result Normal Values
Right atrial pressure 2 2-8 mmHg
Pulmonary artery pressure 15/3 16-24/5-12 mmHg
Wedge pressure 4 5-12 mmHg
Cardiac output 2.5 4-6 L/min
Systemic vascular resistance 1800 800-1200 dyne/s/cm5

Which of the following is the most likely diagnosis?

A. Cardiogenic shock (↑ PCWP)

SHOCK

	HYPOVOLEMIC SHOCK	CARDIOGENIC SHOCK	OBSTRUCTIVE SHOCK	SEPTIC SHOCK	NEUROGENIC SHOCK	ANAPHYLACTIC SHOCK
CAUSE	Volume depletion secondary to hemorrhage, dehydration, burns Dec. Venous return Dec. preload	Left heart dysfunction. Myocardial infarction, Heart failure, Traumatic (contusions)	Right heart dysfunction. (Restriction of chambers). Eg. Cardiac tamponade, pulmonary embolism, tension pneumothorax, coarctation of aorta	Sepsis, Systemic vasodilation	CNS injury, systemic vasodilation	Allergen, systemic vasodilation
CO	↓	↓	↓	↑	↓	↓
HR	↑	↑	↑	↑	↓	↑
SVR (Afterload)	↑	↑	↑	↓	↓	↓
SVO2 Mixed Venous Saturation	↓	↓	↓	↑	Normal/↑	↑
PCWP (Left Heart Preload)	↓	↑	↑	↓	↓	↓
SKIN	Cool, pale, moist	Cool, pale, moist		Warm, flushed	Warm, dry	Pruritis, Urticaria
Rx	IV Fluids	IV fluids, O2, Inotropes (B1-dobutamine), Surgery (Angioplasty, cardiopulmonary bypass)		IV Fluids, Antibiotics	Vasoconstrictors (Noradrenaline, Adrenaline, Dopamine)	**Adrenaline Adults / >12years** 1:1000 0.5ml INTRAMUSCULARLY (not IV). **6 months – 12 years:** 0.3ml 1 in 1,000

B. Septicemic shock

**C. Hypovolemic shock

D. Pulmonary embolism

A 45-year old man is just admitted to the Critical Care Unit with polytrauma following road traffic accident because of hypotension. He is sedated and mechanically ventilated. His heart sounds are distant with no added sounds. Lung auscultation showed equal air entry to both sides with no added sounds (see report).

Blood pressure 85/55 mmHg
Heart rate 110 /min
Temperature 36.0 °C
Oxygen saturation 100 %
Central venous pressure: Right atrial pressure 15 mmHg

Chest radiograph:
Cardiomegaly and fractured sternum. Both lungs are normal.

Which of the following is the most likely diagnosis?

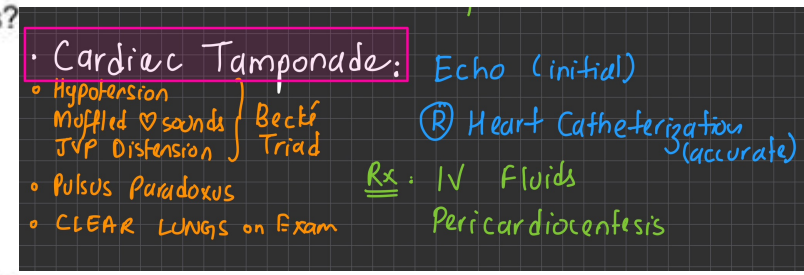

A. Fat embolism

B. Septicemic shock

C. Hypovolemia due to internal bleeding

**D. Cardiac tamponade due to hemopericardium

A 35-year-old man is evaluated in the Orthopedic Ward because of dyspnea, tachycardia and confusion. The patient had fractured left femur for which he undergone internal fixation 2-days ago. He is on enoxaparin as prophylaxis and pain-killer as needed. On examination, the heart sounds are normal and there are scattered crepitations in both lung fields. Petechial rash around the neck and axillae are noticed (see lab result and reports).

Blood pressure 120/70 mmHg
Heart rate 110 /min
Respiratory rate 26 /min
Temperature 37.8 °C
Oxygen saturation 85 %

Test Result Normal Values
ABG HCO3- 22 22-28 mmol/L
ABG PCO2 4.7 4.7-6.0 kPa
pH 7.26 7.36-7.45
ABG PO2 9.5 10.6-14.2 kPa

Chest radiograph:
Bilateral diffuse alveolar infiltrate.

Electrocardiogram:
Sinus tachycardia.

Which of the following is the most likely diagnosis?

A. Pulmonary thromboembolism

**B. Fat embolism syndrome

C. Aspiration pneumonia

D. Septicaemia

A 65-year-old woman with diabetes mellitus and old myocardial infarction is admitted to the Intensive Care Unit with urosepsis and septic shock. Her blood pressure did not respond to fluid challenge for which she is started on norepinephrine infusion. She has hypoxia despite optimizing the ventilator parameters and FiO2 of 100% (see table and report).

Pulmonary Artery Catheter Test Result Normal Values
Right atrial pressure 3 2-8 mm Hg
Pulmonary artery pressure 13/3 16-24/5-12 mm Hg
Wedge pressure 5 5-12 mm Hg
Cardiac output 4 4-6 L/min

Chest X-ray:
Bilateral lung infiltrate.

Which of the following is the most likely cause of the lung infiltrate?

**A. Adult Respiratory Distress Syndrome

B. Cardiogenic pulmonary edema

C. Pulmonary embolism

D. Volume over load

CNS

A 50-year-old man with diabetes and hypertension, presents to the Emergency Department with sudden onset left sided body weakness for 4 hours. On examination, he has left sided upper motor neuron facial palsy and left sided hemiparesis.

Which of the following is the best next step in management?

A. Aspirin

B. Brain MRI

C. Clopidogrel

**D. Brain CT-scan

A 16-year-old boy presents with a several days history of progressive arm and leg weakness. No diplopia or loss of sphincter control. He has been well except for an upper respiratory infection 2 weeks ago. On examination, his breathing is slow and shallow. His heart rate and blood pressure are fluctuant. There is symmetrical weakness of the face and all four extremities. Deep tendon reflexes are absent, and sensations are intact.

Which of the following is the most likely diagnosis?

A. Polymyositis

B. Myasthenia gravis

C. Transverse myelitis

**D. Guillain-Barre syndrome

Cluster Headaches

A 45-year-old man presents with an 8-week history of severe headache. The headaches have occurred at the same time each day; about 2 a.m. and last around 30 minutes. Headaches are accompanied by lacrimation and redness of the right eye.

Which of the following is the best to prevent this type of headache?

**A. Verapamil (Calcium Channel Blocker)

B. Propranolol

C. Sumatriptan

D. 100% oxygen

Rx
* Sumatriptan • Octreotide • Oxygen
Prevent
* Verapamil • Prednisone • CGRP antagonists

A 55-year-old man with diabetes and hypertension complains of pain in the right eye and double vision when looking to the left. On examination, there is ptosis, limited adduction, elevation, and depression of the right eye. The pupils are equal and reactive in both sides. Fundoscopy and other cranial nerve are normal as well as the rest of neurological examination of the upper and lower limbs.

Which of the following is the most likely cause of these findings?

A. Posterior communicating artery aneurism

**B. Diabetic third nerve neuropathy

C. Cavernous sinus thrombosis

D. Mid brain tumor

An 18-year-old boy known to have grand mal epilepsy since childhood is brought to the Emergency Department after having repeated tonic-clonic seizures at home. He is compliant with his medication, which is sodium valproate. In the Emergency Department, he is unconscious and continuously convulsing.

After oxygenation and securing the airway, which of the following intravenous drugs should be administered?

A. Phenytoin

**B. Diazepam

C. Thiopental

D. Phenobarbitone

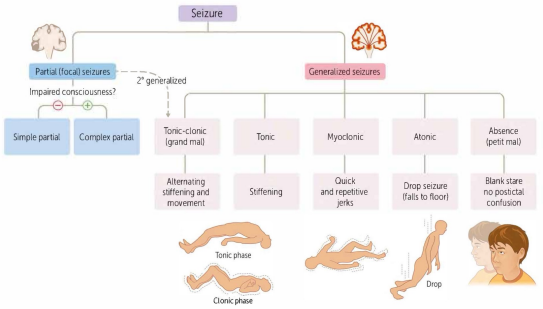

In a patient with Guillain Barre Syndrome, which of the following is the best treatment option?

Treatment is intravenous immunoglobulin (IVIG) or plasmapheresis (equal in efficacy). Do not combine them.

GB syndrome

A. Pulse steroid

B. Cyclosporine

**C. Plasmapheresis

D. Cyclophosphamide

Guillain-Barré Syndrome (GBS) (or acute inflammatory polyneuropathy) is an autoimmune damage of multiple peripheral nerves.

There is no CNS involvement. A circulating antibody attacks the myelin sheaths of the peripheral nerves, removing their insulation.

GBS is associated with Campylobacter jejuni infection.

A 30-year-old woman presents with pain in the right eye associated progressive visual loss over 2 days. She also reported a numbness in the left side of the face and weakness in both lower limbs. Physical examination revealed reduced visual acuity, loss of direct light reflex with preserved indirect light reflex in the right eye. Lower limbs examination showed weakness, clasp knife rigidity, hyperreflexia in both knee and ankle jerks. There is loss of all modalities of sensation in both lower limbs.

Which of the following has the highest diagnostic value?

A. Electromyography

**B. Brain and spine MRI

C. Thoracic spine CT scan

D. Nerve conduction study

NPH

An 80-year-old man has 2-month history of progressive gait disturbance and incontinence. Lately he has been forgetful, confused, and withdrawn. His gait is slow, short-stepped and with tendency to fall backward (see report).

Brain CT scan:
shows dilated ventricles

Normal-pressure hydrocephalus | Gradual, early gait ataxia | ↓CSF absorption → ↑ CSF → lateral ventricles expand → stretch corona radiata → **W**obbly, **W**et, **W**acky | MRI > CT → ventriculomegaly without cortical atrophy = without sulcal enlargement

Which of the following is the most likely diagnosis?

A. Alzheimer's disease

B. Creutzfeldt-Jakob disease

C. Fronto-temporal dementia

**D. Normal-pressure hydrocephalus

ETHICS

An elderly patient sustained a major stroke and he is intubated in the Intensive Care Unit. However, even he was in a very critical state, he managed to write in the bed clothes that he wants to die in peace. Few days later, he passed away without resuscitation according to what he wrote. His son was very angry and said that his father had no mental capacity to decide.

What is the most appropriate stand when dealing with this situation?

**A. Find out whether the son is the real next of kin

B. Tell the son that in anyway his father would have never made it

C. Inform the son that the doctors respected the wish of your father

D. Inform the son that we do not resuscitate patients who are brain dead

A young woman is diagnosed to have multiple sclerosis. She went through an emotional breakdown during breaking bad news.

Which of the following is the most appropriate way to express empathy?

**A. "I share you your feelings and will support you"

B. "Pull yourself up and follow our instructions"

C. "I am very sorry for what happened"

D. "Do not worry, you will be fine"

GIT

A 60-year-old man presents with low-grade fever, insomnia and progressive abdominal distention with vague abdominal pain. Physical examination reveals flapping tremor and moderate ascites. Ascitic fluid analysis showed high SAAG and neutrophil count of 350 cells/L.

Which of the following is the most appropriate management?

**A. Intravenous antibiotic

B. Total paracentesis

C. Syrup lactulose

D. Oral diuretic

TABLE 2.6-22. Ascites Fluid Characteristics

Color	▪ **Bloody:** trauma, malignancy, TB (rare) ▪ **Milky:** chylous ▪ **Turbid:** possible infection ▪ **Straw-colored:** likely more benign causes
Neutrophils	▪ ≥250/mm³: peritonitis (secondary or spontaneous bacterial)
Total Protein	▪ ≥2.5 g/dL (high-protein ascites) ▪ CHF, constrictive pericarditis, peritoneal carcinomatosis, TB, Budd-Chiari syndrome, fungal ▪ <2.5 g/dL (low-protein ascites) ▪ Cirrhosis, nephrotic syndrome

Upper GI endoscopy
Octreotide

A 55-year-old man with Liver cirrhosis is admitted to the hospital with a massive upper gastrointestinal (GI) bleeding.

In addition to volume restoration, which intravenous medication is recommended before upper GI endoscopy?

A. Vitamin K

**B. Octreotide

C. Propranolol

D. Vasopressin

A 28-year-old woman is evaluated because of recurrent lower abdominal pain and diarrhoea for the last 6 months. She also reported having occasional joint pains and a 3 kg weight loss. She received treatment with antibiotics, dietary restrictions, and antispasmodics without improvement. Barium series showed thickening of the terminal ileum and few strictures in the jejunum (see lab results).

Test Result Normal Values
Hb 94 130-170 g/L (Male)
120-160 g/L (Female)
ESR 85 2-10 mm/h (Male)
3-15 mm/h (Female)

Which of the following is expected feature on physical examination?

A. Nail pitting

B. Splenomegaly

**C. Perianal diseases

D. Erythema marginatum

Dysplasia
Barrets

A 56-year-old man presents to the Gastroenterology Clinic with frequent heartburn. He had upper GI endoscopy and biopsy, which revealed Barret's esophagus with low dysplasia.

Which of the following is the best initial option in management?

A. Esophageal resection

**B. Pantoprazole

C. Ranitidine

D. Sucralfate

Finding	Management
Barrett alone (metaplasia)	PPIs and rescope every 3–5 years
Low-grade dysplasia	PPIs and rescope every 6–12 months
High-grade dysplasia	Ablation with endoscopy: photodynamic therapy, radiofrequency ablation, endoscopic mucosal resection

A 60-year-old man with diabetes presented with progressive ascites, fever and weight loss for 2-months. Paracentesis revealed low serum-ascites albumin gradient (SAAG).

Ascites SAAG

Which of the following is the most likely diagnosis?

A. Liver cirrhosis

**B. Peritoneal tuberculosis

C. Veno-occlusive disease

D. Restrictive cardiomyopathy

TABLE 2.6-21. Etiologies of Ascites by SAAG

SAAG > 1.1	SAAG < 1.1
Related to portal hypertension: ▪ Presinusoidal: Splenic or portal vein thrombosis, schistosomiasis ▪ Sinusoidal: Cirrhosis ▪ Postsinusoidal: Right heart failure, constrictive pericarditis, Budd-Chiari syndrome	Not related to portal hypertension: ▪ Nephrotic syndrome ▪ TB ▪ Malignancy with peritoneal carcinomatosis (eg, ovarian cancer)

A 44-year-old man with HBV cirrhosis presents with increasing abdominal girth, lower limb edema, and 10 kg weight gain over the last 3 months. On examination, he has jaundice and moderate ascites (see lab results and report).

6th June DHA

Test Result Normal Values
Sodium 132 134-146 mmol/L

Potassium 3.8 3.5-5.1 mmol/L
Creatinine 65 44-115 µmol/L
Albumin 30 34-56 g/L
Total bilirubin 25 3.5-16.5 µmol/L

Ascetic fluid analysis:
showed an albumin level of 12 g/L and neutrophil count of 180/ul.

In addition to salt-restricted diet, what is the best next step in management?

A. Trans-jugular Intrahepatic Portosystemic shunt

**B. Furosemide and spironolactone

C. Large-volume paracentesis

D. Terlipressin and albumin

In a patient with ulcerative colitis, which of the following is associated with increased risk of colorectal cancer?

A. Colitis limited to the most distal 15 cm of colon

B. Disease of three-year duration

**C. Primary sclerosing cholangitis

D. Mild inflammation

A previously healthy 22-year-old woman reports 3-month history of frequent bloody bowel movements with mucus and occasional right hip pain. She has had no history of contact with sick patient and no recent intake of drugs. Physical examination findings are within normal except for gross blood on rectal examination (see lab results and report).

Test Result Normal Values
Hb 110 130-170 g/L (Male)
120-160 g/L (Female)
MCV 72 80-95 fl

Stool analysis:
Shows many RBCs and few WBCs.

Which of the following is the most likely diagnosis?

A. Internal haemorrhoids

**B. Ulcerative colitis

C. Infectious colitis

D. Celiac disease

A 20-year-old woman with no previous medical illnesses, presented with 7-day history of increasing jaundice, nausea, vomiting and right sided upper abdominal pain (see lab results).

Test Result Normal Values
Total bilirubin 26 3.5-16.5 µmol/L
Aspartate aminotransferase 700 12-40 IU/L
Alanine aminotransferase 1650 5-40 IU/L
Alkaline phosphatase 126 39-117 IU/L

Which of the following tests has the greatest prognostic value?

A. Bilirubin

B. Albumin

**C. Prothrombin time → To see Liver damage

D. Alanine aminotransferase

A 28-year-old woman presents with right lower quadrant abdominal pain, loose bowel motions, and weight loss for 3 months. Colonoscopy and biopsy of the terminal ileum demonstrated non-caseating granulomas.

Which of the following is the most likely diagnosis?

A. Pseudomembranous colitis

B. Intestinal tuberculosis

**C. Crohn's disease

D. Celiac disease

A 25-year-old woman presents with abdominal pain, bloating and weight loss. Physical examination is unremarkable except for BMI 18% (see lab results and report).

6th June DHA

Test Result Normal Values
Hb 90 130-170 g/L (Male)
120-160 g/L (Female)
MCV 70 80-95 fl
Calcium 2.05 2.15-2.62 mmol/L
Phosphate, inorganic 0.79 0.82-1.51 mmol/L

Tissue transglutaminase antibody:
Positive.

Which of the following is the best management?

A. Glucocorticoids

**B. Gluten free diet

C. Metronidazole

D. Ciprofloxacin

A 56-year-old man presents with epigastric pain, bloating and weight loss. Gastroscopy showed antral mass and biopsy is taken (see reports).

Helicobacter pylori breath test:
Positive.

Biopsy report:
Mucosa-Associated Lymphoid Tissue lymphoma (MALToma).

Which of the following is the next step in management?

**A. Eradication therapy for H. Pylori

B. Referral for gastrectomy

C. Chemotherapy

D. Radiotherapy

A young woman who is known to have pan ulcerative colitis is admitted for a severe relapse. Since there was no response to medical treatment, surgery is decided. The patient is very sceptical about surgery and requested more information.

What is the appropriate way to address her concerns?

A. Tell her that she will die if surgery is not performed

B. Discard her concerns as unfounded and push her for surgery

C. Inform her that surgery will leave her with a colostomy bag

**D. Agree on another meeting with the surgeon and the gastroenterologist

Ethics

A 52-year-old man, who has been medically treated as peptic ulcer for a long time, underwent upper endoscopy, which showed a malignant ulcer. During the visit, he started blaming his primary physician and wanted to file a complaint.

Which of the following is the most appropriate response?

**A. Agree that it is his right to do so

B. Take a neutral stand in this issue

C. Inform him that his doctor did what he could do

D. Tell him that he should blame himself not his doctor

Ethics

A married man, who had a trip to Thailand 2 months ago, is complaining of recurrent diarrhoea and weight loss. He underwent HIV testing which came reactive. However, he requested not to tell anyone including his wife.

Which of the following is the best response?

A. Disclose the result to his employer

B. Request the social worker to inform his wife

**C. Report to the infection control unit in the hospital

D. Respect his request not to disclose the result to anyone

Empyema
Pleuritic chest pain
Pleural effusion

A 60-year-old man presented with high-grade fever and left pleuritic chest pain. On examination, he has early clubbing and evidence of moderate pleural effusion in the left side of the chest. Pleural fluid analysis revealed pH of 7.0.

Which of the following is the most likely diagnosis?

**A. Empyema

B. Chylothorax

C. Parapneumonic effusion

D. Tuberculous pleural effusion

CVS

A 65-year-old man with diabetes and hypertension is admitted with extensive anterior elevation

myocardial infarction (STEMI), had successful angioplasty and stenting to left anterior descending artery. Aspirin, clopidogrel, bisoprolol and enalapril were started (see lab results).

Test Result Normal Values
Cholesterol (HDL) 1.0 >1.03 mmol/L
Cholesterol (LDL) 3.36 <3.36 mmol/L
Total Cholesterol 5.0 <5.1 mmol/L
Triglycerides 2.2 <2.16 mmol/L

Which of the following is recommended?

A. No additional medication is indicated

**B. Atorvastatin

C. Fenofibrate

D. Niacin

A 55-year-old man with diabetes presented to the Cardiology Clinic with vague chest pain with exertion for 2 months (see report).

Electrocardiogram:
Normal.

Which of the following is the most appropriate next step in management?

A. Assurance

**B. Exercise ECG testing

C. Coronary angiogram

D. Adenosine myocardial perfusion imaging

A 60-year-old man with poorly controlled hypertension presents with exertional dyspnea and occasional paroxysmal nocturnal dyspnea. No chest pain or palpitation. On examination, he is comfortable at rest; the JVP is 3 cm above sternal border, loud A2 and left ventricular S4, no murmur (see reports).

Blood pressure 160/100 mmHg
Heart rate 76 /min
Respiratory rate 18 /min
Oxygen saturation 95 %

Electrocardiogram:
Shows sinus rhythm and left ventricular hypertrophy.

Echocardiogram:
Normal cardiac chambers size, concentric left ventricular hypertrophy and normal left ventricular ejection fraction.

Which of the following is the most likely diagnosis?

**A. Left vntricular diastolic dysfunction

B. Restrictive cardiomyopathy

C. Silent myocardial ischemia

D. Constrictive pericarditis

A 30-year-old man is found to have cardiomegaly on chest X-ray during pre-employment check-up. He denies chest pain, dyspnea, orthopnea or PND. Physical examination unremarkable (see reports).

Blood pressure 120/80 mmHg
Heart rate 76 /min
Respiratory rate 18 /min

Electrocardiogram:
Normal.

Echocardiogram:
Dilated left ventricle with ejection fraction of 40%.

Which of the following is the best management?

A. Digoxin

**B. Lisinopril

C. Furosemide

D. Echocardiogram in 6 months

MITRAL

A 45-year-old man with previous history of rheumatic heart disease presents with worsening dyspnea, orthopnea and PND. Physical examination shows holosystolic murmur in the apex and bibasilar crackles on lung auscultation. His symptoms improved with furosemide, spironolactone, enalapril and carvedilol (see report).

Echocardiogram:
Showed mildly dilated left ventricle, LVEF 45% and severe rheumatic mitral regurgitation.

Which of the following is the best next step in management?

A. Digoxin

B. Losartan

C. Follow-up in 6 months

**D. Mitral valve replacement

Atrial Stenosis

A 70-year-old man is found to have ejection systolic murmur in the aortic area during routine medical check-up. He denied symptoms of dyspnea, chest pain or syncope. Physical examination revealed slow raising carotid pulsation; normal JVP and normal lung auscultation (see reports).

Blood pressure 110/70 mmHg
Heart rate 76 /min

Respiratory rate 18 /min

Electrocardiogram:
Normal sinus rhythm with LVH.

Echocardiogram:
Shows concentric LVH, normal ejection fraction and severely stenosed aortic valve.

Which of the following is the next step in management?

A. Aortic valve replacement

**B. Follow-up in 6 months

C. Furosemide

D. Enalapril

A 30-year-old woman with history of rheumatic heart disease since childhood presented with exertional dyspnea and occasional paroxysmal nocturnal dyspnea. Physical examination showed JVP of 5 cm above sternal angle, loud S1, loud P2 and mid diastolic rumbling murmur in the apex. Fine basal crackles are present on lung auscultation.

Which of the following is the most likely diagnosis?

**A. Mitral stenosis

B. Aortic stenosis

C. Tricuspid stenosis

D. Pulmonary stenosis

A 60-year-old man presents with abdominal distension dyspnea and orthopnea. The JVP is markedly elevated and fails to descend during inspiration. Lower limbs showed massive pitting edema up to the thighs. Heart sounds are normal. There are bibasilar crackles on lung auscultation. Abdominal examination showed hepatomegaly and positive shifting dullness (see report).

Echocardiogram:
Both atria are dilated. Left and right ventricles are normal in size and LVEF is 60%. No valve lesions.

Which of the following has the highest diagnostic value?

A. Holter monitor

**B. Cardiac CT scan

C. Coronary angiogram

D. Exercise ECG testing

An 18-year-old boy presents with recurrent syncope with exercise. Physical examination showed normal JVP, jerky carotid pulsations and thrusting apex. There is an ejection systolic murmur, which is best heard in the left parasternal area that increases in intensity with standing

and reduced during handgrip (see report).

Blood pressure 110/70 mmHg
Heart rate 76 /min

Electrocardiogram:
Shows left ventricular hypertrophy.

Which of the following is the most likely diagnosis?

A. Aortic stenosis

B. Pulmonary stenosis

C. Ventricular septal Defect

**D. Hypertrophic obstructive cardiomyopathy

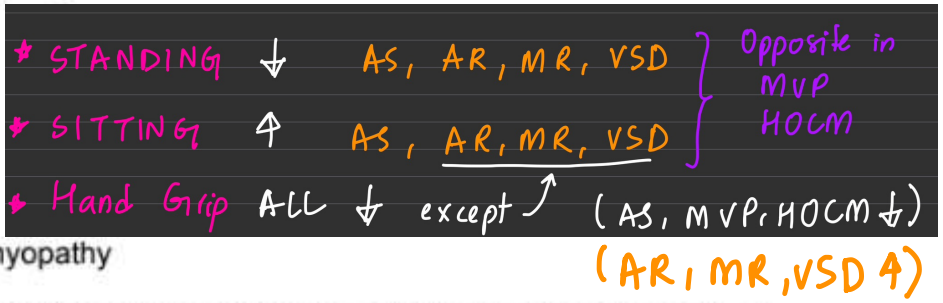

HOCM

A young man with diagnosis of hypertrophic cardiomyopathy presented with recurrent exertional chest pain and syncope.

Which of the following is the best management?

A. Nifedipine

**B. Metoprolol

C. Hydralazine

D. Nitroglycerine

Rx: β-blocker — 1st line
Diltiazem
Verapamil — 2nd line
CONTRA-INDIC → Spironolactone, Digoxin, ACE ⊖

A 65-year-old woman with diabetes and hypertension, presented with retrosternal chest pain at rest for 3 hours. Physical examination is normal except for S4 gallop (see lab result and report).

Blood pressure 110/70 mmHg
Heart rate 76 /min
Oxygen saturation 95 %

Test Result Normal Values
Troponin 10 < 0.2 pg/L

Electrocardiogram:
T-wave inversion in leads V2-V5.

Which of the following is the most likely diagnosis?

A. Stable angina

B. Unstable angina

C. Elevation myocardial infarction

**D. Non ST elevation myocardial infarction

A 60-year-old man with diabetes and hypertension is admitted to the Coronary Care Unit with diagnosis of unstable angina. Physical examination is normal except for S4 gallop. Aspirin, bisoprolol, enoxaparin, atorvastatin and nitrate are started (see lab result and reports).

Blood pressure 110/70 mmHg
Heart rate 76 /min
Respiratory rate 18 /min

Test Result Normal Values
Troponin .001 < 0.2 pg/L

Electrocardiogram:
Showed ST depression in leads II, III, AVF.

Echocardiogram:
Normal.

What additional medication is indicated?

**A. Clopidogrel

B. Candesartan

C. Streptokinase

D. Spironolactone

A 30-year-old man presents with burning retrosternal chest pain associated with dyspnea. His history is significant only for common cold 2 weeks ago (see image).

Which of the following clinical signs is likely to be present?

A. Murmur

**B. Pericardial rub

C. Cannon a-wave

D. Fourth heart sound

A 70-year-old man presents with dyspnea, fatigue and presyncope. On examination, the JVP showed Cannon a-wave and variations in the intensity of the first heart sound (see image).

Heart Block

Which of the following is the definitive treatment?

A. Implantable cardioverter defibrillator

**B. Permanent pacemaker

C. Oral theophylline

D. Oral metoprolol

Key feature	Diagnosis
Bradycardia, cannon A waves	Third-degree AV block
No cannon A waves	Sinus bradycardia
Sudden loss of pulse, jugulovenous distention	Tamponade/wall rupture
IWMI in history, clear lungs, tachycardia, hypotension with nitroglycerin	RV infarction
New murmur, rales/congestion	Valve rupture
New murmur, increase in oxygen saturation on entering the right ventricle	Septal rupture
Loss of pulse, need EKG to answer question	Ventricular fibrillation

A 64-year-old woman with advanced breast cancer complains of dyspnea on exertion. On examination, her systolic blood pressure is noted to markedly decrease during inspiration. Heart

sounds are distant to auscultation. Chest is clear (see report).

Blood pressure 95/65 mmHg
Heart rate 100 /min
Respiratory rate 24 /min
Temperature 36.6 °C
Oxygen saturation 95 %

Chest x-ray:
Marked cardiomegaly with clear lung fields.

Which of the following is the most likely diagnosis?

A. Hypertrophic obstructive cardiomyopathy

B. Restrictive cardiomyopathy

C. Dilated cardiomyopathy

**D. Cardiac tamponade

Gallops

A 65-year-old woman with diabetes and hypercholesterolemia presents to the Emergency Department with chest tightness associated with sweating and nausea of 4-hour duration. Physical examination showed elevated JVP, which increases further during inspiration, S4 gallop and clear lung fields on chest auscultation. Aspirin and clopidogrel were given. Results of cardiac enzymes are pending (see image).

Blood pressure 90/55 mmHg
Heart rate 76 /min
Respiratory rate 18 /min
Oxygen saturation 95 %

Gallops:

- **S_3 gallop:** A sign of fluid overload (eg, heart failure, mitral valve disease); often normal in younger patients and in high-output states (eg, pregnancy).
- **S_4 gallop:** A sign of decreased compliance (eg, hypertension, aortic stenosis, diastolic dysfunction); usually pathologic but can be normal in younger patients and in athletes.

Which of the following immediate action should be taken?

A. Chest X-ray

B. Echocardiogram

C. Coronary CT angiogram

**D. ECG with right chest leads

Murmur

A 25-year-old woman presented with dyspnea and cyanosis. Physical examination revealed elevated JVP with predominant a-wave and left parasternal heave. There is an ejection systolic murmur best heard in the left second intercostal space that increases in intensity during inspiration. An ejection click is also heard in the same area.

Blood pressure 110/70 mmHg
Heart rate 76 /min
Respiratory rate 20 /min

Which of the following is the most likely diagnosis?

A. Aortic stenosis

B. Coarctation of aorta

C. Ventricular septal defect

**D. Conginital pulmonary stenosis

A 70-year-old man is admitted for stomach resection for gastric cancer. On the 4TH postoperative day, the patient developed retrosternal chest pain accompanied with dyspnea and perfuse sweating. Physical examination is remarkable only for S4. Aspirin, clopidogrel and nitrate were administered (see report).

Blood pressure 110/70 mmHg
Heart rate 76 /min
Respiratory rate 18 /min
Temperature 36.6 °C
Oxygen saturation 95 %

Electrocardiogram:
Shows ST elevation in leads V2-V5.

Which of the following is the most appropriate step in management?

A. Thrombolytic therapy

**B. Primary angioplasty

C. Abciximab

D. Warfarin

A 70-year-old man with hypertension, diabetes and aortic sclerosis discovered to have atrial fibrillation on routine health check-up. He denies dyspnea, chest pain or palpitations.

Which of the following drugs is recommended to prevent systemic embolization?

A. Aspirin

**B. Warfarin

C. Clopidogrel

D. Rivaroxaban

A 22-year-old woman presents with retrosternal burning chest pain, which is worse during breathing and coughing. Precordial auscultation showed an added sound of 3 components; systolic, diastolic and presystolic (see image).

Which of the following is the best initial treatment?

A. Tissue plasiminogen activator

B. Enoxaparin

**C. Ibuprofen

D. Prednisone

In a patient with heart failure due to dilated cardiomyopathy presenting with fast atrial fibrillation, which of the following drugs is the most appropriate to control the heart rate?

**A. Digoxin

B. Diltiazem

C. Ivabradine

D. Propranolol

A 40-year-old man is admitted with palpitations of 4-hour duration. He had similar attack a month ago but did not seek medical advice. His initial electrocardiogram showed atrial fibrillation with controlled ventricular rate. He subsequently converted to sinus rhythm.

Which of the following drugs is the most appropriate to maintain sinus rhythm?

A. Digoxin

B. Bisoprolol

C. Verapamil

Rate control

**D. Amiodarone

Rheumatic fever

An 18-year-old girl is recently diagnosed to have rheumatic fever with carditis. Echocardiogram showed mild mitral stenosis with mild regurgitation.

To what age the rheumatic fever prophylaxis is recommended?

**A. 40

B. 28

C. 23

D. 21

Table 2: Contraindications to Thrombolytic Therapy

Absolute Contraindications
Any prior intracranial hemorrhage
Known intracranial malformation or neoplasm
Ischemic stroke <3 month
Suspected dissection
Recent surgery
Recent head trauma
Bleeding diathesis
Relative Contraindications
>75 years of age
Current anticoagulants
Pregnancy
Cardiopulmonary resuscitation >10 minutes
Recent internal bleed (2–4 weeks)
Uncontrolled hypertension (180/110 mmHg)
Remote ischemic stroke
Major surgery within 3 weeks

Modified from Jaff et al.[9]

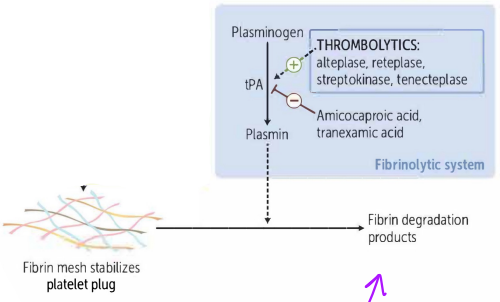

Thrombolysis CI
Thrombolytics

Which of the following is an absolute contraindication for thrombolytic therapy?

A. Pregnancy

**B. Intracranial hemorrhage 2 years ago

C. Cardiopulmonary resuscitation for 10 min

D. Blood pressure at presentation of 180/110 mmHg

Contraindications to Thrombolytics

- Major bleeding into the bowel (melena) or brain (any type of CNS bleeding)
- Recent surgery (within the last 2 weeks)
- Severe hypertension (>180/110 mm Hg)
- Nonhemorrhagic stroke within the last 6 months

Palpitations

A 28-year-old woman presents to the Cardiology Outpatient Department with recurrent palpitations for the last 6 months. She describes the palpitations as fast heartbeat, which starts and ends suddenly. Each attack lasts 5-10 min. No associated chest pain, dyspnea, syncope or presyncope (see lab result and report).

Test Result Normal Values
Hb 132 130-170 g/L (Male)

120-160 g/L (Female)
Thyroid-Stimulating Hormone 3.8 0.4 - 5.0 µU/mL

Electrocardiogram:
Normal sinus rhythm with rate of 70/min.

Which of the following is the best next investigation?

A. Exercise ECG testing

B. Electrophysiology

C. Echocardiogram

**D. Holter monitor

Ethics

An elderly patient is admitted with diagnosis of unstable angina. He is known to have atrial fibrillation and taking warfarin. The attending resident administered heparin but did not check the INR, which came back as 6.8. The patient developed bleeding from the gums and hematuria. His son is upset, and he requests an explanation.

Which of the following is the most appropriate response?

A. Say that you are sorry for what happened and request him to calm down

**B. Apologize and reassure him that you will start an investigation

C. Tell him that this is an expected side effect of the drug

D. Inform him that the situation is under control

A 60-year-old man with hypertension and diabetes undergone coronary angiogram, which showed 3-vessel disease requiring coronary bypass surgery. The patient refused surgery.

Being the resident with the team, what is the appropriate communication tool to be used?

A. Use the SPIKES protocol

B. Tell the son to speak to the patient

C. Respect autonomy and continue medical treatment

**D. Apply the counselling in the presence of the consultant

A patient who presented with heart failure had an echocardiogram, which showed severe rheumatic mitral regurgitation requiring valve replacement. He is waiting to know the result.

Which of the following is the most appropriate way to break the news?

A. Avoid asking him about what he already knows

B. Tell him all the details from the beginning

C. Express more sympathy than empathy

**D. Deliver the information in small steps

A 53-year-old widow with dilated cardiomyopathy presented to the Cardiology Clinic with decompensated heart failure. She lives alone, has no insurance and cannot afford the cost of medications.

During counselling, which of the following is the most appropriate plan?

A. Arrange for a charity organization to help her financially

**B. Involve the social worker and the hospital support system

C. Refer her to the Emergency Department

D. Advise her to avoid salt and stop smoking

A 79-year-old man with multiple co-morbidities is hospitalized for dissecting aneurysm and needs urgent surgery. He lives alone and he has no written will or advanced directive. His condition is very critical in the ICU.

What is the best way to arrange the consent for surgery?

**A. The attending medical team should sign the consent form

B. The social worker is asked to complete the consent form

C. Proceed for emergency and delay the consent

D. Request a court decision

A 38-year-old man presented to the Emergency Department with 5-day history of fever and a productive cough (see lab results and reports).

Blood pressure 100/65 mmHg
Temperature 39 °C

Test Result Normal Values
WBC 12 4.5-10.5 x 109/L
ESR 26 2-10 mm/h (Male)
3-15 mm/h (Female)

Chest X-ray:
Right middle lobe infiltrate.

Sputum culture:
Pending.

Which of the following is the most appropriate immediate therapy?

**A. Moxifloxacin 400mg IV once daily

B. Ceftazidime 1 gm IV every 8 hours

C. Meropenem 1 gm IV every 8 hours

D. Piperacillin /Tazobactam 4.5 gm every 6 hours

A 27-year-old man presented to the Emergency Department with 2-days history of confusion and 5-hours history of seizures. Positive history of multiple unprotected sexual contact for the last 6 years. On examination, he was disoriented to time; place and person (see lab results and report).

Temperature 39 °C

Test Result Normal Values
WBC 1.3 4.5-10.5 x 109/L

Serum Cryptococcal Antigen:
Positive.

Which of the following is the most appropriate diagnostic test?

**A. HIV serology

B. CSF toxoplasma PCR

C. CSF culture for syphilis

D. Herpes Simplex Polymerase chain reaction (PCR)

A 22-year-old man recently diagnosed with HIV presented to the clinic for counselling.

Whom should he disclose his HIV status to?

**A. Wife

B. Parents

C. Brother

D. Employer

A 53-year-old man recently diagnosed with HIV came to the clinic for counselling.

Who should be offered HIV testing?

A. Parents

**B. Ex-wife

C. 28-year-old son

D. Office colleagues

A 69-year-old man known to have diabetes mellitus, presented to Emergency department with 4-day history of productive cough and tachypnea. On examination, oriented to time place and person. Chest exam revealed right lower lobe crepitation (see lab results and report).

Respiratory rate 23 /min
Temperature 38.5 °C

Test Result Normal Values
WBC 12 4.5-10.5 x 109/L
Urea 5 2.75-7.4 mmol/L

Chest X-Ray:
Right lower lobe infiltrate.

Which of the following is the most appropriate management approach?

**A. Admit to general ward and start IV antibiotics

B. Admit to Intensive care unit and start IV antibiotics

C. Start oral antibiotics and observe in Emergency Room for 24 hours

D. Start oral antibiotics and see in outpatient clinic in 7-days

A 70-year-old woman known to have hypertension on medication. Presented to the Emergency Department with 4-days history of productive cough, shortness of breath and tachypnea. Chest exam, right lobe zone crepitation.

Temperature 38.5 °C

Which of the following is the most appropriate next diagnostic test to confirm the diagnosis?

**A. Chest X-ray

B. Elevated WBC

C. Sputum culture

D. Echocardiogram

Sputum

A 54-year-old man known to have diabetes and hypertension presented to Emergency Department with 9-days history of cough, headache, shortness of breath and fever. Cough was productive of white sputum, which has become yellowish lately. On chest examination, wheezing, and right side crepitation (see lab results and reports).

Temperature 38 °C

Test Result Normal Values
Reticulocyte 8 0.2-1.2 %
WBC 12 4.5-10.5 x 109/L

Cold agglutinin titre:
1:256

Chest X-Ray:
Bilateral shadowing both lungs with more density on the right middle lobe.

Which of the following is the most likely diagnosis?

A. Bronchial asthma exacerbation

B. Streptococcal pneumonia

**C. Atypical pneumonia

D. Exacerbation of heart failure

Doxycycline

A 28-year-old woman referred to the clinic with 3-weeks history of generalized fatigability, malaise, arthralgia, back pain and fever. Positive history of raw milk ingestion. Abdominal examination, mild hepato-splenomegaly (see lab results and report).

Temperature 39 °C

Test Result Normal Values
Hb 10.5 130-170 g/L (Male)
120-160 g/L (Female)
Platelets count 120 150-400 x 109/L

Blood culture:
Gram negative cocco-bacilli.

Which of the following is the first line in treatment option?

A. Doxycycline and clindamycin

**B. Doxycycline and streptomycin

C. Ciprofloxacin and trimethoprim sulfamethoxazole

D. Rifampin and trimethoprim sulfamethoxazole

A 28-year-old woman referred to the clinic with 3-week history of generalized fatigability, malaise, arthralgia, back pain and fever. Positive history of raw milk ingestion. Abdominal examination, mild hepato-splenomegaly (see lab results and reports).

Temperature 38.5 °C

Test Result Normal Values
Hb 10.5 130-170 g/L (Male)
120-160 g/L (Female)
Platelets count 120 150-400 x 109/L

Blood culture:
Gram negative cocco-bacilli.

MRI of the back:
Sacroiliac joint spondylitis.

Which of the following is the optimal duration of therapy?

A. 3 weeks

B. 6 weeks

**C. 12 weeks

D. 24 weeks

TB

A 45-year-old housemaid from Southeast Asia, recently came to Saudi Arabia, presented to the Emergency Department with 2-weeks history of productive cough and shortness of breath. Positive history of hemoptysis. Chest exam showed right upper zone crepitations (see lab results and report).

Temperature 38.5 °C

Test Result Normal Values
WBC 14 4.5-10.5 x 109/L
ESR 73 2-10 mm/h (Male)
3-15 mm/h (Female)

Chest X-Ray:
Right upper lobe infiltrate and cavitation.

Which of the following is the most appropriate next step?

A. IV ceftriaxone

B. Bronchoscopy

**C. Sputum for acid fast bacilli

D. Isoniazid, rifampin, pyrazinamide and ethambutol

A 45-year-old man admitted to the hospital with history of productive cough and shortness of breath. He was found to have cavitatory pulmonary tuberculosis (TB). He was started on 4 anti-TB drugs. Few days later, he noticed that the urine color is red. Detailed history revealed family history of urethral stones (see lab results).

Test Result Normal Values
Hb 11 130-170 g/L (Male)
120-160 g/L (Female)
Platelets count 110 150-400 x 109/L

Which of the following is the most likely cause of his new symptom?

A. Urethral stones

B. Renal tuberculosis

**C. Medication side effect

D. Hematological abnormalities related to TB

A 45-year-old man admitted to the hospital with history of productive cough and shortness of breath. He was found to have positive acid fast bacilli (AFB) in sputum. He was started on isoniazid, rifampin, pyrazinamide and ethambutol. He came back to the clinic for follow up after

3-weeks. Cough was better and no other symptoms (see lab results).

Admission lab results: Test Result Normal Values
Total bilirubin 5 3.5-16.5 µmol/L
Aspartate aminotransferase 28 12-40 IU/L
Alanine aminotransferase 32 5-40 IU/L
ESR 75 2-10 mm/h (Male)
3-15 mm/h (Female)

Follow-up lab results: Test Result Normal Values
Total bilirubin 0.7 3.5-16.5 µmol/L
Aspartate aminotransferase 75 12-40 IU/L
Alanine aminotransferase 80 5-40 IU/L
ESR 35 2-10 mm/h (Male)
3-15 mm/h (Female)
Sputum AFB Negative

Which of the following is the best management approach?

**A. Continue anti-TB and repeat LFT in 1 week

B. Stop all anti-TB and repeat LFT in 1 weeks

C. Stop pyrazinamide and repeat LFT in 2 weeks

D. Stop isoniazid and rifampin and repeat LFT in 2 weeks

A 60-year-old man known to have hypertension and post aortic valve replacement on lisinopril 20 mg, amlodipine 5 mg and warfarin 3 mg once daily. He was admitted to the hospital with history of productive cough and shortness of breath, and was found to have positive acid fast bacilli (AFB) in sputum. First line four anti-TB drugs were started.

Which of the following regarding medications should be done?

A. Lisinopril dose needs to be decreased

B. Amlodipine needs to be stopped

**C. Warfarin needs to be increased

D. Rifampin should be stopped

A 60-year-old man from India presented to the Emergency Department with headache and low-grade fever for 3-weeks. The headache became worse over the last 2-days and was associated with vomiting. In the emergency room, he developed generalized seizures (see lab results and reports).

Test Result Normal Values
WBC 19 4.5-10.5 x 109/L
Pressure 280 200-250 mmH2O (Male)
300-400 mmH2O (Female)
Cells 380 0-3 /µL
Total protein (Men) 3 0.22-0.33 g/L
Glucose 1.2 2.50-3.89 mmol/L

CSF differential WBC count:
73% lymphocytes and 13 % neutrophils.

CSF culture:
Pending.

Which of the following is the most likely diagnosis?

A. Neurocysticercosis

**B. Tuberculous meningitis

C. Bacterial meningitis

D. Viral meningitis

SKIN Infections
Malaria Dengue

A 53-year-old woman known diabetic, hypertensive and cardiac arrhythmia on amiodarone, presented to Emergency Department with 3-days history of progressive redness and pain on her right leg. Examination showed a sharply demarcated red lesion, which was tender with no ulcer.

Temperature 38.8 °C

Which of the following is the most likely diagnosis?

**A. Erysipelas

B. Erythema nodosum

C. Side effect of Amiodarone

D. Necrobiosis lipodica diabeticorum

A 53-year-old woman known diabetic presented to the Emergency Department with 5-days history of progressive redness and pain on her right thigh. On examination, right thigh showed 15 cm red lesion, which was tender with no ulcer (see report).

Temperature 38.3 °C

Ultrasound:
Showed inflammatory changes and 10 x 8 cm deep abscess collection.

Which of the following is the best management approach?

A. Admit to ward and start IV antibiotics

B. Admit to ICU and start IV antibiotics

C. Discharge home on oral antibiotics with 1-week follow up

**D. Admit to ward, start IV antibiotics, and surgical consultation

A 53-year-old woman recently returned from Egypt, known diabetic, presented to the Emergency Department with 3-days history of progressive redness and pain on her right shin.

Positive history of allergy to penicillin. On examination, right leg has red lesion, which was tender with no ulcer. She was started on oral antibiotics. Next day she complained of abdominal pain, watery diarrhoea and fever.

Temperature 37.8 °C

Which of the following is the most likely diagnosis?

A. Worsening of diabetic gastroparesis

B. Allergy to antibiotic

**C. Clostridium difficile infection

D. Salmonellosis

A 63-year-old woman known diabetic for the last 20-years on insulin, presented to the Emergency Department with 3-days history of right knee pain and swelling. Right knee examination revealed, red, swollen and tender with severely limited range of movement. Other joints were normal (see lab result and report).

Temperature 39 °C

Test Result Normal Values
WBC 17 4.5-10.5 x 109/L

Synovial fluid:
WBC: 55,000
Crystals: Pending
Culture: Negative

Which of the following is the most likely diagnosis?

A. Charcot joint

**B. Septic arthritis

C. Gout arthritis

D. Pseudo-gout arthritis

A 32-year-old man presents to the Emergency Department with 3-days history of generalized body aches, sore throat, runny nose, productive cough and shortness of breath. Chest exam shows right lung crepitations. The patient was admitted and according to the results of throat swab was started on oseltamivir (see report).

Temperature 39 °C

Chest X-Ray:
Right middle lobe infiltrate.

Which of the following isolation precautions should be considered?

A 56-year-old diabetic man presented with cough and fever. Chest-XR showed cavity at upper lobe of the left lung.

What is the type of precaution required when dealing with this patient?

A. Droplet

B. Contact

**C. Airborne

D. Standard

A. Contact

B. Standard

C. Airborne

**D. Droplet

A 33-year-old woman presents with headache and myalgia for 5 days. 2 days ago, she started to have fever and noticed a skin rash on her face. She returned from Jeddah 10-days ago (see lab results).

Test Result Normal Values
Hb 8 130-170 g/L (Male)
120-160 g/L (Female)
Platelets count 80 150-400 x 109/L

Which of the following is the most appropriate next step in management?

A. Steroid

B. IV antiviral

C. IV antibiotics

**D. Supportive management

Malaria

A 27-year-old soldier going to a military mission at the Southern border of Saudi Arabia. His medical history is insignificant apart from a positive history of depression, which is controlled by medication. He came for counselling regarding malaria prevention.

Which of the following is the best malaria chemoprophylaxis regimen?

**A. Atovaquone-proguanil

B. Doxycycline

C. Mefloquine

D. Chloroquine

A 30-year-old man presents to the Emergency Department with history of fever and headache. He recently came from a trip to Sudan, where he stayed there for 10-days. Abdominal examination, palpable spleen 3 cm below costal margin (see lab results).

Temperature 40 °C

Test Result Normal Values
Hb 9 130-170 g/L (Male)
120-160 g/L (Female)
Platelets count 90 150-400 x 109/L
Aspartate aminotransferase 88 12-40 IU/L
Alanine aminotransferase 94 5-40 IU/L

Which of the following is the first line treatment option?

A. Quinine

B. Mefloquine

C. Chloroquine

**D. Artemisinin based combination therapy

A 45-year-old man, heavy smoker, presents to the Emergency Department with 5-days history of fever and skin rash and 3-days of dyspnea and dry cough. Skin examination shows vesicular lesions over the truck and extremities, some of the lesions were crusted. Chest examination shows bilateral crepitation's (see report).

Respiratory rate 28/min
Temperature 39 °C
Oxygen saturation 82 %

Chest X-Ray:
Diffuse bilateral infiltrate.

Which of the following is the most appropriate intravenous treatment option?

A. Ceftriaxone and azithromycin

**B. Acyclovir

C. Steroids

D. Furosemide

Meningitis

A 22-year-old man recently returned from Umrah, presents to Emergency Department with 1-day history of fever and headache. Upon arrival to the Emergency Department, he started to have seizures on the right extremities. On examination, positive Kerning sign (see lab results and report).

Temperature 39 °C

Test Result Normal Values
Cells 380 0-3 /µL
Total protein (Men) 1.2 0.22-0.33 g/L

CSF analysis:
WBC differential count : 87% neutrophils and 5% lymphocytes.

Which of the following is the most appropriate intravenous treatment option?

**A. Ceftriaxone, vancomycin and steroid

B. Ceftriaxone and vancomycin

C. Ceftriaxone and IV acyclovir

D. Acyclovir and steroid

A 22-year-old man presents to Emergency Department with 4-days history of fever, headache and confusion. On examination, Kernig's sign is present (see lab results and reports).

Temperature 39 °C

Test Result Normal Values
Cells 380 0-3 /µL
Total protein (Men) 0.8 0.22-0.33 g/L
Glucose 3.7 2.50-3.89 mmol/L

CSF analysis:
WBC differential count : 5% neutrophil and 90% lymphocytes.

CSF Culture:
Pending.

Which of the following is the most appropriate intravenous treatment option?

A. Ceftriaxone , vancomycin and steroid

B. Ceftriaxone and vancomycin

C. Ceftriaxone

**D. Acyclovir

Precautions
Droplet
Airborne

A 22-year-old man recently returned from Hajj, presents to Emergency Department with 1-day history of fever and headache. On examination, Kernig's sign is present. Skin examination showed petechial rash on extremities and trunk (see lab results and report).

Temperature 39 °C

Test Result Normal Values
Cells 380 0-3 /µL
Total protein (Men) 0.9 0.22-0.33 g/L
Glucose 1.2 2.50-3.89 mmol/L

CSF analysis:
WBC differential: 87% neutrophils and 5% lymphocytes.

Which of the following isolation precautions should be considered?

A. Contact

**B. Droplet

C. Standard

D. Airborne

A 27-year-old man recently returned from Umrah. Presents to Emergency Department with 1-

day history of fever and headache. On examination, positive Kernig's sign and petechial rash on extremities and trunk. He was isolated and started on antibiotics (see lab results and report).

Temperature 39 °C

Test Result Normal Values
Cells 380 0-3 /µL
Total protein (Men) 0.9 0.22-0.33 g/L
Glucose 1.2 2.50-3.89 mmol/L

CSF analysis:
WBC differential 87 % neutrophil and 5 % lymphocytes.

How many hours after starting antibiotics should isolation be discontinued?

A. 12

**B. 24

C. 48

D. 72

A 64-year-old diabetic woman was recently started on hemo-dialysis through a femoral central line. During dialysis, the nurse notices that she is shivering. Detailed history reveals a 3-day history of fever. On examination, central line site was red with pus discharge.

Which of the following is the most appropriate management approach?

A. Withdraw blood culture and start IV antibiotics

B. Start IV antibiotics and hold dialysis for 3 days

C. Withdraw blood culture, change the line and resume dialysis

**D. Withdraw blood culture, start antibiotics and remove the line

A 64-year-old diabetic woman is receiving hemo-dialysis through a femoral central line. She develops line sepsis. Blood culture grows MRSA (methicillin resistant staphylococcus aureus). She was started on IV vancomycin 1000 mg every 72 hours (to be infused over 20 min). Immediately after starting vancomycin, she started to have flushing, redness and itching over the face, neck and trunk.

Which of the following is the most appropriate management approach?

A. Stop vancomycin and label her allergic to vancomycin

B. Continue vancomycin but a lower dose

**C. Continue vancomycin but slower infusion rate

D. Change vancomycin to cefazolin 1000 mg every 24 hours

UTI
Asymptomatic

A 38-year-old woman came for routine follow up 2-months after delivery. She has no symptoms and her baby is well and lactating normally. Upon reviewing her labs, a positive urine culture : >

100,000 cfu/ml E.coli was noticed which was sensitive to trimethoprim/sulfamethoxazole, ciprofloxacin, and nitrofurantoin.

Which of the following is the best treatment option?

A. Oral ciprofloxacin

B. Oral nitrofurantoin

C. Oral trimethoprim/sulfamethoxazole

**D. No treatment needed

UTI
Symptomatic

A 38-year-old woman, 28-weeks pregnant came for routine follow up. She has no symptoms and her pregnancy is all well. Upon reviewing her labs, a positive urine culture : > 100,000 cfu/ml E.coli was found which was sensitive to ciprofloxacin, nitrofurantoin, trimethoprim/sulfamethoxazole and ceftriaxone

Which of the following is the best treatment option?

A. Oral ciprofloxacin

**B. Oral nitrofurantoin

C. Oral trimethoprim/sulfamethoxazole

D. No treatment needed

UTI
Diabetic woman
Allergic to penicillin

A 45-year-old diabetic woman presented to Emergency Department with fever, flank pain and dysuria. She is allergic to penicillin. Examination shows flank tenderness (see lab result and report).

Temperature 39 °C

Test Result Normal Values
WBC 17 4.5-10.5 x 109/L

Urine culture:
> 100,000 cfu/ml E.coli.

Which of the following is absolutely contraindicated?

**A. Piperacillin tazobactam

B. Ciprofloxacin

C. Meropenem

D. Ceftriaxone

UTI
E.COLI
Empirical treatment

A 45-year-old woman presented to Emergency Department with fever, flank pain and dysuria (see lab result and report).

Rattafy

Test Result Normal Values
WBC 14 4.5-10.5 x 109/L

Urine culture:
> 100,000 cfu/ml E.coli

Which of the following is the best empirical treatment option?

A. Piperacillin tazobactam

B. Nitrofurantoin

C. Meropenem

**D. Ceftriaxone

UTI
Diabetic woman
E.coli

A 48-year-old diabetic woman presented to Emergency Department with dysuria (see lab result and report).

Test Result Normal Values
WBC 14 4.5-10.5 x 109/L
Creatinine 230 44-115 µmol/L

Urine culture:
> 100,000 cfu/ml E.coli

Which of the following medications is contraindicated?

**A. Nitrofurantoin

B. Ciprofloxacin

C. Piperacillin tazobactam

D. Trimethoprim / sulfamethoxazole

A 62-year-old man presented with 2-weeks history of tiredness, dyspnea and 5-days history of fever. No previous surgical history. Cardiac exam shows pan-systolic murmur at the apex. Hands exam shows splinter hemorrhage on nails.

Temperature 38.8 °C

Which of the following is the most likely causative organism?

A. Staphylococcus epidermidis

B. Enterococcus species

C. Klebsiella pneumoniae

**D. Streptococcus species

A 58-year-old man presented with 2-weeks history of tiredness, dyspnea and 5-days history of fever. No previous surgical history. Cardiac exam shows pan systolic murmur at the apex. Hands exam shows splinter hemorrhage on nails.

Temperature 38.5 °C

Which of the following is the most appropriate empirical therapy?

A. Ceftriaxone

B. Gentamicin

C. Piperacillin tazobactam

**D. Ceftriaxone and vancomycin

A 24-year-old woman is 10-weeks pregnant. She has dysuria and is diagnosed with a urinary tract infection.

Which of the following antibiotics is contraindicated?

A. Nitrofurantoin

**B. Ciprofloxacin

C. Amoxacillin

D. Ceftriaxone

ORTHO

SLE
ANA
Anti sm

A 22-year-old woman presented to the clinic with 2-months history of polyarthralgia, skin rash, mucosal ulcers and fatigue. Her clinical examinations revealed malar rash over her face and active arthritis at several joints (see lab results).

Test Result Normal Values
Hb 100 130-170 g/L (Male)
120-160 g/L (Female)
Platelets count 100 150-400 x 109/L
WBC 3 4.5-10.5 x 109/L
ESR 35 2-10 mm/h (Male)
3-15 mm/h (Female)
Lupus anticoagulant positive negative
Urea 5 2.75-7.4 mmol/L
Creatinine 78 44-115 µmol/L
C-reactive peptide 5 <8.2 mg/L
Complement C3 0.3 0.7-1.5 g/L
Complement C4 0.13 0.15-0.45 g/L

Which of the following test obtained at this visit is most likely to confirm the diagnosis?

A. Anti-Ro (SSA) antibodies

**B. Antinuclear antibodies (ANA)

C. Anti-double-stranded DNA (anti-DNA)

D. Anti- ribonucleoprotein (RNP) antibodies

* ANTI-Sm
* ANA
* anti-ds DNA

A 30-year-old woman presented to the clinic with polyarthralgia, malar rash and mucosal ulcerations for 2-months. Examination revealed active malar rash and arthritis affecting several

joints. She has positive anti-nuclear antibody with high titer (see lab results).

Test Result Normal Values
Hb 110 130-170 g/L (Male)
120-160 g/L (Female)
Platelets count 280 150-400 x 109/L
WBC 10 4.5-10.5 x 109/L
ESR 65 2-10 mm/h (Male)
3-15 mm/h (Female)
Urea 4 2.75-7.4 mmol/L
Creatinine 60 44-115 µmol/L
Appearance clear clear
Protein absent absent
Leukocytes 2 0-3 per high power field
Erythrocytes 0 0-2 per high power field
Complement C3 0.6 0.7-1.5 g/L
Complement C4 0.13 0.15-0.45 g/L
Alkaline phosphatase 50 39-117 IU/L
Alanine aminotransferase 18 5-40 IU/L
Aspartate aminotransferase 20 12-40 IU/L

Which of the following is the best treatment option at this time?

**A. Hydroxychloroquine and methotrexate

B. Hydroxychloroquine and azathioprine

C. Hydroxychloroquine and cyclophosphamide

D. Hydroxychloroquine and mycophenolate mofetil

SLE FLARE

A 30-year-old woman presented to the clinic with polyarthralgia, malar rash and mucosal ulcerations for 2-months. Examination revealed active malar rash and arthritis affecting several joints. She has positive anti-nuclear antibody with high titer (see lab results).

Test Result Normal Values
Hb 100 130-170 g/L (Male)
120-160 g/L (Female)
Platelets count 90 150-400 x 109/L
WBC 3.5 4.5-10.5 x 109/L
ESR 60 2-10 mm/h (Male)
3-15 mm/h (Female)
Urea 5 2.75-7.4 mmol/L
Creatinine 150 44-115 µmol/L
Protein 1200 0-150 mg/24 hr
Complement C3 0.4 0.7-1.5 g/L
Complement C4 0.1 0.15-0.45 g/L

Which of the following is the best high dose treatment option at this time?

**A. Steroid and mycophenolate mofetil

B. Steroid and hydroxychloroquine

C. Steroid and methotrexate

D. Steroid and cyclosporine

Rheumatoid Arthritis
Methoraxate

A 50-year-old man with active rheumatoid arthritis presented to the clinic complaining of polyarthralgia and significant early morning stiffness. His current treatments are methotrexate, prednisone and hydroxychloroquine.

Examination revealed active arthritis at several joints (see lab results).

Test Result Normal Values
Hb 160 130-170 g/L (Male)
120-160 g/L (Female)
Platelets count 500 150-400 x 109/L
WBC 10 4.5-10.5 x 109/L
ESR 80 2-10 mm/h (Male)
3-15 mm/h (Female)
Urea 5 2.75-7.4 mmol/L
Creatinine 75 44-115 µmol/L
C-reactive peptide 18 <8.2 mg/L
Rheumatoid factor 600 <58 kIU/L
Aspartate aminotransferase 37 12-40 IU/L
Alanine aminotransferase 35 5-40 IU/L
Albumin 50 34-56 g/L

- Sicca syndrome affects dry eyes, mouth, and other mucous membranes
- Felty syndrome causes RA, splenomegaly, and neutropenia.
- Caplan syndrome causes RA, pneumoconiosis, and lung nodules.

The most common cause of death in RA is coronary artery disease.

Which of the following is the most appropriate additional treatment option?

A. Azathioprine

**B. Adalimumab

C. Cyclosporine

D. Mycophenolate mofetil

Rx: Methoraxate (Check LFT's for toxicity if unresponsive or toxicity ↓ Adalimumab

Reactive Arthritis
NSAIDs
Sulphasalazine

A 38-year-old man presented to the clinic complaining of recurrent painful swelling affecting right knee and left ankle for 6-months despite using non-steroidal anti-inflammatory drugs. His past history revealed urinary tract infection 2-weeks prior to onset of his joint pain. On examination, he has active arthritis at right knee and left ankle (see lab results).

Test Result Normal Values
Hb 160 130-170 g/L (Male)
120-160 g/L (Female)
Platelets count 450 150-400 x 109/L
WBC 12 4.5-10.5 x 109/L
ESR 65 2-10 mm/h (Male)
3-15 mm/h (Female)
Urea 4 2.75-7.4 mmol/L
Creatinine 100 44-115 µmol/L
C-reactive peptide 20 <8.2 mg/L
Rheumatoid factor 13 <58 kIU/L
Color clear clear or light yellow
Protein absent absent
Nitrite absent absent
Leukocytes 2 0-3 per high power field

Reactive Arthritis (Reiter Syndrome)

Look for the triad of:

- Joint pain
- Ocular findings (uveitis, conjunctivitis)
- Genital abnormalities (urethritis, balanitis)

Rx:

NSAIDS

Sulfasalazine (if no response to NSAIDS)

Which of the following is the most appropriate treatment?

**A. Sulfasalazine

B. Methotrexate

C. Azithromycin

D. Cyclosporine

A 30-year-old woman with systemic lupus erythematosus is complaining of arthralgia and skin rash for 3 months. Examination revealed active arthritis at two small joints of right hand and malar rash over her face (see lab results).

Test Result Normal Values
Hb 110 130-170 g/L (Male)
120-160 g/L (Female)
Platelets count 190 150-400 x 109/L
WBC 6 4.5-10.5 x 109/L
ESR 35 2-10 mm/h (Male)
3-15 mm/h (Female)
Urea 5 2.75-7.4 mmol/L
Creatinine 65 44-115 µmol/L

Which of the following advice should be presented to the patient about hydroxychloroquine?

A. Interferes with mycophenolate mofetil

B. Should be stopped during pregnancy

C. Should be stopped during lactation

**D. Efficacy is reduced by smoking

Osteoarthritis

A 50-year-old woman presented to the clinic with polyarthralgia affecting distal and proximal interphalangeal joints bilaterally for 3-years. She does not have significant early morning stiffness. Clinical examination revealed no active arthritis but there was non-tender hard nodules over some distal interphalangeal (see lab results).

RA spares DIPJ
OA involves DIPJ

Test Result Normal Values
Hb 140 130-170 g/L (Male)
120-160 g/L (Female)
Platelets count 190 150-400 x 109/L
WBC 11 4.5-10.5 x 109/L
ESR 15 2-10 mm/h (Male)
3-15 mm/h (Female)
C-reactive peptide 5 <8.2 mg/L
Rheumatoid factor 30 <58 kIU/L
Urea 4 2.75-7.4 mmol/L
Creatinine 75 44-115 µmol/L

Bony nodes occurring on distal interphalangeal (DIP) joints in the hands are called "Heberden nodes," and the ones on the proximal interphalangeal (PIP) joints are referred to as "Bouchard nodes."

Which of the following is the most likely rheumatological disease?

A. Seronegative rheumatoid arthritis

**B. Hand osteoarthritis

C. Polyarticular gout

D. Reactive arthritis

A 53-year-old woman presented to the clinic with polyarthralgia affecting distal and proximal interphalangeal joints bilaterally for 3-years. She does not have significant early morning stiffness. Clinical examination revealed no active arthritis (see lab results).

Test Result Normal Values
Hb 140 130-170 g/L (Male)
120-160 g/L (Female)
Platelets count 200 150-400 x 109/L
WBC 8 4.5-10.5 x 109/L
ESR 12 2-10 mm/h (Male)
3-15 mm/h (Female)
Urea 4 2.75-7.4 mmol/L
Creatinine 75 44-115 µmol/L
C-reactive peptide 5 <8.2 mg/L

Which of the following is the best management option at this stage?

A. Methotrexate therapy

B. Surgical intervention

C. Weight loss

**D. Finger splints

A 65-year-old man presented to the clinic with 3-year history of progressive worsening of bilateral knee pain and stiffness that occurs at rest and at night. He has no history of trauma. Paracetamol and ibuprofen resulted in mild improvements of his joint pain. Upon examination, there is no warmth, erythema or effusion and there is no compromise in joints stability (see lab results).

Blood pressure 140/90 mmHg
Temperature 36.6 °C
Weight 90 kg
Height 160 cm

Test Result Normal Values
Hb 125 130-170 g/L (Male)
120-160 g/L (Female)
Platelets count 300 150-400 x 109/L
WBC 9 4.5-10.5 x 109/L
ESR 15 2-10 mm/h (Male)
3-15 mm/h (Female)
Blood urea nitrogen 9 2.8 to 8.9 mmol/L
Creatinine 115 44-115 µmol/L
C-reactive peptide 6 <8.2 mg/L

Which of the following is the most appropriate next investigation?

A. MRI of knee joints

B. Bone scintigraphy

C. Ultrasonography for knee joints

**D. Standing plain radiography of knee joints

NSAIDS

A 30-year-old man presented to the clinic with left knee pain for one month. 3 months ago, he had an episode of right knee active arthritis that was aspirated and then improved.

Synovial fluid aspiration showed leukocyte count 40,000/cu mm, and negative cultures. Clinical examination revealed a swollen and tender left knee only. He has not had rashes or eye symptoms. Knee radiographs are normal (see lab results).

Test Result Normal Values
Hb 140 130-170 g/L (Male)
120-160 g/L (Female)
Platelets count 450 150-400 x 109/L
WBC 10 4.5-10.5 x 109/L
ESR 55 2-10 mm/h (Male)
3-15 mm/h (Female)
Urea 4 2.75-7.4 mmol/L
Creatinine 85 44-115 µmol/L
C-reactive peptide 16 <8.2 mg/L
Rheumatoid factor 35 <58 kIU/L

Which of the following is the most appropriate initial treatment?

**A. Ibuprofen

B. Methotrexate

C. Infliximab

D. Amoxicillin

SLE
Pericarditis

A 23-year-old woman with systemic lupus erythematosus (SLE) presented to the clinic with a 3-month history of lower-extremity swelling and shortness of breath. She has not had chest pain, palpitations, or fevers. On physical examination, she has jugular venous distention and engorgement with inspiration. Heart sounds are distant; a prominent early diastolic sound without gallops or murmurs is heard. Breath sounds are normal. Abdominal examination reveals shifting dullness. Pitting edema to the level of the knees is noted (see lab results).

Blood pressure 110/70 mmHg
Heart rate 95 /min
Respiratory rate 25 /min
Temperature 36.6 °C
Oxygen saturation 90 %

Test Result Normal Values
Hb 90 130-170 g/L (Male)
120-160 g/L (Female)
Platelets count 450 150-400 x 109/L

WBC 3 4.5-10.5 x 109/L
Creatinine 150 44-115 µmol/L
Albumin 28 34-56 g/L
Complement C3 0.5 0.7-1.5 g/L
Complement C4 0.1 0.15-0.45 g/L
Aspartate aminotransferase 100 12-40 IU/L
Alanine aminotransferase 94 5-40 IU/L

Which of the following SLE association most likely explains the current condition?

**A. Constrictive pericarditis

B. Myocardial infarction

C. Liver failure

D. Renal failure

SLE Complications

A 30-year-old woman with systemic lupus erythematosus presented to Emergency Department with seizures and fatigue for 2-days. No history of fever or skin rash. Musculoskeletal and neurologic examinations are normal. She has negative septic workup. Brain MRI revealed multiple hyperintense lesions (see lab results).

Blood pressure 120/70 mmHg
Temperature 37.2 °C
Oxygen saturation 95 %

SLE Drugs

1. Nsaids (initially)
2. Steroids (complications)
   ± Cyclophosphamide / Mycophenolate
3. Hydroxychloroquine
   Mycophenolate

Test Result Normal Values
Hb 110 130-170 g/L (Male)
120-160 g/L (Female)
Platelets count 200 150-400 x 109/L
WBC 6 4.5-10.5 x 109/L
ESR 35 2-10 mm/h (Male)
3-15 mm/h (Female)
APTT 30 30-40 sec
INR 1 0.8-1.2
Lupus anticoagulant negative negative
Urea 6 2.75-7.4 mmol/L
Creatinine 100 44-115 µmol/L
Pressure 300 200-250 mmH2O (Male)
300-400 mmH2O (Female)
Cells 20 0-3 /µL
Total protein (Women) 0.65 0.15-0.45 g/L
Anti SS antibodies 35 negative
Complement C3 0.5 0.7-1.5 g/L
Complement C4 0.1 0.15-0.45 g/L

Which of the following is the most appropriate treatment in addition to corticosteroids?

**A. Cyclophosphamide

B. Azathioprine

C. Phenytoin

D. Heparin

A 50-year-old man presented to the clinic with a 15-year history of multiple joints pain with daily significant morning stiffness that lasts for 3 hours. He has been admitted 3 times during the last year to the local hospital for treatment of bacterial pneumonia. Physical examination reveals multiple rheumatoid nodules and an enlarged spleen. He has active arthritis affecting multiple metacarpophalangeal (MCP) and proximal interphalangeal (PIP) joints symmetrically. Hands x-ray show severe erosive disease of the MCP and PIP joints. Bone marrow aspiration and biopsy reveals an excess of immature forms and maturation arrest with normal differential (see lab results).

Feltys

- Sicca syndrome affects dry eyes, mouth, and other mucous membranes
- Felty syndrome causes RA, splenomegaly, and neutropenia.
- Caplan syndrome causes RA, pneumoconiosis, and lung nodules.

Test Result Normal Values
Hb 90 130-170 g/L (Male)
120-160 g/L (Female)
Platelets count 100 150-400 x 109/L
WBC 2 4.5-10.5 x 109/L
ESR 80 2-10 mm/h (Male)
3-15 mm/h (Female)
Rheumatoid factor 400 <58 kIU/L

Which of the following is the most likely diagnosis?

A. Systemic lupus erythematosus

**B. Feltys syndrome

C. Lymphoma

D. Tuberculosis

Reactive Arthritis

A 40-year-old man presented to Emergency Department with fever and painful swelling in the left knee for 2 days. 2 weeks ago, he had watery, non-bloody diarrhea and abdominal pain for 5-days after eating from a restaurant. On physical examination, left knee is warm and tender, with a moderate effusion. The right wrist is mildly swollen and tender. The left achilles tendon is mildly tender and swollen at its insertion into the calcaneus. Blood, stool and synovial cultures are negative. However, testing for Clostridium difficile toxin is positive (see lab results).

Blood pressure 140/90 mmHg
Heart rate 76 /min
Temperature 38.5 °C

Test Result Normal Values
ESR 75 2-10 mm/h (Male)
3-15 mm/h (Female)
WBC 18 4.5-10.5 x 109/L
Creatinine 110 44-115 µmol/L
Uric acid 260 200-410 µmol/L (Male)
140-360 µmol/L (Female)
C-reactive peptide 20 <8.2 mg/L
Rheumatoid factor 35 <58 kIU/L

Which of the following is the most likely arthritis?

A. Septic

B. Gonococcal

**C. Reactive

D. Peripheral associated with inflammatory bowel disease

SLE
Hydroxychloroquine
Ala Medicine

A 32-year-old woman smoker presented to the clinic with 6-months history of polyarthralgia, malar rash and fatigue. Examination revealed active malar rash over her face and lower limb pitting oedema up to the knees. She has positive antinuclear antibody with high titer (1:1280). She is started on hydroxychloroquine and mycophenolate mofetil (see lab results).

Test Result Normal Values
Hb 110 130-170 g/L (Male)
120-160 g/L (Female)
Platelets count 200 150-400 x 109/L
WBC 3.5 4.5-10.5 x 109/L
ESR 45 2-10 mm/h (Male)
3-15 mm/h (Female)
Urea 5 2.75-7.4 mmol/L
Creatinine 75 44-115 µmol/L
24 hr urine protein 750 0.8-14 mg/dl (Male)
2.5-11 mg/dl (Female)
Complement C3 0.4 0.7-1.5 g/L
Complement C4 0.1 0.15-0.45 g/L

Which of the following non-pharmacological intervention would be most important at this time?

A. Weight loss

**B. Smoking cessation

C. Low protein diet

D. Reduce physical activities

* Smoking reduce efficacy of Hydroxychloroquine.

SLE
Anemia

A 27-year-old man with systemic lupus erythematosus (SLE) is seen in the clinic because of worsening fatigue and exertional shortness of breath. He has had no fevers, arthritis, ulcers, rash, chest pain or palpitations. His current treatments are hydroxychloroquine and mycophenolate mofetil. Systemic examination is unremarkable (see lab results).

Blood pressure 130/70 mmHg
Respiratory rate 18 /min
Temperature 37.3 °C

Test Result Normal Values
Hb 78 130-170 g/L (Male)
120-160 g/L (Female)
Reticulocyte 7 0.2-1.2 %
Platelets count 300 150-400 x 109/L
WBC 6 4.5-10.5 x 109/L
Creatinine 85 44-115 µmol/L
Haptoglobin 0.2 0.9-1.4 g/L
Iron 11 11.7-31.8 µmol/L (Male)

9-30.4 µmol/L (Female)
Ferritin 500 20-300 µg/L (Male)
20-120 µg/L (Female)
Lactate dehydrogenase 1200 60-160 IU/L

Which of the following anemias is most likely associated with SLE at this stage?

A. Anaemia of chronic disease

B. Iron deficiency

**C. Haemolytic

D. Pernicious

A 55-year-old man with rheumatoid arthritis for 6-years on methotrexate 15 mg weekly and prednisone 5 mg daily presented to the Emergency Department with a 2-day history of left knee pain and swelling. On examination, left knee is swollen, red, warm and tender. Left knee aspiration revealed high white blood cells 35000 cells/mm and the culture is pending (see lab results).

Blood pressure 105/70 mmHg
Heart rate 96 /min
Temperature 39 °C
Oxygen saturation 97 %

Test Result Normal Values
Hb 125 130-170 g/L (Male)
120-160 g/L (Female)
Platelets count 450 150-400 x 109/L
WBC 18 4.5-10.5 x 109/L
ESR 80 2-10 mm/h (Male)
3-15 mm/h (Female)
C-reactive peptide 28 <8.2 mg/L
Rheumatoid factor 600 <58 kIU/L

Which of the following is the most appropriate immediate management?

**A. Intravenous antibiotics

B. Intravenous high dose steroids

C. Intra-articular steroid injection

D. Oral non-steroidal anti-inflammatory drugs

A 65-year-old-woman presented to the clinic with a 5-day history of pain and swelling in the left knee. Her pain aggravated by walking and relieved by rest. No history of small joints involvement or significant morning stiffness.

On examination, left knee is swollen but not warm or erythematous. Left knee X-ray shows osteophytes and joint space narrowing. Joint aspiration reveals 280 leukocytes/mm (see lab results).

Blood pressure 140/80 mmHg
Temperature 36.6 °C
BMI 35 kg/m2

Test Result Normal Values
Hb 125 130-170 g/L (Male)
120-160 g/L (Female)
Platelets count 300 150-400 x 109/L
WBC 11.5 4.5-10.5 x 109/L
ESR 8 2-10 mm/h (Male)
3-15 mm/h (Female)

Which of the following is the most likely arthritis?

**A. Osteoarthritis

B. Rheumatoid

C. Gouty

D. Septic

A 35-year-old man with rheumatoid arthritis for 6 months on methotrexate 20 mg weekly and ibuprofen daily presented to the clinic with increasing joint pain in both hands and feet associated with morning stiffness for 2-hours. On examination, he shows signs of active arthritis at both wrists. Hand X-rays show erosions at multiple joints (see lab results).

Test Result Normal Values
Hb 120 130-170 g/L (Male)
120-160 g/L (Female)
Platelets count 450 150-400 x 109/L
WBC 8 4.5-10.5 x 109/L
ESR 60 2-10 mm/h (Male)
3-15 mm/h (Female)
C-reactive peptide 18 <8.2 mg/L
Rheumatoid factor 500 <58 kIU/L

Which of the following is the most appropriate additional treatment?

**A. Adalimumab

B. Azathioprine

C. Cyclophosphamide

D. Hydroxychloroquine

A 28-year-old woman presented to the clinic with 2-month history of pain and swelling in the hand joints with morning stiffness for 2-hours. She is 3-months postpartum, and taking care of her infant. On examination, she has active arthritis at second and fourth proximal and metacarpophalangeal joints and both wrists (see lab results).

Test Result Normal Values
Hb 120 130-170 g/L (Male)

120-160 g/L (Female)
Platelets count 450 150-400 x 109/L
WBC 6 4.5-10.5 x 109/L
ESR 70 2-10 mm/h (Male)
3-15 mm/h (Female)
C-reactive peptide 18 <8.2 mg/L

Which of the following is the most likely diagnosis?

A. Viral arthritis

B. Reactive arthritis

C. Polyarticular gout

**D. Rheumatoid arthritis

A 75-year-old man presented to the clinic with a 5-year history of right knee pain that worsens with walking and is relieved with rest. Paracetamol 1 gm 3 times a day resulted in mild improvements. He also has hypertension, diabetes mellitus and chronic kidney diseases. On examination, his right knee is mildly swollen but not tender or warm with significant limitation of his flexion movements. Right knee radiography shows osteophytes and significant joint space narrowing (see lab results).

Test Result Normal Values
ESR 8 2-10 mm/h (Male)
3-15 mm/h (Female)
Urea 8.5 2.75-7.4 mmol/L
Creatinine 190 44-115 µmol/L

Which of the following is the most appropriate treatment?

A. Celecoxib

B. Ibuprofen

**C. Tramadol

D. Prednisone

Rheumatoid Arthritis Treatment

A 30-year-old woman presented to the clinic with 4-month history of multiple joint pain and morning stiffness for 2-hours. On examination, she has active arthritis at multiple small joints of both hands and feet. Hands radiography show erosions at several small joints of both hands (see lab results).

Test Result Normal Values
Hb 110 130-170 g/L (Male)
120-160 g/L (Female)
Platelets count 450 150-400 x 109/L
WBC 10 4.5-10.5 x 109/L
ESR 65 2-10 mm/h (Male)
3-15 mm/h (Female)
Urea 4 2.75-7.4 mmol/L
Creatinine 67 44-115 µmol/L
C-reactive peptide 25 <8.2 mg/L

Rheumatoid factor 450 <58 kIU/L

Which of the following is the most appropriate management?

A. Prednisone 60 mg daily

B. Hydroxychloroquine 400 mg daily

C. Indomethacin, 25 mg three times daily

**D. Hydroxychloroquine 400 mg daily and methotrexate 15 mg weekly

A 28-year-old man with systemic lupus erythematosus presented to the clinic with a 1-month history of joint pain and morning stiffness. He has no current history of skin rash or other systemic features. His current treatment consists of hydroxychloroquine 400 mg daily. On examination, he has active arthritis at both wrist joints and second proximal interphalengeal joint of both hands (see lab results).

Test Result Normal Values
Hb 125 130-170 g/L (Male)
120-160 g/L (Female)
Platelets count 220 150-400 x 109/L
WBC 5 4.5-10.5 x 109/L
ESR 55 2-10 mm/h (Male)
3-15 mm/h (Female)
Urea 4.5 2.75-7.4 mmol/L
Creatinine 78 44-115 µmol/L
C-reactive peptide 12 <8.2 mg/L
Complement C3 0.9 0.7-1.5 g/L
Complement C4 0.1 0.15-0.45 g/L

Which of the following agents should be added to control the arthritis?

**A. Methotrexate

B. Sulfasalazine

C. Azathioprine

D. Cyclosporine

CNS

A 67-year-old man comes to the clinic complaining that he has a tremor in the right hand. It is best displayed when he reaches for a pen and is manifested easily in the finger-to-nose test.

In which of the following locations is the lesion?

Intention Tremors → Cerebellum

A. Left basal ganglia

**B. Right cerebellum

C. Left motor cortex

D. Left cerebellum

Parkinson Tremor

A 72-year-old woman with Parkinson's disease, complaining of a very annoying tremor of the

dominant right hand. She is not on any medication. She states that her tremor is the only feature that disturbs her functioning.

Which of the medications would be most likely to improve her tremor?

**A. Procyclidine

B. Amitriptyline

C. Bromocriptine

D. Carbidopa/levodopa

A 69-year-old man comes to the clinic complaining of increasing fatigue and drowsiness and difficulty to arouse. History reveals he was in a vacation 2 weeks ago. Although he admits to taking several falls, he is unaware of any head injury. Neurological examination showed no lateralizing or focal findings. Head and scalp examinations are negative for focal tenderness and deformity. Plain X-ray of the skull is negative (see lab results).

Test Result Normal Values
RBC 5.1 4.7-6.1 x 1012/L (Male)
4.2-5.4 x 1012/L (Female)
Hb 132 130-170 g/L (Male)
120-160 g/L (Female)
HCT 0.40 0.42-0.52 (Male)
0.37-0.48 (Female)
MCH 30 28-33 pg/cell
MCHC 322 320-360 g/L
MCV 88 80-95 fl
Reticulocyte 0.9 0.2-1.2 %
Platelets count 200 150-400 x 109/L
WBC 5.5 4.5-10.5 x 109/L
Neutrophils 50 40-60%
Eosinophils 2 1-4 %
Basophils 0.8 0.5-1 %
Lymphocytes 32 20-40 %
Monocytes 4.1 2-8 %
Calcium 2.3 2.15-2.62 mmol/L
Calcium ionized 1.2 1.1-1.3 mmol/L
Magnesium 0.8 0.7-1.2 mmol/L
Thyroid-Stimulating Hormone 4.4 0.4 - 5.0 µU/mL
Thyroxine (T4 free serum) 12 8.5 - 15.2 pmol/L
Sodium 136 134-146 mmol/L
Potassium 4.2 3.5-5.1 mmol/L

Which of the following is the most likely diagnosis?

A. Stroke

B. Acute bacterial meningitis

C. Post-concussion syndrome

**D. Chronic sub-dural hematoma

A 73-year-old diabetic man presents with right-sided weakness. The weakness is equal in the

right face, arm and leg. Sensation, speech and comprehension are intact.

Which of the following arteries is affected?

MCA - UL weakness > LL weakness

ACA - LL weakness > UL weakness

A. Vertebral artery

B. Mid-basilar artery

C. Anterior cerebral artery

**D. Penetrating branch, middle cerebral artery

A 70-year-old man complains of a sudden severe headache while bending down to pick up his keys this morning. He describes it as the worst headache he has ever had; he says it was like being hit on the back of the neck.

Which of the following is the most likely diagnosis?

A. Meningitis

B. Cluster headache

C. Tension headache

**D. Sub-arachnoid hemorrhage

A 48-year-old woman has a 2-year history of a slowly progressive bilateral tremor. The tremor interferes with her writing and eating. She has recently noted head bobbing and a change in her voice.

Which of the following would be an appropriate first-line medication for her problem?

A. Carbidopa/levodopa

B. Alprazolam

**C. Propranolol

D. Olanzapine

A 45-year-old man presents with a sudden onset of unilateral peripheral facial nerve weakness 1 hour ago. He has no medical illness and not on any medication.

Which of the following is most likely to shorten his symptoms?

A. Antiviral therapy

B. Thrombolytic therapy

**C. Corticosteroid therapy

D. Hyperbaric oxygen therapy

A 36-year-old woman presented with 2-year history of recurrent headaches. These headaches occur 3 to 4 times per month and last 12 to 24 hours. The headaches are usually located over the right or left frontal sinuses. This particular headache has lasted 2 days now, and she has some nausea associated with it. The patient has been using an over-the counter analgesic-

decongestant combination without significant relief. Neurological examination is within normal limits. The optic fundi are normal.

Blood pressure 110/70 mmHg
Heart rate 76 /min
Temperature 36.6 °C

What is the appropriate next step to determine the etiology of this headache?

A. MRI scan of the brain

B. CT scan of the paranasal sinuses

C. Erythrocyte sedimentation rate

**D. Careful history and physical examination

GIT

Giardiasis

A 31-year-old man complains of persistent watery diarrhoea and has noticed some weight loss. He returned 5 weeks ago from Egypt. He submits a stool sample that came back negative.

Which of the following is the most likely diagnosis?

**A. Giardiasis

B. Shigellosis

C. Amoebiasis

D. Ulcerative colitis

A 62-year-old woman presents with dysphagia. Her symptoms were first noticed a few months ago and have steadily worsened. Initially she had difficulty swallowing solids but over recent weeks has also been having difficulty swallowing liquids. She lost 5 Kg over 5 weeks. On examination, she looks thin and slightly pale.

Which of the following is the most likely diagnosis?

A. Achalasia

B. Pharyngeal pouch

**C. Oesophageal cancer

D. Gastro-oesophageal reflux disease

A 24-year-old woman is diagnosed with celiac disease.

Which of the following foods should she avoid?

- Wheat
- Barley
- Cereals

A. Rice

**B. Barley

C. Maize

D. Potatoes

A 40-year-old woman brought to Emergency Room with severe colicky right upper quadrant pain. The pain started after eating fish and chips for lunch. By the time she is seen, an hour later, the pain has settled and she is otherwise asymptomatic. Clinical examination is unremarkable.

Which of the following is the most likely cause of her symptoms?

A. Acute cholecystitis

B. Gastroenteritis

C. Renal colic

**D. Biliary colic

A 21-year-old woman presents with a 3-months history of upper abdominal pain. The discomfort and bloating becomes worse by eating. There is no diarrhea or constipation and her appetite is good. Clinical examination of her abdomen is normal. Helicobacter test is negative and other blood tests are all normal.

Which of the following is the most likely diagnosis?

A. Irritable bowel syndrome

**B. Functional dyspepsia

C. Celiac disease

D. Crohn's disease

A 25-year-old woman presented with episodic abdominal pain and altered bowel habits that have been present intermittently for the past year. The pain is "crampy," and moderate to severe. Defecation brings some relief, but she sometimes must pass several loose, watery stools before the pain resolves. She occasionally notes mucus in her stool and sometimes feels that evacuation is incomplete even though she is unable to pass more stool. Her body weight is stable. Abdominal examination are normal.

Which of the following is the most appropriate test to establish diagnosis?

A. Helicobacter pylori test

**B. Celiac disease testing

C. Thyroid function test

D. CT abdomen

Bloody diarrhoea
Antibiotic

A 42-year-old man with no medical problems presents with a 2-day history of profuse bloody diarrhea, severe abdominal cramping and fever. He has recently returned from a week-long trip to Indonesia. His stool culture is positive for Campylobacter.

Which of the following is the most appropriate treatment?

A. Metronidazole

B. Ciprofloxacin

Rx: Erythromycin
Azithromycin

**C. Azithromycin

D. Amoxicillin

A 34-year-old woman presents with a 4-week history of retrosternal burning pain. The pain is often worse following eating. Her past medical history includes depression and she is on escitalopram 10 mg OD. Clinical examination is unremarkable.

Which of the following is the most likely diagnosis?

A. Pericarditis

B. Pneumothorax

C. Myocardial infarction

**D. Gastro-oesophageal reflux disease

Tender red nodules

A 38-year-old woman with a history of chronic abdominal pain and diarrhea develops tender red nodules on her shins.

The findings are most consistent with which of the following?

A. Celiac disease

**B. Crohn's disease

C. Diverticular disease

D. Irritable bowel syndrome

Crohns family history

A 38-year-old woman presented with a 7-weeks of frequent, loose and bloody bowel movements that associated with campy abdominal and rectal pain. She has family history of crohn's disease. Stool analysis is negative (see lab results).

Blood pressure 110/70 mmHg
Heart rate 76 /min
Temperature 36.6 °C

Test Result Normal Values
RBC 9.2 4.7-6.1 x 1012/L (Male)
4.2-5.4 x 1012/L (Female)
Hb 111 130-170 g/L (Male)
120-160 g/L (Female)
HCT 0.41 0.42-0.52 (Male)
0.37-0.48 (Female)
MCH 27 28-33 pg/cell
MCHC 330 320-360 g/L
MCV 77 80-95 fl
Platelets count 220 150-400 x 109/L
C-reactive peptide 22 <8.2 mg/L

Which of the following is the most appropriate next step in establishing diagnosis?

A. Anorectal manometry

**B. Upper GI endoscopy

C. Celiac disease testing

D. Measurement of fecal calprotectin

A 28-year-old man with 4-months history of non-specific crampy abdominal pain and diarrhea alternate with constipation that is not related to any specific food. He has no history of food allergy. No history of weight loss.

Blood pressure 110/70 mmHg
Heart rate 76 /min
Temperature 36.6 °C
BMI 23 kg/m2

Which of the following is the most likely diagnosis?

**A. Irritable bowel syndrome

B. Lactose intolerance

C. Colonic cancer

D. Crohn's disease

Hepatitis Serology

A 34-year-old man previously healthy brought a laboratory results for hepatitis B virus from a private clinic (see lab results).

Test Result
HBsAg Negative
HBeAg Negative
Anti- HBsAg Positive
Anti-HBc IgG Negative

	Surface antigen	A-antigen	Core antibody	Surface antibody
Acute or chronic infection	Positive	Positive	Positive IgM or IgG	Negative
Resolved, old, past infection / Immune due to Natural infect.	Negative	Negative	Positive IgG	Positive
Vaccination	Negative	Negative	Negative	Positive
"Window period"	Negative	Negative	Positive IgM, then IgG	Negative

Serologic Patterns in Hepatitis B

What is the clinical state the laboratory results indicate?

A. Previous Hepatitis B infection

B. Acute Hepatitis B infection

C. Chronic Hepatitis B infection

**D. Previous hepatitis B immunization

A 31-year-old woman presented to the Emergency Room with mild acute cholecystitis. She was started on intravenous fluids and empiric antibiotics.

Which of the following is the most appropriate next step?

A. Endoscopic retrograde cholangiopancreatography

**B. Laparoscopic cholecystectomy within 72 hours

C. Cholecystectomy after 3 months

D. No more intervention needed

A 34-year woman presented with recurrent biliary colic for 5 months. Liver function test is within normal limits. Liver ultrasound shows cholelithiasis.

Which of the following procedures is the most appropriate?

**A. Cholecystectomy

B. Upper GI endoscopy

C. Gall bladder lithotripsy

D. Endoscopic retrograde cholangiopancreatography

Gilbert

A 29-year-old man presented with painless jaundice after resolution of upper respiratory tract viral infection, otherwise he is asymptomatic. Clinical abdominal examination is unremarkable. Peripheral blood smear is normal (see lab results).

Test Result Normal Values
RBC 5.1 4.7-6.1 x 1012/L (Male)
4.2-5.4 x 1012/L (Female)
Hb 133 130-170 g/L (Male)
120-160 g/L (Female)
MCV 88 80-95 fl
Reticulocyte 0.21 0.2-1.2 %
Platelets count 220 150-400 x 109/L
WBC 5.2 4.5-10.5 x 109/L
Alkaline phosphatase
41 39-117 IU/L
Alanine aminotransferase 12 5-40 IU/L
Aspartate aminotransferase 20 12-40 IU/L
↑ Indirect bilirubin 18 3.2-12.1 µmol/L
Direct bilirubin 1.51 1.5-6.5 µmol/L
Total bilirubin 19.51 3.5-16.5 µmol/L
HCT 0.44 0.42-0.52 (Male)
0.37-0.48 (Female)

Gilbert syndrome is characterized by recurrent episodes of jaundice, o

Mutated Gene

(UGT1A1), which is responsible for the conjugation of bilirubin with glucuronic acid.

The most likely diagnosis is Gilbert syndrome, an autosomal recessive disorder of bilirubin glucuronidation caused by ↓ activity of the enzyme glucuronyl transferase. Patients present with unconjugated hyperbilirubinemia but have a normal CBC, blood smear, and LFTs. The condition is benign, and no treatment is indicated.

Impaired conjugation of bilirubin	Gilbert syndrome Crigler-Najjar syndrome Newborn physiologic jaundice	↑ unconjugated bilirubin
Impaired bilirubin uptake and secretion from the liver	Dubin-Johnson syndrome Rotor syndrome	↑ conjugated bilirubin

Which of the following is the most likely cause of his jaundice?

A. Hemolytic anemia

B. Fatty liver disease

**C. Gilbert syndrome

D. Common bile duct obstruction

A 39-year-old man with asymptomatic hereditary hemochromatosis presented to the clinic for a check-up (see lab results).

Test Result Normal Values
Alkaline phosphatase
42 39-117 IU/L

Alanine aminotransferase 20 5-40 IU/L
Aspartate aminotransferase 22 12-40 IU/L
Ferritin 860 20-300 µg/L (Male)
20-120 µg/L (Female)

Which of the following is the most appropriate management?

A. Give penicillamine

B. Referral to upper GI endoscopy

C. Repeat the serum ferritin after 6 month

**D. Initiate regular therapeutic phlebotomy

A 52-year-old man develops sudden severe retrosternal chest pain that radiates to his back. Within minutes, he became unconscious. He is a heavy smoker and has history of hypertension.

Blood pressure 85/56 mmHg
Heart rate 92 /min

Aortic dissection occurs when a tear in the intima of the aorta creates a false lumen. This weak spot extends with each beat, extending the tear.

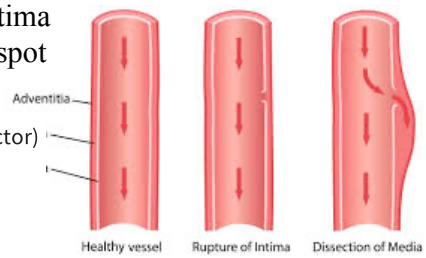

- Hypertension (main risk factor)
- Age >40
- Marfan syndrome

Which of the following is the most likely diagnosis?

A. Vasovagal attacks

B. Pulmonary embolism

**C. Tear in the aortic intima

D. Acute myocardial infarction

sudden onset of tearing chest pain that radiates to the back,

Difference in BP between the arms

CXR (initial)
CTPA (Most accurate)

Rx: β blockers * Nitroprusside Surgery

HOCM

A 23-year-old man is brought to the hospital after an episode of collapse. He states that on a few occasions while playing football he has had some chest pain, breathlessness and felt as he was going to faint. Last night during training, he collapsed and blacked out for a few seconds. Clinical examination revealed a harsh ejection systolic murmur with a palpable systolic thrill at the left sternal edge; and a prominent jerky carotid pulse.

Which of the following is the most likely diagnosis?

**A. Hypertrophic obstructive cardiomyopathy

B. Wolff-parkinson-white syndrome

C. Brugada syndrome

D. Long QT syndrome

A 68-year-old man is seen for a follow-up. He has longstanding breathlessness and symptoms of cardiac failure. The ECG confirmed a diagnosis of heart failure due to left ventricular dysfunction. His currently on enalopril 10 mg OD, simvastatin 40 mg OD, furosemide 40 mg OD and omeprazole 20 mg OD. Examination revealed that the chest is clear and heart sounds are normal. There is no peripheral edema.

Blood pressure 125/83 mmHg
Heart rate 76 /min

Which of the following is the most appropriate next step in the management at this stage?

A. Add in digoxin

B. Add in losartan

**C. Add in bisoprolol

D. No additional medication indicated

A 78-year-old man diagnosed with heart failure due to left ventricular dysfunction. His currently on aspirin 75 mg OD, simvastatin 40 mg OD and furosemide 40 mg OD. On examination, heart sounds are normal, his chest is clear and there is no peripheral oedema.

Which of the following is the most appropriate drug therapy to initiate at this stage?

A. Digoxin

**B. Enalopril

C. Hydralazine

D. Spironolactone

Smoking

A 55-year-old man presents with a 3-month history of exertional chest pain. He has previous history of myocardial infarction.

Which of the following is modifiable risk factors in the treatment of ischemic heart disease?

A. Family history

**B. Smoking

C. Gender

D. BMI

A 78-year-old woman presents with exertional syncope. On clinical examination, she has a slow rising carotid pulse and a loud ejection systolic murmur at the upper right sternal edge, radiating to the carotids.

Which of the following is the most likely cause of these findings?

A. Mitral stenosis

**B. Aortic stenosis

C. Mitral valve prolapse

D. Tricuspid regurgitation

A 43-year-old healthy man concerned about heart disease.

Which of the following is the most important risk factor of ischemic heart disease?

A. BMI of 31.2 kg/m2

B. Waist circumference of 103 cm

C. Blood pressure of 132/82 mmHg

**D. 2 separate fasting plasma glucose of 8.2 and 8.3 mmol/L

A 72-year-old man presented with an episode of right-sided weakness that lasted 10 minutes and fully resolved and he is clinical stable. He has no other medical illness. On clinical examination, he is in atrial fibrillation.

Blood pressure 110/70 mmHg
Heart rate 95 /min
Temperature 36.6 °C

Which of the following is the most appropriate next step in the management?

A. Aspirin

B. Warfarin, INR range 3-4

**C. Warfarin, INR range 2-3

D. No additional drug treatment

MI
Beta Blocker

A 58-year-old man comes to the clinic for a follow-up. He has been discharged after an acute inferior myocardial infarction. He is diabetic type 2, on metformin 1g BD, aspirin 75 mg, atorvastatin 10 mg OD and lisinopril 10 mg OD . Examination revealed bilateral basal crackles on auscultation of the chest.

Blood pressure 148/88 mmHg
Heart rate 76 /min
BMI 24 kg/m2

Which of the following is the most appropriate medication to add to his regime?

**A. Bisoprolol

B. Amlodipine

C. Losartan

D. Warfarin

Thyroid Storm
Atrial Fib

A 61-year-old woman comes to the clinic complaining of palpitations. She has also noticed some weight loss over the last 2 months. On clinical examination, she has an irregularly irregular pulse and a fine tremor. Her ECG shows atrial fibrillation.

Which of the following is the next most appropriate investigation to do?

A. Carotid Ultrasound

**B. Thyroid function tests

C. Exercise tolerance test

D. 24 hours ECG monitoring

A 66-year-old man comes for follow-up. He has shortness of breath on exercise, which have increased over the past few months. He became unable to walk more than 200-300 meters on the corridor and cannot climb the stairs easily. He has history of hypertension and currently on amlodipine 5 mg OD and indapamide 2.5 mg OD. On examination, he has bilateral basal crackles and mild pitting ankle edema (see lab results).

Blood pressure 188/96 mmHg
Heart rate 79 /min

Test Result Normal Values
Hb 133 130-170 g/L (Male)
120-160 g/L (Female)
Sodium 138 134-146 mmol/L
Potassium 4.2 3.5-5.1 mmol/L
Creatinine 133 44-115 µmol/L

Which of the following is the most appropriate next therapy?

A. Spironolactone

B. Furosemide

C. Bisoprolol

**D. Lisinopril

Murmur

A 66-year-old man presents with a diastolic murmur best heard at the left sternal edge. On examination, the apex beat is displaced outwards.

Which condition typically presents with these findings?

A. Coarctation of the aorta

**B. Aortic regurgitation

C. Mitral regurgitation

D. Aortic stenosis

Agents to Reverse Anticoagulation

- Andexanet alfa reverses rivaroxaban, apixaban, and edoxaban.
- Idarucizumab reverses dabigatran.
- Prothrombin complex concentrate (PCC) reverses warfarin.

CHAD

A 64-year-old man is diagnosed with persistent atrial fibrillation. His past medical history includes hypertension and type 2 diabetes. He has no contraindications to any antithrombotic treatments.

What antithrombotic treatment should be considered first line for this patient?

A. Aspirin and Clopidogrel

B. Clopidogrel

**C. Warfarin

ANTI COAG. → CHAD ≤ 1 Aspirin

ANTI COAG. → CHAD ≥ 2 NOAC or Warfarin

KEY FACT

The **CHA_2DS_2-VASc** scoring system can estimate stroke risk in AF. Score of ≥2 in men or ≥3 in women: Recommend anticoagulation with a direct oral anticoagulant or warfarin. Anticoagulation may be considered at a lower score (1 in men, 2 in women):

- **C**HF (1 point)
- **H**TN (1 point)
- **A**ge ≥75 (2 points)
- **D**iabetes (1 point)
- **S**troke or TIA history (2 points)
- **V**ascular disease (1 point)
- **A**ge 65–74 (1 point)
- **S**ex **c**ategory (female) (1 point)

D. Aspirin

Anti coagulation
Anti thrombotic

A 77-year-old woman comes to the clinic for a check-up. She has an irregular pulse when the nurse checked her vitals. An ECG has confirmed persistent atrial fibrillation .She is completely asymptomatic. She has a past medical history of migraine and asthma and on salbutamol PRN for asthma and PRN ibuprofen for her migraines. Other clinical examination is normal.

Blood pressure 138/85 mmHg
Heart rate 88 /min

What antithrombotic treatment should be considered first line in this patient?

A. Aspirin

B. Clopidogrel

C. Aspirin and dipyridamole

**D. Oral anticoagulation

ABPI

A 63-year-old smoker man presents with pain in his left leg, which is exacerbated by exercise and relieved by rest. Examination revealed weak pulses in the left leg compared to the right. The ankle brachial pressure Index is 0.84.

Which of the following is the most likely diagnosis?

A. Peripheral arterial disease with critical ischaemia

B. Normal peripheral arterial disease

**C. Peripheral arterial disease

D. Incompressible vessels

ABPI

> 1.2 Non compressible, Calcified

> 1 Normal

< 0.9 Arterial Occlusion

0.5 – 0.9 Intermittend Claudication (Mild to Mod. Ischemia)

< 0.5 Critical limb Ischemia

< 0.3 Necrosis Gangrene

Referral

A 62-year-old man presents with a 3-month history of epigastric pain after eating and intermittent heartburn between meals. He has lost weight but does not have any nausea or vomiting. He has not noticed any change in bowel habit and has not passed any blood or melena stools. He has no past medical history. He quit smoking 2 years ago.

What is the most appropriate management strategy?

A. Routine ultrasound of the abdomen

**B. Urgent referral for upper GI endoscopy

C. An oral proton pump inhibitor for 4 weeks

D. Blood testing for helicobacter pylori infection

A 29-year-old man is seen in the pre-employment clinic for routine exam. He is asymptomatic. Physical examination revealed a systolic murmur that heard at the apex. The murmur is augmented with sustained handgrip and reduced with Valsalva manoeuvre.

Which of the following is the most likely cause for this murmur?

**A. Mitral regurgitation

B. Aortic regurgitation

C. Mitral stenosis

D. Aortic stenosis

Endoscopy

A 38-year-old man presents to the clinic complaining of severe epigastric pain that is worse after eating. He describes the pain as burning in nature with mild improvement with antacid therapy. Physical examination is unremarkable (see lab results).

Test Result Normal Values
Hb 120 130-170 g/L (Male)
120-160 g/L (Female)
Platelets count 450 150-400 x 109/L
WBC 10 4.5-10.5 x 109/L
Urea 8.5 2.75-7.4 mmol/L
Creatinine 65 44-115 µmol/L

What is the most appropriate test to establish the diagnosis?

A. CT scan of the abdomen

**B. upper endoscopy

C. Barium swallow

D. H. pylori antibody

Crohns
Smoking

A 29-year-old man who is smoker for 5 years had appendectomy 2 years ago. He came to the clinic to discuss with you his risk to develop Crohn's disease because his brother has Crohn's disease that difficult to be controlled.

Which of the following increase the risk for the development of Crohn's disease?

A. Being male

**B. Cigarette smoking

C. No known risk factors

D. History of appendectomy

Abdominal pain
Hematocrit
Pancreatitis

A 30-year-old woman presents to the Emergency Department with 2-days history of severe abdominal pain that radiated to the back, which is associated with nausea and vomiting. On examination, she has normal vital signs with tender epigastrium but without rebound (see lab results).

Test Result Normal Values
Platelets count 450 150-400 x 109/L
WBC 14 4.5-10.5 x 109/L
Alanine aminotransferase 80 5-40 IU/L
Aspartate aminotransferase 65 12-40 IU/L
Amylase 800 24-151 IU/L
Lipase 750 0-160 IU/L
HCT 49 0.42-0.52 (Male)

0.37-0.48 (Female)

Which of the following predict a poor prognosis for this patient?

**A. Hematocrit > 44%

B. Lipase > 500 IU/L

C. Amylase > 600 IU/L

D. Albumin > 3.5 g/dl

IBS

A 30-year-old man with 3 years history of intermittent abdominal pain, bloating and diarrhoea is seen in the clinic.

Which of the following complains is highly suggestive of irritable bowel syndrome?

**A. Diarrhoea that alternate with constipation

B. Undiagnosed food particles in the stool

C. Blood streak mixed with stool

D. Diarrhoea at night

A 35-year-old woman with rheumatoid arthritis who maintained on methotrexate 15 mg weekly. She is currently on remission. 4 months ago, her liver function tests were normal but the most recent liver function tests are shown (see lab results).

Test Result Normal Values
Aspartate aminotransferase 300 12-40 IU/L
Alanine aminotransferase 280 5-40 IU/L
Albumin 30 34-56 g/L

What is the most appropriate action to be done for her abnormal liver function tests?

A. Do ultrasound for the liver

B. Start glucocorticoids

**C. Stop methotrexate

D. Order liver biopsy

Hepatocellular

A 55-year-old man with chronic hepatitis C present to the clinic for regular follow-up. His examination reveals a palpable right upper quadrant mass. CT scan of his abdomen shows a large 6*6 cm mass in the right lobe of the liver. A mass biopsy confirms the diagnosis of hepatocellular carcinoma.

What is the most appropriate management steps at this stage?

A. Start chemotherapy

B. Start radiotherapy

C. Referral for palliative medicine

**D. Referral for surgical resection

Hepatitis Serology

A 30-year-old asymptomatic woman presents to the clinic as pre-employment screening. Her examinations are unremarkable. Her laboratory tests revealed, positive HbsAg, anti-HBc (IgG) and anti-HBe but negative anti-HBs and HBeAg.

Which of the following statements is the most accurate?

A. She has acute hepatitis B

**B. She has chronic hepatitis B

C. She has received hepatitis B vaccine

D. She has been exposed to hepatitis B but now in recovery period

Aortic stenosis

A 65-year-old man presents to the clinic with progressive exertional shortness of breath that associated with syncope. His examinations show a mid-systolic murmur at right upper sternal boarder that radiates to carotids. Chest x-ray shows cardiomegaly. ECG reveals left ventricular hypertrophy.

Which of the following is the most appropriate management?

A. Start antihypertensive with tight control of his blood pressure

**B. Surgical valvular replacement

C. Start vasodilators

D. Start diuretics

Pericarditis Treatment

A 28-year-old man presents to the Emergency Department with sudden onset of chest pain that reduced with sitting forward associated with shortness of breath class II. No history of fever. Examinations reveal a normal heart sound with friction rub. His cardiac enzymes are within normal range. ECG shows diffuse ST segment elevation.

Blood pressure 130/70 mmHg
Heart rate 90 /min
Respiratory rate 24 /min
Temperature 37.9 °C
Oxygen saturation 95 %

What is the most appropriate treatment for this patient?

A. Start antibiotics

B. Start corticosteroids

C. Start anticoagulation

**D. Start non steroid anti-inflammatory drug

Δ Pericarditis

Rx : ◦ NSAID (mild)
◦ Colchicine
Steroids (Severe)

A 55-year-old man with congestive heart failure on multiple treatments came to the clinic for follow up. The physician discussed with him the importance of compliance and the effect of the

treatments on his life.

Which of the following medications is associated with reduced mortality rate in congestive heart failure?

A. Digoxin therapy

B. Diuretic therapies

C. anticoagulation therapies

**D. Angiotensin-converting enzyme (ACE) inhibitors

COPD

A 50-year-old man presents to the clinic with chronic history of productive cough and shortness of breath. A diagnosis of chronic obstructive pulmonary disease (COPD) is suspected. Pulmonary function test is ordered.

Which of the following pulmonary function tests is most likely to represent COPD?

**A. Increased total lung capacity (TLC), decreased vital capacity (VC), decreased FEV1/FVC ratio

B. Increased total lung capacity (TLC), decreased vital capacity (VC), increased FEV1/FVC ratio

C. Decreased total lung capacity (TLC), increased vital capacity (VC), decreased FEV1/FVC ratio

D. Increased total lung capacity (TLC), normal vital capacity (VC), decreased FEV1/FVC ratio.

Thoracostomy
Pleural fluid

A 35-year-old-man presented to the Emergency Department with 5-day history of fever, shortness of breath and productive cough. Lung examination reveals dullness to percussion to approximately half of the lung field on the right and his breath sounds are markedly diminished. Chest radiography, shows right lower and middle lobes consolidation with moderate pleural effusion.

Which of the following would indicate the need for tube thoracostomy?

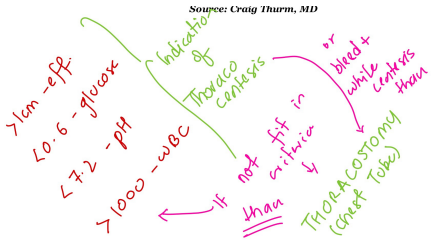

**A. Pleural fluid glucose below 60 mg/dl

B. Pleural fluid PH more than 7.20

C. Pleural fluid with more than 90% polymorphonucleocytes (PMNs)

D. Pleural fluid/ serum protein less than 0.4

Antibiotic

A 36-year-old man presents to Emergency Department with 5-day history of fever, productive cough and shortness of breath. On examination, he is febrile with temperature 38.5 °C and his lung examination reveals dullness to percussion with markedly diminished breath sound over half of the lung field on the right side. Chest radiography shows right lower and middle lobes consolidation and moderate pleural effusion.

Which of the following is the most appropriate management?

A. Start azithromycin and ceftriaxone

B. Start azithromycin, ceftriaxone and oseltamivir

**C. Start azithromycin, ceftriaxone and do thoracocentesis

D. Start azithromycin, ceftriaxone and do CT scan of the chest

Tuberculosis Pleural Effusion Fluid

A 36-year-old man presents to Emergency Department with 4-week history of low-grade fever, non-productive cough and shortness of breath. On examination, he is febrile with temperature 37.9 °C and his lung examination reveals dullness to percussion with markedly diminished breath sound over half of the lung field on the right side. A diagnosis of tuberculous pleural effusion is suspected. Chest radiography shows moderate pleural effusion (see lab results).

6th June DHA

Test Result Normal Values
Leukocytes 4500 <1000/µL
Total Protein 6 10-20 g/L
Glucose 1.6 >2.2 mmol/L
LDH 650 <200/UL

Which of the following tests is the most sensitive to establish the diagnosis?

A. Positive pleural fluid AFB culture

B. Exudative pleural fluid with lymphocytosis

C. Pleural fluid with very low glucose concentration

**D. Pleural fluid adenosine deaminase more than 45 IU/L

A patient with a diagnosis of advanced chronic obstructive pulmonary disease (COPD) who is discussing with his doctor the therapeutic benefits of different therapies on his survival rate.

Which of the following therapies is most likely to improve his survival?

A. Theophylline

B. Corticosteroids

C. Mucolytics

**D. Oxygen

A 25-year-old man presents to the Emergency Department with progressive shortness of breath, non-productive cough and wheezes for 1 day. On examinations, he has obvious difficulty in breathing and his lungs show with diffuse wheezes but no crackles.

Blood pressure 120/70 mmHg
Heart rate 100 /min
Respiratory rate 28 /min
Temperature 36.6 °C
Oxygen saturation 93 %

Which of the following is the most effective initial treatment at this time?

A. Epinephrine

B. Inhaled steroids

**C. Inhaled B2 agonists

D. Intravenous magnesium

Pulmonary Embolism Postpartum Chest pain Sob LMWH

A 25-year-old woman non-smoker presents to Emergency Department with sudden onset of severe chest pain and shortness of breath. Her past medical history is significant for caesarean section 4 days ago. Her examinations show a distressed woman with oxygen saturation 92% but otherwise unremarkable. Chest radiography is unremarkable.

Which of the following is the most appropriate management?

A. Start warfarin

B. Start thrombolytic drugs

**C. Start low molecular heparin

D. Insert inferior vena caval filter

Murmur AS Pulmonary edema

A 65-year-old man presents to the Emergency Department with exertional syncope and progressive shortness of breath. Clinical examination reveals fine crackles at both lung bases and mid-systolic murmur at right upper sternal boarder that radiated to carotids. Chest radiography demonstrated clear evidence of pulmonary edema.

Which of the following statements about the assessment and diagnosis is the most accurate?

A. The murmur will be augmented by standing position

B. The main treatment for symptomatic patient is diuretics

C. Electrocardiogram (ECG) will show right bundle branch block (RBBB)

**D. Presence of symptoms of congestive heart failure are poor prognosis

A 38-year-old man who is smoker for several years presents to the clinic with progressive shortness of breath. Pulmonary function test (PFT) done which results in the following parameters: forced expiratoy volume (FEV1)/forced vital capacity (FVC) ratio < 0.7 with minimal improvement after bronchodilators low diffusing capacity for carbon monoxide (DLCO).

Which of the following is the most likely diagnosis?

**A. Emphysema

B. Bronchial asthma

C. Chronic bronchitis

D. Interstitial lung disease

Chest pain Nifedipine

A 48-year-old woman is seen in the clinic because of recurrent severe nocturnal chest pain for several months that rapidly resolved with sublingual nitrate. She had a normal cardiac catheterization and positive ergonovine echocardiography testing. She does not want to use multiple medications and she accept to use only one drug as a long-term maintenance therapy.

Which of the following drugs is the best strategy for long-term management of this patient?

A. Lisinopril

B. Carvedilol

**C. Nifedipine

D. Aspirin

Hepatitis Autoimmune

A 28-year-old woman has 2-week history of jaundice and an 11-month history of progressive fatigue and arthralgia. She is not on any regular medication and does not drink alcohol. Her examination reveals hepatosplenomegaly. Viral hepatitis screening tests are negative (see lab results).

Test Result Normal Values
Hb 10 130-170 g/L (Male)
120-160 g/L (Female)
Platelets count 120 150-400 x 109/L
WBC 7 4.5-10.5 x 109/L
INR 1.5 0.8-1.2
Total bilirubin 26 3.5-16.5 µmol/L
↑↑ Aspartate aminotransferase 920 12-40 IU/L
↑↑ Alanine aminotransferase 890 5-40 IU/L
Alkaline phosphatase 160 39-117 IU/L
Albumin 30 34-56 g/L

AUTOIMMUNE HEPATITIS

Look for young women with signs of liver inflammation with a positive ANA. More specific tests are liver-kidney microsomal antibodies, high gamma globulin (IgG), anti-smooth muscle antibodies, and anti-liver/kidney microsomal antibodies. The most accurate test is the liver biopsy. Treat with prednisone and or azathioprine.

Which of the following is the most likely diagnosis?

A. Hepatocellular carcinoma

**B. Autoimmune hepatitis

C. Primary biliary cirrhosis

D. Acute cholangitis

GERD

A 34-year-old man presents to the clinic with symptoms of gastroesophageal reflux disease that not responding well to esomeprazole 20 mg once a day. Despite mild improvement in his symptoms, he continues to wake up with an acid taste in the middle of the night. He has not had difficulty swallowing. He confirms that he takes the medication properly. Physical examination is unremarkable. His laboratory investigation are within normal range.

Which of the following is the most appropriate management for this patient?

A. Switch to pantoprazole

B. Perform upper endoscopy

C. Add amoxicillin and clarithromycin

**D. Increase the dose of esomeprazole

Hepatitis

A 35-year-old nurse is seen in the clinic after a recent routine screening for viral hepatitis infection. She was found to have positive antibody to hepatitis C virus (HCV). Her medical history is unremarkable; she has not used illicit drugs or had any history of blood transfusions. She currently feels well and takes no medications. Vital signs and physical examination are normal. Laboratory studies reveal a positive HCV antibody test, but HCV RNA testing is

negative (see lab results).

Test Result Normal Values
Hb 120 130-170 g/L (Male)
120-160 g/L (Female)
Platelets count 300 150-400 x 109/L
WBC 8 4.5-10.5 x 109/L
Aspartate aminotransferase 26 12-40 IU/L
Alanine aminotransferase 30 5-40 IU/L
Alkaline phosphatase 80 39-117 IU/L
Gamma glutamyltransferase 25 6 to 37 IU/L

Which of the following is the most appropriate action to be done?

**A. No further testing

B. Perform liver ultrasound

C. Repeat HCV antibody testing

D. Perform serial alanine aminotransferase monitoring

Hematemesis
Peptic ulcer

A 40-year-old man is evaluated in the Emergency Department for several episodes of hematemesis. He has no previous similar episodes. His history is unremarkable. He takes no medications. There is no jaundice or other signs of chronic liver disease. Abdominal examination reveals no tenderness, guarding, or rebound (see lab results).

Blood pressure 105/65 mmHg
Heart rate 110 /min
Temperature 36.8 °C

Test Result Normal Values
Hb 95 130-170 g/L (Male)
120-160 g/L (Female)
Platelets count 250 150-400 x 109/L
WBC 12 4.5-10.5 x 109/L
Prothrombin time 11 10-13 sec
Alanine aminotransferase 30 5-40 IU/L
Alkaline phosphatase 26 39-117 IU/L
Blood urea nitrogen 14 2.8 to 8.9 mmol/L
Creatinine 88 44-115 µmol/L

Which of the following is the most likely cause of his gastrointestinal bleeding?

A. Erosive gastritis

**B. Peptic ulcer disease

C. Oesophageal varices

D. Mallory-Weiss tear

A 45-year-old man with a diagnosis of gastroesophageal reflux disease who is taking a maximum dose of pantoprazole for several weeks presents to the clinic with heartburn that is

GERD

minimally improved with treatment. The patient verified that he is taking the medication 30 minutes before meals. He takes no other medications. His physical examination is unremarkable. Upper endoscopy findings are normal.

Which of the following is the most appropriate next step in the management?

A. Repeat endoscopy

B. Barium esophagogram

C. Esophageal manometry

**D. Ambulatory pH impedance monitoring

Pancreas Necrosis

A 50-year-old man presents to the Emergency Department with acute onset of abdominal pain, nausea and vomiting. Abdominal examination shows tenderness and guarding at the epigastrium. CT scan of the abdomen reveals fluid around the pancreas. He was admitted and started on intravenous fluids; analgesics and nasogastric suction (see lab results).

Test Result Normal Values
Hb 120 130-170 g/L (Male)
120-160 g/L (Female)
Platelets count 190 150-400 x 109/L
WBC 18 4.5-10.5 x 109/L
Aspartate aminotransferase 55 12-40 IU/L
Alanine aminotransferase 65 5-40 IU/L
Lactate dehydrogenase 6 1.4-3.56 µmol/L
Amylase 850 24-151 IU/L
Lipase 900 0-160 IU/L

PANCREATITIS
Treatment is as follows:

- NPO
- IV hydration at very high volume
- Analgesia
- PPIs decrease pancreatic stimulation from acid entering the duodenum
- If CT/MRI shows >30% necrosis, adding an antibiotic such as imipenem or meropenem may decrease mortality by limiting the development of infected, necrotic pancreatitis
  - Severe necrosis is an indication for needle biopsy to determine the presence of infection.
  - The only way to confirm an infection is with biopsy.

Infected, necrotic pancreatitis should be resected with surgical debridement to prevent ARDS and death.

Which of the following is the most appropriate next step in the management?

**A. Add imipenem

B. Add pantoprazole

C. Add methylprednisolone

D. Urgent surgical consultation

A 32-year-old man is evaluated for a 10-month history of fatigue and diarrhoea. He has a good appetite but has unintentionally significant weight loss over the past 10 weeks. He has not had blood in the stool, melena, or other obvious source of blood loss. His systemic examinations are unremarkable. Stool is negative for occult blood (see lab results).

6th June DHA

Blood pressure 110/70 mmHg
Heart rate 80 /min
Respiratory rate 16 /min
Temperature 36.6 °C
BMI 18 kg/m2

Test Result Normal Values
Hb 109 130-170 g/L (Male)
120-160 g/L (Female)
MCH 20 28-33 pg/cell

MCV 70 80-95 fl
Platelets count 455 150-400 x 109/L
WBC 8 4.5-10.5 x 109/L
Aspartate aminotransferase 30 12-40 IU/L
Alanine aminotransferase 26 5-40 IU/L
Albumin 32 34-56 g/L
Total bilirubin 10 3.5-16.5 µmol/L

Which of the following is the best treatment?

A. Loperamide (anti-diarrhoea agent)

B. Metronidazole (antibiotic drug)

C. Mebendazole (anti-parasitic drug)

**D. Gluten-free diet

A 55-year-old woman with a chronic obstructive pulmonary disease (COPD) on combination of long-acting β2-agonist and inhaled glucocorticoid and albuterol as needed presents to the clinic with worsening of her symptoms. On physical examination, there is no jugular venous distention. Pulmonary examination reveals decreased breath sounds. Bilateral lower extremity edema is noted to a level above the ankles. Echocardiogram is normal apart of high mean pulmonary artery pressure, 52 mmHg (see lab results).

Blood pressure 125/75 mmHg
Heart rate 84 /min
Respiratory rate 20 /min
Temperature 36.6 °C
Oxygen saturation 86 %
BMI 30 kg/m2

Test Result Normal Values
ABG PCO2 7.5 4.7-6.0 kPa
pH 7.6 7.36-7.45
ABG PO2 8.6 10.6-14.2 kPa

Which of the following is the most appropriate treatment at this time?

A. Start mucolytics

B. Start oral diuretics

C. Start oral prednisone

**D. Start oxygen therapy

A 66-year-old woman is evaluated for a 6-week history of increasing dyspnea and right-sided pleuritic chest pain with occasional cough. She has lost significant body weight in the last 3 months. She has no other medical problems and takes no medications. Her physical examination reveals dullness to percussion and decreased breath sounds over both lower lung zones. A 4-cm right breast mass is palpated. Chest radiograph demonstrates bilateral pleural effusions but no evidence of infiltrate or pulmonary vascular congestion. Thoracentesis is performed. Pleural fluid Gram stain is negative (see lab results).

Pleural Fluid
Lights criteria
Exudate

Test Result Normal Values
Total Protein 40 10-20 g/L
Fluid Protein/Serum Protein 0.67 >0.5
Glucose 3.5 >2.2 mmol/L
LDH 350 <200/UL
Total Proteins 60 60-84 g/L
Lactate dehydrogenase 125 60-160 IU/L
Leukocytes 3600 <1000/µL

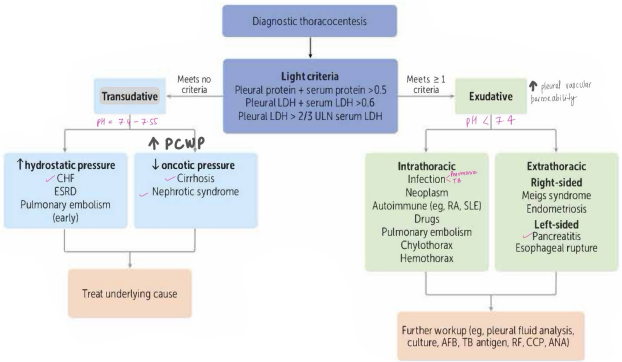

Which of the following is the most appropriate statement about the diagnosis?

**A. Exudative pleural effusion due to malignancy

B. Transudative pleural effusion due to malignancy

C. Exudative pleural effusion due to heart failure

D. Transudative pleural effusion due to empyema

A 28-year-old woman with bronchial asthma that controlled on budesonide and albuterol inhalers is evaluated in the clinic as she is 6 weeks pregnant. Her symptoms are well controlled on the treatment. However, symptoms usually flare in fall and she treats these symptoms with an add-on oral leukotriene inhibitor. She currently has no asthma symptoms. On examination, vital signs are normal. The lungs show good air entry and no wheezes. She is so concern about the safety of medications during pregnancy.

What is the best information to be delivered to her with regard to medication safety?

**A. Continue the current treatments as they are safe during pregnancy

ALL ASTHMA MEDS SAFE IN PREGNANCY

B. Stop budesonide and continue albuterol inhaler

C. Stop albuterol and continue budesonide inhaler

D. Switch to as-needed albuterol therapy

Asthma
Methacoline

A 26-year-old man presents to the clinic with shortness of breath and occasional wheeze that occurs several times per week. He develops significant shortness of breath when playing football. He notes that it takes several minutes to recover his breath when this occurs. He also notes coughing during exercise as well. He takes no medications. On physical examination, vital signs are normal. Mild nasal congestion is noted. His systemic examinations are unremarkable. A chest radiograph is normal. Spirometry findings are within normal parameters.

Which of the following is the most appropriate next step in assessment?

A. Repeat spirometry

B. Clinical observation

**C. Methacholine challenge test

D. Helical (spiral) computed tomography (CT) for the chest

Asthma Meds
SABA LABA

A 31-year-old woman is evaluated because of daily wheezing and breathlessness that limit her activities several times a week. Medical history is otherwise unremarkable. She has never

smoked. She is diagnosed with moderate persistent asthma.

In addition to a short-acting β2-agonist, which of the following is the most appropriate treatment?

MILD INTERMITTENT :-
SABA

MILD PERSISTENT :-
SABA + Inhaled Corticosteroid

MOD. PERSISTENT :-
SABA + ICS + LABA OR
SABA + ↑dose ICS + LABA

**A. Add a low-dose inhaled corticosteroid and long-acting β2-agonist

B. Add a low-dose inhaled corticosteroid

C. Add a leukotriene antagonist

D. Add thiophylline

COPD
Ventilation

A 66-year-old woman with severe COPD is admitted with 4 days of dyspnoea and cough. She is alert, in moderate respiratory distress, and has an oxygen saturation of 93% on 3 L/min supplemental oxygen. A chest radiography demonstrates no consolidation. She receives intensive bronchodilator therapy and systemic steroids (see lab results).

Test Result Normal Values
ABG PCO2 8.8 4.7-6.0 kPa
pH 7.28 7.36-7.45
ABG PO2 9.9 10.6-14.2 kPa

STILL NOT CONTROLLED
SABA + LABA + MAX. DOSE ICS + Tiotropium

STILL NOT CONTROLLED
ADD ORAL STEROID

Which of the following is the best next step in the management?

**A. Non-invasive ventilation

B. Increase supplemental oxygen

C. Decrease supplemental oxygen

D. Intubation and mechanical ventilation

- PO_2 < 7.3 Kpa
  Home O_2 therapy - VENTURI MASK
- Coma, ↑ secretions - Mechanical Ventilation

Pleuritic Chest pain
OCP

A 58-year-old woman with acute onset shortness of breath and pleuritic chest pain. She is diagnosed with pulmonary embolism.

Which of the following is an indication to do thrombophilia workup?

A. Age above 55 years

**B. Being on oral contraceptive pills

C. Has a history of connective tissue disease

D. Has negative family history of thrombosis

Lung lesion
Non smokers

6th June DHA

A 32-year-old man is evaluated in the clinic because of an abnormal chest computerised tomography (CT) scan that revealed a small lung lesion (7 mm) without any other abnormalities. He is non-smoker and he is asymptomatic. Physical examination shows no lymphadenopathy and normal lung examinations (see lab results).

Test Result Normal Values
Hb 140 130-170 g/L (Male)
120-160 g/L (Female)
Platelets count 300 150-400 x 109/L
WBC 8 4.5-10.5 x 109/L

ESR 11 2-10 mm/h (Male)
3-15 mm/h (Female)
Calcium 2.25 2.15-2.62 mmol/L

Which of the following is the most appropriate procedure to do next?

**A. Repeat CT scan within 3-6 months

B. Pulmonary function test

C. Biopsy of this lesion

D. PET scan

Cardiac risk Assessment Pooled Cohort

A 60-year-old man is evaluated in the clinic for cardiac risk assessment. He is asymptomatic and physically active. He has never smoked. He has no chronic health issues and takes no medications. His physical examinations are normal. Cardiovascular risk calculation using the Pooled Cohort Equations predicts a 6.5% risk of a myocardial infarction in the next 10 years that indicate an intermediate risk of myocardial infarction.

≥ 7.5 (ELEVATED RISK)

Which of the following investigations should be done next?

A. Cardiac CT angiography

B. Stress echocardiography

**C. High-sensitivity C-reactive protein

D. Cardiac magnetic resonance (CMR) imaging

What other factors play a role in heart risk assessment?

Depending on your cardiovascular risk assessment score and your symptoms (if any), your healthcare provider may order additional tests, such as:

- Blood test for hsCRP.
- Lipid panel to measure total cholesterol, triglycerides and lipoproteins, including lipoprotein (a).
- Electrocardiogram (ECG).
- Exercise stress test.

ACC/AHA Pooled Cohort Risk Equation

Sex	Male/Female	Systolic Blood Pressure	? (mmHg)
Age	?	History of Diabetes	Yes/No
Race	White/African American/other	Treatment for Hypertension	Yes/No
Total Cholesterol	? (mg/dL)	Smoking	Yes/No
HDL Cholesterol	? (mg/dL)		

A 58-year-old woman with hypertension and type 2 diabetes mellitus presents to the clinic for routine follow-up. She has no symptoms. Medications are hydrochlorothiazide, losartan, atorvastatin, and metformin. Cardiac examination shows a grade 2/6 diastolic murmur heard best over the apex. Peripheral pulses are normal. Electrocardiogram shows sinus rhythm with nonspecific ST changes.

Blood pressure 160/80 mmHg
Heart rate 78 /min
Respiratory rate 18 /min
Temperature 36.6 °C
Oxygen saturation 96 %

Which of the following is the most appropriate test to perform next?

**A. Transthoracic echocardiography

B. Cardiac CT angiography

C. Transesophageal echocardiography

D. No further testing

Atrial fibrillation

A 55-year-old woman presents to the clinic for her regular follow-up. 6 months ago, she presented to Emergency Department with palpitations and dyspnea and diagnosed to have atrial fibrillation. She is currently asymptomatic with no palpitations. Her medical history is also

significant for a transient ischemic attack and hypertension. Her medications are warfarin, metoprolol and candesartan. Her physical examination is unremarkable. Her most recent electrocardiogram shows normal sinus rhythm.

Which of the following is the most appropriate management?

**A. Continue warfarin

B. Discontinue warfarin

C. Continue warfarin and start aspirin

D. Discontinue warfarin and start clopidogrel

CHF
Furosemide

A 68-year-old man presented to the Emergency Department with progressive exertional dyspnoea, orthopnea and dry cough for 7 days. His medical history is significant for hypertension. Physical examination reveals raised central venous pressure, fine crackles at lung bases and hepatomegaly. His extremity examination reveals bilateral pitting edema. Echocardiogram shows a left ventricular ejection fraction of 60% and normal valves. Chest radiograph shows evidence of pulmonary edema (see lab results).

Blood pressure 160/85 mmHg
Heart rate 86 /min
Respiratory rate 18 /min

Test Result Normal Values
Sodium 140 134-146 mmol/L
Potassium 4 3.5-5.1 mmol/L
Urea 6 2.75-7.4 mmol/L
Creatinine 88 44-115 µmol/L
Brain natriuretic peptide 900 0-300 ng/L

Which of the following is the most appropriate next step in the management?

A. Start calcium channel blocker agent

B. Start β-Blocker agent

C. Start spironolactone

**D. Start furosemide

A 26-year-old pregnant woman visits the clinic for regular follow-up. She is asymptomatic. She is in her 30th week of pregnancy. Her physical examination reveals a mid-systolic ejection murmur at the right upper sternal border. The murmur radiates to carotids. No diastolic murmur is heard.

Which of the following is the most likely diagnosis?

**A. Aortic stenosis

B. Mitral stenosis

C. Tricuspid stenosis

D. Physiologic murmur of pregnancy

Diffuse St segment
Ibuprofen

A 28-year-old man is evaluated in the Emergency Department for severe persistent chest pain for 1-day. The pain is constant but exacerbated when leaning forward and not associated with other symptoms. Physical examination is unremarkable apart of a friction rub at the left lower sternal border. Electrocardiogram shows diffuse, concave upward ST-segment elevations and PR-segment depression most prominent in leads V1 through V6.

Which of the following is the most appropriate treatment?

A. Prednisone

B. Nitroglycerin

C. Warfarin

**D. Ibuprofen

Poor Prognostic Factors in Heart Failure	
Clinical	High NYHA class, hypotension, tachycardia at rest, JVD, S3
Labs	Hyponatremia, elevated BNP, renal insufficiency
EKG	QRS >120 milliseconds, LBBB
Echocardiogram	Severe reduction in EF, pulmonary hypertension, diastolic dysfunction, RV function impairment
Associated conditions	Anemia, atrial fibrillation, DM

Re infarction
CHF
Systolic vs
Diastolic

A 58-year-old woman was admitted with a diagnosis of acute myocardial infarction received appropriate treatments and now she is ready for discharge. She is so concern about the secondary prevention of infarction. → ASPIRIN → to prevent Re-infarct

Which of the following statements is the most appropriate?

A. Anti-platelet agents should be used for short period to reduce the risk of recurrent infarction

B. Calcium channel blockers should be used indefinitely to reduce the risk of recurrent infarction

C. Hormonal replacement therapy should be given to postmenopausal women to prevent coronary events

**D. Angiotensin-converting enzyme (ACE) inhibitors should be used indefinitely by patient with clinically evident heart failure

Systolic HF

A 55-year-old woman with non-decompensated systolic heart failure and ejection fraction of 25% presents to the clinic for routine follow-up.

Which of the following medications is the most appropriate management?

**A. Lisinopril

B. Amlodipine

C. Furosemide

D. Spironolactone

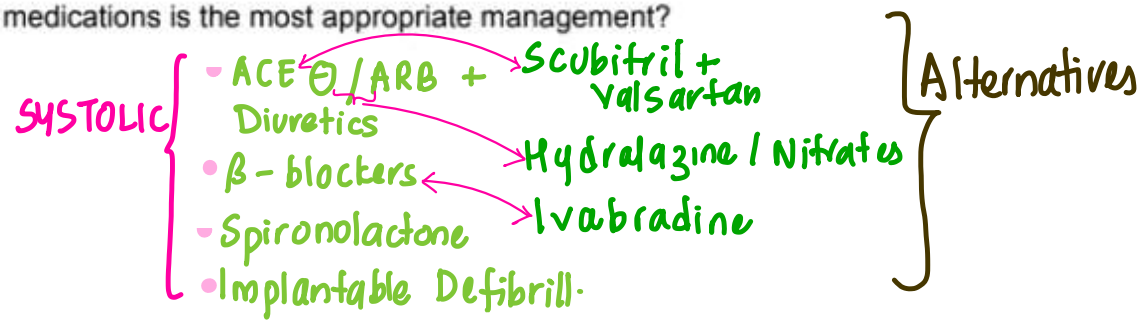

Murmur

A 45-year-old woman is evaluated for a 3-week history of progressive shortness of breath that limit her activities. Medical history is significant for asthma and moderate mitral regurgitation. Her only medication is an albuterol inhaler as needed. On physical examination, her vital signs are normal. Cardiac examination reveals a grade 3/6 holosystolic murmur radiating to the axilla. Lungs are clear to auscultation.

Which of the following is the most appropriate diagnostic test?

A. Spirometry

B. Transthoracic echocardiogram

**C. Transesophageal echocardiogram

D. Helical (or spiral) computed tomography (CT) of the chest

Pleural Effusion

A 54-year-old man presents with shortness of breath and fever for 1 week. On physical examination, the patient is febrile and dyspneic. His oxygen's saturation is 89% on room air. Chest examination shows absent breath sounds and dullness to percussion over right lung field. Chest radiography confirms a large right-sided pleural effusion.

Which of the following is the most useful to establish a diagnosis of exudative pleural effusion?

A. Pleural fluid protein/ serum protein < 0.5

**B. Pleural fluid pLDH/ serum LDH > 0.6

C. Pleural fluid LDH >1/3 normal upper limit for serum

D. Pleural fluid white cell count > 1000

Pleural Fluid Thoracocentesis

A 54-year-old man presents with shortness of breath and fever for 1 week. On physical examination, the patient is febrile and dyspneic. His oxygen's saturation is 89% on room air. Chest examination shows absent breath sounds and dullness to percussion over right lung field. Chest radiography confirms a large right-sided pleural effusion.

Which of the following factors indicating the need for therapeutic thoracentesis?

**A. Loculated pleural fluid

B. Pleural fluid pH more than 7.30

C. Pleural fluid glucose more than 80 mg/dl

D. Negative gram stain of the pleural fluid

Atrial fibrillation
Palpitation
TSH

A 67-year-old man presents with insomnia, irritability and palpitation for 3 months. He is known to have hypertension, depression and atrial fibrillation. He is on amiodarone, fluoxetine and enalopril. Clinically, he is unremarkable.

Blood pressure 130/70 mmHg
Heart rate 76 /min
Oxygen saturation 95 %

Which of the following is the most appropriate next step?

A. Add propranolol

**B. Measure thyroxin level and TSH

C. Substitution of antidepressant drug

D. Refer him for psychiatric assessment

Chest pain
ECG

A 62-year-old man presents to Outpatient Clinic with recurrent episodes of sternal chest

tightness, which occurs mainly after heavy physical exertion. He has no chronic medical problems. Clinical examination and baseline ECG were normal.

Which of the following is the most appropriate next step in diagnosis?

**A. Exercise ECG

B. Echocardiography

C. Coronary arteriography

D. Myocardial perfusion scintigraphy

Chest pain
Exercise
Nitroglycerin
Ibuprofen

A 28-year-old man presents with recent onset of chest pain. The pain is retrosternal, localized, sharp and constant in intensity. He noticed increase in severity with movement. He started active exercise program a week prior to the onset of the symptom.

Blood pressure 110/70 mmHg
Heart rate 76 /min
Oxygen saturation 95 %

Which of the following is the most appropriate next step in management?

A. Atenolo

**B. Ibuprofen

C. Nitroglycerine

D. Reassurance and assess after 1 week

Murmur

A 65-year-old woman came for routine annual check-up found to have with harsh ejection systolic murmur, which propagated to the neck.

Which of the following factors is the most important in deciding the time of the surgery?

A. Low pulse pressure

B. Intensity of the murmur

**C. The patients symptoms

D. Left ventricular hypertrophy

Aortic Stenosis
Valve

A 65-year-old man found to have an ejection systolic murmur on clinical examination. There is no history of chest pain, shortness of breath nor syncope. ECHO confirmed aortic stenosis with good left ventricular systolic function. Aortic valve gradient of 40 mmHg.

Blood pressure 100/65 mmHg
Heart rate 67 /min

MILD $> 1.5 cm^2$, 15 – 25 mmHg
MOD. $1 - 1.5 cm^2$, 25 – 40 mmHg
SEVERE $0.7 - 1 cm^2$, > 40 mmHg
CRITICAL $< 0.7 cm^2$

Which of the following is the most appropriate management option?

**A. Follow-up

B. Anti-coagulation

C. Aortic valvoplasty

D. Surgical valve replacement

Atrial fibrillation
Rhythm
Rate

A 67-year-old man known to have hypertension came to Emergency Room with acute onset of palpitation. His pulse on the monitor showing pulse rate of 170/min. He have irregular pulse with normal cardiac and chest examinations.

Blood pressure 120/70 mmHg
Respiratory rate 18 /min
Oxygen saturation 91 %

} Stable pt.

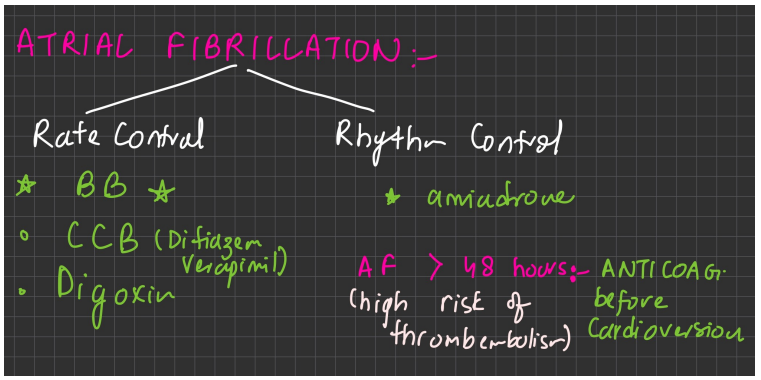

Which of the following is the best treatment option?

A. Cardioversion

B. Adenosine

**C. Amidorone

D. observation

A 38-year-old Indian man presents with progressive dyspnea for 3 months. He has past history of old tuberculosis. He has no other medical problems and not on any medications. His JVP was elevated and rises further on inspiration. Cardiac examination was normal with no murmurs.

Blood pressure 105/60 mmHg
Heart rate 120 /min
Oxygen saturation 93 %

Which of the following is the most likely diagnosis?

A. Myocarditis

B. Corpulmonale

C. Cardiomyopathy

**D. Constrictive Pericarditis

Mitral stenosis
Mitral valve orifice

A 28-year-old woman who is a known case of mitral stenosis came to the clinic asking about how critical is her condition. Echo was done and mitral valve orifice was recorded.

Which of the following mitral valve orifice measurement is consider critical?

**A. <1 cm

B. <2 cm

C. < 3 cm

D. < 4 cm

	Mild	Moderate	Severe
Valve area (cm^2)	>1.5	1–1.5	<1
Mean gradient (mmHg)	<5	5–10	>10
Pulmonary artery pressure (mmHg)	<30	30–50	>50

Post MI
Papillary

A 72-year-old man presented with acute sever chest pain with an ECG revealing St segment elevation II,II,AVF, leads was treated with thrombolysis but 2 days later acutely unwell with sever dyspnea. On examination, he has loud systolic murmur at the apex, which radiates to the axilla and bilateral crackles at the base of the lungs.

Blood pressure 90/60 mmHg
Heart rate 100 /min
Respiratory rate 25 /min
Oxygen saturation 88 %

Which of the following is the most likely diagnosis?

A. Myocarditis

B. Cardiogenic shock

**C. Rupture papillary muscle

D. Acute Rt sided heart failure

TABLE 2.1-16. A Timeline of Common Post-MI Complications

TIME	COMPLICATIONS
First day	Life-threatening arrhythmia (eg, VT, VF)
2–4 days	Arrhythmia Peri-infarction pericarditis Treatment is supportive NSAIDs avoided (impair collagen deposition and increase risk of ventricular wall rupture) Compare to Dressler syndrome (see later)
5 days–2 weeks	LV wall rupture (acute pericardial tamponade causing electrical alternans, pulseless electrical activity, and JVD) Papillary muscle rupture (severe mitral regurgitation, pulmonary edema) Septal rupture (lower-left sternal border murmur, increase in O_2 saturation in the RV)
Weeks to months	Dressler syndrome Autoimmune process occurring 2–10 weeks post-MI; presents with fever, pericarditis, pleural effusion, leukocytosis, and ↑ erythrocyte sedimentation rate (ESR) Treat with NSAIDs (unlike peri-infarction pericarditis) Ventricular aneurysm CHF, arrhythmia, persistent ST-segment elevation, mitral regurgitation, thrombus formation

A 65-year-old man with heart failure requires rate control to treat coexisting atrial fibrillation.

Which of the following is the best treatment option?

**A. Digoxin

B. Adenosine

C. Lidocaine

D. Nitroglycerine

Asymptomatic healthy 24-year-old woman came for a check-up visit and found to have grade II mid-diastolic murmur over the apex.

Which of the following is the best next step in diagnosis?

A. Cardiac MRI

**B. Echocardiography

C. Cardiac catheterization

D. Antistreptolysin O titre

HF
Dyspnea
Beta blocker
Carvedilol

A 70-year-old man presented with progressive dyspnea, palpitation and fatigue for 3 months. He is known to have hypertension on captopril. He underwent echo which showed poor left ventricular function so furosemide was added with good control of his symptoms. His vital signs upon the last clinic visit shown below.

Blood pressure 150/90 mmHg
Heart rate 90 /min
Respiratory rate 18 /min
Oxygen saturation 95 %

Which of the following medication should be added at this stage?

A. Digoxin

**B. Carvedilol → Non Selective β blocker → HF, LV Dysfunction, Hypertension

C. Nifedipine

D. Hydralazine

ACE
ARB
Side effects

A 70-year-old man admitted with left lower limb swelling and pain diagnosed as DVT where heparin was started. He has a history of diabetes mellitus, hypertension and chronic heart failure. He is on insulin; furosemide and enalapril (see lab results).

Blood pressure 110/70 mmHg
Heart rate 76 /min
Oxygen saturation 94 %

Test Result Normal Values
Sodium 135 134-146 mmol/L

Potassium 6,0 3.5-5.1 mmol/L
Chloride 107 97-108 mmol/L
Urea 7.9 2.75-7.4 mmol/L
Creatinine 120 44-115 µmol/L
APTT 50 30-40 sec
Prothrombin time 14 10-13 sec

ACEI → ↑ bradykinin → cough + angio-edema. ARBs have less risk.

ACEI, ARBs, Aliskiren → ↓ GFR (acute renal failure) as efferent arteriole vaso-constriction controlled by angiotensin II. ↓ aldosterone → ↑ K^+.

Renal teratogens, cause rash.

Which of the following medications should be discontinued at this stage?

A. Insulin

**B. Enalapril

C. Heparin

D. Furosemide

Malaria
Blood smear
Fever

A 35-year-old man presented to Emergency Room with recurrent attacks of high-grade fever with chills for 1 week. He was on a work trip to Sudan 3 weeks ago. Each attack begins with chills for few hours followed by fever up to 40.5 degree, which resolves with profuse sweating. The attacks comes every other day. On examination, mild splenomegaly was detected. Blood smear at Emergency Room was negative for parasites.

Blood pressure 110/70 mmHg
Heart rate 120 /min
Temperature 39 °C

Which of the following is the most appropriate next step in diagnosis?

A. Repeat thin blood smear

B. Repeat thick blood smear once more

C. Repeat blood smear during the attack

**D. Repeat blood smear every 8 hours for 2 days

Meningitis
CSF

A 51-year-old woman presented to the hospital with 2-days history of malaise and headache. The headache became more intense and was associated with pain in her neck. Her husband reported that she had also fever. She was previously well with no significant medical history. On examination, she looked unwell confused, febrile and with positive Kernig's sign. CT scan brain was normal. Lumbar puncture done (see lab results).

Test Result Normal Values
Colour Turbid colourless
Cells 200 0-3 /µL
Total protein (Women) 0.9 0.15-0.45 g/L
Glucose 1.6 2.50-3.89 mmol/L

Which of the following is the most likely causative organism?

A. Escherichia coli

B. Listeria monocytogenes

**C. Streptococcus pneumoniae

D. Staphylococcus pyogenes

TABLE 2.9-13. Common Pathogens Causing Meningitis

BACTERIAL	VIRAL (ASEPTIC)	HIV
Streptococcus pneumoniae (#1 in adults) *Neisseria meningitidis* (#1 in teens) Group B Streptococcus (GBS) and *Escherichia coli* (in neonates) *Haemophilus influenzae* serotype b, *Listeria* (see Fig. 2.9-16)	Enteroviruses: ▪ Echovirus ▪ Coxsackie ▪ HSV-2	*Cryptococcus neoformans*, cytomegalovirus (CMV), HSV, varicella zoster virus (VZV), tuberculosis (TB), toxoplasmosis, and John Cunningham (JC) virus (progressive multifocal leukoencephalopathy [PML])

TABLE 2.9-14. CSF Profiles

	RBCS (PER MM³)	WBCS (PER MM³)	GLUCOSE (MG/DL)	PROTEIN (MG/DL)	OPENING PRESSURE (CM H_2O)	APPEARANCE	GAMMA GLOBULIN (% PROTEIN)
Normal	<10	<5	>2/3 of serum	15–45	10-20	Clear	3–12
Bacterial meningitis	↔	↑ (>1000 polymorphonuclear [PMN] cells)	↓	↑↑	↑	Cloudy/purulent	↔ or ↑
Viral/aseptic meningitis	↔	↑ (monos/lymphs)	↔	↔ or ↑	↔ or ↑	Most often clear	↔ or ↑

TB
ANTI TB MEDS
side affect

A 45-year-old man has been diagnosed as a case of pulmonary tuberculosis.

Which of the following investigations is essential prior initiation of the therapy?

A. Vitamin B6

B. PPD skin test

C. Plasma glucose

**D. Liver function test

- All TB medications cause hepatoxicity, but should not be stopped unless transaminases rise to 3–5× the upper limit of normal.

Drug	Toxicity	Management
Rifampin	Red color to body secretions	None, benign finding
Isoniazid	Peripheral neuropathy	Use pyridoxine to prevent
Pyrazinamide	Hyperuricemia	No treatment unless symptomatic
Ethambutol	Optic neuritis/color vision	Decrease dose in renal failure

A 39-year-old man came to the clinic for follow-up. He is recently diagnosed as pulmonary tuberculosis and was started on rifampicin, Isoniazid, pyrazinamide and ethambutol for 4 weeks. Basic lab workup were normal. LFT test was repeated (see lab results).

Test Result Normal Values
Direct bilirubin 56 1.5-6.5 µmol/L
Total bilirubin 76 3.5-16.5 µmol/L
Aspartate aminotransferase 465 12-40 IU/L
Alanine aminotransferase 620 5-40 IU/L
Alkaline phosphatase 720 39-117 IU/L
Gamma glutamyltransferase 387 6 to 37 IU/L

Which of the following is the most appropriate next step?

A. Stop Isoniazid

B. Stop rifampicin

C. Stop pyrazinamide

**D. Stop all medications

Meningitis
Cocobacilli
Gram
Rifampicin
Antibiotic

An 82-year-old woman admitted to the hospital for meningitis. Her CSF was obtained and Gram stain showed Gram negative cocco-bacilli

Which chemo-prophylaxis should be offered to her contacts?

**A. Rifampicin

B. Ceftriaxone

C. Ciprofloxacin

D. Azithromycin

Pregnant
UTI
Antibiotic

A 23-year-old pregnant woman presented with frequency and dysuria for 5 days (see lab result).

Blood pressure 110/70 mmHg
Heart rate 76 /min
Temperature 37.6 °C

Test Result Normal Values
Leukocytes 30 0-3 per high power field

Which of the following is the best treatment option?

A. Flucloxacillin

**B. Augmentin

C. Ciprofloxacin

D. Nitrofurantion

A 35-year-old man presented with fever, rigors and weight loss for 10 days. He underwent Mitral valve replacement by prosthetic valve a month ago. Echo showed small vegetation.

Blood pressure 90/70 mmHg
Heart rate 100 /min
Temperature 38.7 °C

Which of the following organisms is the most likely to be responsible for his presentation?

A. Coxiella burnetii

B. Staphylococcus aureus

C. Streptococcus viridans

**D. Staphylococcus epidermidis

A 24-year-old woman came to the clinic complaining of yellowish offensive vaginal discharge and itching for 2 weeks duration. She has no other significant medical history. Vaginal swab done which showed motile flagellate organisms on wet film microscopy.

Which of the following is the best treatment option?

A. Tetracycline

B. Cefuroxine

C. Nitrofurantoin

**D. Metronidazole

A 24-year-old married woman came to the clinic complaining of yellowish offensive vaginal discharge and itching for 2 weeks duration. She has no other significant medical history. Vaginal swab done which showed motile flagellate organisms on wet film microscopy. Appropriate treatment was initiated.

Which of the following is the best management option for her husband?

A. Tetracyclin

**B. Metronidazole

C. No treatment

D. Follow-up in 2 weeks

A 25-year-old man developed fever, malaise and rash on the palms of his hands as well as on the soles of both feet. 6 weeks earlier, he had a painless ulcer on his penis. He gave a history of recent travel and extramarital unprotected sex. On examination, he has generalized lymphadenopathy.

Blood pressure 110/70 mmHg
Heart rate 87 /min
Temperature 38.6 °C

Which of the following is the most likely diagnosis?

A. HIV

**B. Syphilis

C. Herpes zoster

D. Chlamydia trachomatis

GIT

GERD
Hpylori
Risk factor

A 45-year-old woman was diagnosed with GERD for 4 years on daily dose of PPI with a good control of her symptoms. However, she reported occasionally heartburn. She underwent endoscopy, which was normal. Gastric biopsy revealed Helicobacter pylori. She gave history of smoking 20 pack-year but she quit 3 years ago, but she gave history of social alcohol drink. On examination, she is obese otherwise normal.

Which of the following risk factors is mostly contribute to worsening of her GERD and she should control it?

**A. Obesity

B. Smoking

C. Alcohol intake

D. Helicobacter pylori

Hpylori

A 46-year-old man came to the clinic asking for advice about eradication of H.pylori. He is known to have GERD on daily dose of PPI for 8 years with good control. He developed new onset of epigastric pain and was found to have helicobacter pylori By ELISA testing.

Which of the following can happen post H.pylori eradication in such patient?

A. No sequel post eradication

**B. Need to increase the PPI dose

C. Reducing risk of barrett's esophagitis

D. Increase the risk of atrophic gastritis

A 60-year-old man with a history of diabetic mellitus, hypertension and osteoarthritis presents with melena. He gave a history of NSAID use for knee pain. He underwent upper GI endoscopy, which showed 1 cm duodenal ulcer with bleeding vessel, hemoclip was applied with good hemostasis (see lab result).

Blood pressure 100/60 mmHg
Heart rate 110 /min
Oxygen saturation 95 %

Test Result Normal Values
Hb 8.4 130-170 g/L (Male)
120-160 g/L (Female)

Which of the following is the most appropriate next step in the management?

A. High dose of oral PPI BID

B. High dose of oral H2 blocker

C. IV PPI infusion for 24 hours then oral PPI

**D. IV PPI infusion for 72 hours then oral PPI

ERCP
Pancreatitis

A 44-year-old woman known to have gall bladder stones presented with biliary pain and jaundice. US abdomen confirmed CBD stones. She underwent ERCP for stone extraction. Few hours later, she developed sever epigastric pain, nausea and vomiting (see lab results).

Test Result Normal Values
Hb 11 130-170 g/L (Male)
120-160 g/L (Female)
WBC 18 4.5-10.5 x 109/L
Urea 11 2.75-7.4 mmol/L

Creatinine 110 44-115 µmol/L
Total bilirubin 23 3.5-16.5 µmol/L
Lipase 3000 0-160 IU/L

Which of the following management options has proven a survival benefit in such patient?

A. Urgent repeat of ERCP

B. Administration of IV antibiotics

C. Rectal indomethacin and IV steroid

**D. IV ringer lactate at rate of 250 ml/hours

Chronic pancreatitis
Steatorrhea
Lipase

A 60-year-old man with a history of chronic alcohol intake presents with chronic dull epigastric pain and diarrhoea for 6 months. He reported 5 bulky stool a day (see reports).

72 hours stool collection:
>42 gram of fat/24 hours.

Plain abdomen X-ray:
Showed pancreatic calcification.

Which of the following is the most effective strategy to control his symptoms?

A. High dose of PPI BID

B. Long course of metrodidazole

**C. Lipase 30.000 IU with each meal

D. Diet modification with small frequent low fat meals

Replace Pancreatic Enzyme to control Fat Malabsorption

RUQ pain
Cholangitis

A 60-year-old man presented to Emergency Room with 3-days history of epigastric and RT upper quadrant pain and nausea. He gave a history of fever and rigors for 1-day duration. On Examination, Jaundice and tender RT upper abdomen with no rebound (see lab results and report).

Blood pressure 100/70 mmHg
Heart rate 120 /min
Temperature 38.6 °C

Test Result Normal Values
Hb 11 130-170 g/L (Male)
120-160 g/L (Female)
WBC 16.4 4.5-10.5 x 109/L
Direct bilirubin 49 1.5-6.5 µmol/L
Total bilirubin 57 3.5-16.5 µmol/L
Aspartate aminotransferase 150 12-40 IU/L
Alanine aminotransferase 200 5-40 IU/L
Alkaline phosphatase 250 39-117 IU/L

US abdomen:
Reveals multiple small gallstones with mild thickening of the wall. CBD dilated 9 mm.

Which of the following is the most likely diagnosis?

A. Acute Hepatitis

B. Liver abscess

C. Acute cholecystitis

**D. Ascending Cholangitis

Which of the following is the least risk factors for cholesterol gallstones?

A. Obesity

**B. Nulliparity

C. Rapid weight loss

D. Hypertriglyceridemia

Biliary Stricture

A 34-year-old woman presented to the clinic for evaluation of persistent high liver enzymes for 6 months. She is asymptomatic. She has no significant medical or drugs history (see lab results and reports).

Test Result Normal Values
Direct bilirubin 1.1 1.5-6.5 µmol/L
Total bilirubin 1.9 3.5-16.5 µmol/L
Aspartate aminotransferase 53 12-40 IU/L
Alanine aminotransferase 43 5-40 IU/L
Alkaline phosphatase 546 39-117 IU/L
Albumin 35 34-56 g/L

US Abdomen:
Unremarkable.

MRCP:
Showed multi focal segmental biliary strictures and dilation.

Which of the following is the best next step in the diagnosis?

A. Liver biopsy

**B. Perform colonoscopy

C. Repeat abdomen ultrasound

D. Check anti-nuclear antibodies

HCV

What is the most common HCV genotype in Saudi Arabia?

A. 1

B. 2

C. 3

**D. 4

A 50-year-old man referred to the clinic with positive HCV. He is asymptomatic with no history of drug use or previous blood transfusion. Physical examination was unremarkable. Reviewing of his lab test showed normal LFT with positive anti-HCV (ELISA). Hepatitis C RNA was negative. US abdomen showed normal liver.

Which of the following is the most appropriate next step in management?

A. Liver fibroscan

**B. No further tests

C. Triphasic CT scan of liver

D. Repeat HCV RNA in 6 months

Hepatitis Treatment

A 43-year-old man who is known to have chronic hepatitis B presents to the clinic for evaluation. He is asymptomatic with normal physical examination (see lab results and report).

Test Result Normal Values
RBC 5
4.7-6.1 x 1012/L (Male)
4.2-5.4 x 1012/L (Female)
Hb 11.9 130-170 g/L (Male)
120-160 g/L (Female)
Platelets count 145 150-400 x 109/L
WBC 3.9 4.5-10.5 x 109/L
Direct bilirubin 17 1.5-6.5 µmol/L
Total bilirubin 21 3.5-16.5 µmol/L
Aspartate aminotransferase 89 12-40 IU/L
Alanine aminotransferase 61 5-40 IU/L
Alkaline phosphatase 160 39-117 IU/L

- Hepatitis B becomes chronic in 10% of patients and there is no treatment to prevent this (chronicity for hepatitis B is defined as persistence of surface antigen >6 months). If patients are positive for e-antigen with elevated DNA viral load, treatment is entecavir, adefovir, lamivudine, telbivudine, tenofovir, or interferon (note that interferon is an injection and has many side effects, including arthralgia/myalgia, leukopenia and thrombocytopenia, depression, and flu-like symptoms).

1st line
↓
Entecavir
↓
less side affects

Hep C Rx } Sofosbuvir, Ledipasvir, Velpatasvir

US Abdomen:
Showed mild coarse liver echotexture.

Which of the following is the most appropriate treatment option?

**A. Entecavir

B. Observation

C. Lamivudine

D. Pegylated Interferon

Vibrio Cholera

Which of the following stool electrolyte testing results would most represent a Vibrio cholerae?

A. Stool osmoles of 300 mOsm/kg

B. Stool osmoles of 410 mOsm/kg

**C. Fecal osmotic gap of 30 mOsm/kg

D. Fecal osmotic gap of 110 mOsm/kg

HF
chest pain
ACE

A 44-year-old woman with heart failure diagnosed 9 months ago is evaluated for 3-month history of non-productive cough. No history of chest pain, dyspnoea or orthopnoea. She has never smoked. Her current medications are lisinopril, carvedialol and fruosemide. Unremarkable cardiac and chest examination (see reports).

Blood pressure 100/70 mmHg
Heart rate 76 /min
Respiratory rate 18 /min
Oxygen saturation 95 %

Chest X-ray:
Normal.

ECHO:
Showed left ventricular ejection fracture 40%.

Which of the following is the most appropriate management?

**A. Discontinue lisinopril

B. Order pulmonary function test

C. Increase the dose of fruosemide

D. Start inhaled B2- adrenergic agonist

A 54-year-old man is evaluated prior elective hernia repair surgery. He is known case of bicuspid aortic valve and mechanical aortic valve replacement 4 years ago. He is asymptomatic. Cardiac examination showed grade 1/6 ejection systolic murmur at aortic area.

Blood pressure 110/70 mmHg
Heart rate 76 /min
Respiratory rate 18 /min
Oxygen saturation 95 %

Which of the following is the best management option for endocarditis prophylaxis?

A. Amoxicillin

B. Augmentin

C. Cefuroxime

**D. No antibiotic

CHAD Score

A 64-year-old man presented to Emergency Room with symptoms of dyspnoea, SOB, and palpitation. He is a known case of diabetic mellitus, hypertension and hyperlipidaemia. He is smoker with history of stroke. On examination, found to have irregular pulse. Cardiac and chest examination showed high JVP, S3 and bi-basal crackles. Atrial fibrillation on ECG.

Blood pressure 150/90 mmHg
Heart rate 144 /min
Oxygen saturation 89 %

KEY FACT

The **CHA_2DS_2-VASc** scoring system can estimate stroke risk in AF. Score of ≥2 in men or ≥3 in women: Recommend anticoagulation with a direct oral anticoagulant or warfarin. Anticoagulation may be considered at a lower score (1 in men, 2 in women):

- **C**HF (1 point)
- **H**TN (1 point)
- **A**ge ≥75 (2 points)
- **D**iabetes (1 point)
- **S**troke or TIA history (2 points)
- **V**ascular disease (1 point)
- **A**ge 65–74 (1 point)
- **S**ex **c**ategory (female) (1 point)

What is the CHADS2 score of this patient?

A. 2

B. 3

C. 4

**D. 5

Screening Hepatocellular

Which of the following diagnostic tools is the best option for screening for hepatocellular carcinoma in cirrhotic patients?

A. Liver function test

B. Alpha fetoprotein

**C. Ultrasound abdomen

D. Triphasic CT scan of liver

Hepatitis

A 36-year-old man presented to the clinic for evaluation of elevated liver enzyme. He is asymptomatic with no significant past medical history. He is a smoker and drinks alcohol every weekend. Examination was unremarkable (see lab results and reports).

Test Result Normal Values
Total bilirubin 12 3.5-16.5 µmol/L
Aspartate aminotransferase 147 12-40 IU/L AST > AST
Alanine aminotransferase 76 5-40 IU/L
Alkaline phosphatase 119 39-117 IU/L
Albumin 33 34-56 g/L
↑ Iron 35 11.7-31.8 µmol/L (Male)
9-30.4 µmol/L (Female)
Total iron binding capacity 34 11.6-31.3 µmol/L (Male)
9-30.4 µmol/L (Female)
↑ Ferritin 423 20-300 µg/L (Male)
20-120 µg/L (Female)

Liver function tests:
Hepatitis screen; Negative HCV, HBsAg was negative with positive HBsAb.

US Abdomen:
Enlarged liver with no focal lesion.

Which of the following is the most likely cause for his underlying liver disease?

A. Hemochromatosis

**B. Alcoholic hepatitis

C. Hepatocellular carcinoma

D. Chronic hepatitis B infection

Cirrhosis
Hepatitis
Varices
Tense
ascites

A 67-year-old man a known case of HCV cirrhosis admitted to Emergency Room with massive hematemesis. Variceal bleeding is suspected. On examination, he is drowsy with tense ascites (see lab results).

Blood pressure 110/70 mmHg
Heart rate 86 /min
Oxygen saturation 95 %

Test Result Normal Values
Hb 8 130-170 g/L (Male)
120-160 g/L (Female)
INR 1.3 0.8-1.2

Which of the following management options has a great benefit in reducing this patient mortality?

A. Octreotid

**B. IV ceftriaxone

C. Blood transfusion

D. Panataprazole infusion

Hepatitis
Chronic
Embolisation

A 42-year-old man with hepatitis B cirrhosis evaluated for focal lesion at US abdomen. He is asymptomatic. Currently on diuretics with well-controlled ascites (see lab results and report).

Test Result Normal Values
Hb 110 130-170 g/L (Male)
120-160 g/L (Female)
Platelets count 123 150-400 x 109/L
INR 1.5 0.8-1.2
Total bilirubin 16 3.5-16.5 µmol/L
Aspartate aminotransferase 98 12-40 IU/L
Alanine aminotransferase 65 5-40 IU/L
Alkaline phosphatase 120 39-117 IU/L
Albumin 30 34-56 g/L

CT scan of liver:
Demonstrated a 6 cm lesion with arterial enhancement at RT lobe, portal vein and hepatic veins were patent.

Which of the following is the best treatment option?

A. Sorafenib

B. Liver transplant

C. Surgical resection

**D. Transarterial chemoembolisation

Heartburn

A 22-year-old pregnant woman complains of heartburn, which is mainly at night after the dinner when she is lying on the bed. She was started on antacid syrup with somewhat response to

that. She denies history of abdominal pain or nausea.

Which of the following is the best next step in the management?

A. Start panotprazole

B. Ambulatory pH testing

**C. Lifestyle modifications

D. Perform upper endoscopy

TCA

A 24-year-old woman presents with 9-months of intermittent abdominal pain and anxiety. Occasionally, the pain associated with loose motions. She denies any alarm symptoms. All basic work-up (CBC, LFT, TSH, CRP and Celiac serology) were normal. Stool C/S and fecal calprotein was negative.

Which of the following is the most appropriate treatment?

A. Metronidazole

B. Increase fibre intake

C. Trial of gluten free diet

**D. Tricyclic antidepressants

Lower GI bleed
Diverticulosis

A 62-year-old man with no significant medical history presented to Emergency Room with 1-day history of 4 episodes of hematochezia. He denies history of abdominal pain, constipation or weight loss.

Blood pressure 90/50 mmHg
Heart rate 112 /min

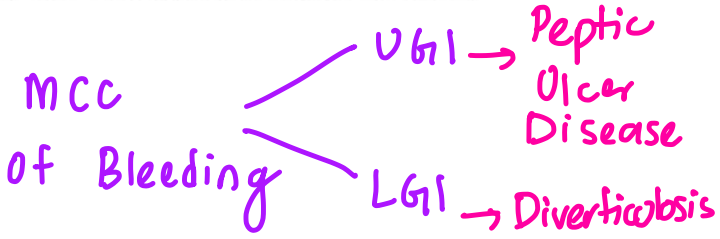

Which of the following is the most likely diagnosis?

A. Cecal cancer

**B. Diverticulosis

C. Internal piles

D. Ischaemic colitis

Crohns

A 25-year-old woman presented with few months history of increase forgetfulness, fatigue and numbness of lower limbs. She is a known case of crohn's disease, post terminal ilium resection 2 years ago. She is on azathioprine. She denies abdominal pain or diarrhoea (see lab results).

Test Result Normal Values
RBC 4.5 4.7-6.1 x 1012/L (Male)
4.2-5.4 x 1012/L (Female)
Hb 90 130-170 g/L (Male)
120-160 g/L (Female)
MCH 38 28-33 pg/cell
MCV 99 80-95 fl
Platelets count 199 150-400 x 109/L

A deficiency of which of the following nutrients would be responsible for her current clinical presentation?

A. Zinc

B. Thiamine

C. Selenium

**D. Vitamin B12

Murmur
TOF

A 23-year-old woman evaluated for dyspnoea and recurrent palpitation. She has a history of Fallot tetralogy repair at the age of 3. On cardiac examination, apex was normal with left parasternal impulse. S1 is single with grade 2/4 decrescendo diastolic murmur that increases with inspiration noted at left sternal border.

Blood pressure 110/70 mmHg
Heart rate 94 /min
Oxygen saturation 92 %

* Pulmonary Regurg. Murmur (Early Diastolic - Decrescendo) is common after surgical relief of Pulmonary Stenosis in TOF.

- Overriding aorta
- Pulmonary stenosis
- Right ventricular hypertrophy
- Ventricular septal defect (VSD)

Which of the following is the most likely diagnosis?

A. Mitral valve stenosis

B. Ventricular septal defect

C. Tricuspid valve regurgitation

**D. Pulmonary valve regurgitation

Endocarditis
Murmur

A 22-year-old woman presents with fatigue, SOB, arthralgia and fever for 2 weeks. It is worsened with time specially the fever. She has no significant medical history apart from sore throat 3 weeks ago and dental extraction 2 months ago. Skin examination revealed petechiae over lower limb. Cardiac examination demonstrated 3/6 holosystolic murmur that radiates to axilla and mild splenomegaly (see report).

6th June DHA

Blood pressure 100/60 mmHg
Heart rate 88 /min
Temperature 38.5 °C

Urine dipstick:
Showed mild proteinuria and microscopic hematuria.

Which of the following is the most likely diagnosis?

A. Lymphoma

**B. Infective endocarditis

C. Group A streptococcus infection

D. Systemic lupus erythematosus

Cardiomyopathy
S3

A 30-year-old woman is admitted with dyspnea, SOB, PND and orthopnea 3 days post vaginal delivery. She gave a history of lower limb oedema. She has no significant medical history. On examination, she looks in distress with bilateral LL pitting oedema, bilateral basal crackles on lung examination. On cardiac examination, apex was displaced down with pan-systolic murmur at the apex radiating to axilla and S3 gallop.

Blood pressure 90/60 mmHg
Heart rate 110 /min
Temperature 37.6 °C

Which of the following is the most likely diagnosis?

A. Viral myocarditis

B. Puerperium sepsis

C. Infective endocarditis

**D. Per-partum cardiomyopathy

Peripartum Cardiomyopathy
Rx
- ACEIs/ARBs ← CI if still pregnant
- Beta blockers
- Spironolactone
- Diuretics
- Digoxin

Invest: ECHO

Peripartum

A 30-year-old woman is admitted with cough, dyspnea, chest pain, SOB, PND and orthopnea 3 days post vaginal delivery. She gave a history of lower limb oedema. She has no significant medical history. On examination, she looks in distress with bilateral LL pitting oedema, bilateral basal crackles on lung examination. On cardiac examination, apex was displaced down with pan-systolic murmur at the apex radiating to axilla and S3 gallop

Blood pressure 90/70 mmHg
Heart rate 120 /min
Temperature 37.6 °C
Oxygen saturation 90 %

Which of the following is the most appropriate step in this patient management?

**A. Echocardiography

B. Thallium stress test

C. ECG and Chest x-ray

D. Cardiac MRI and PFT

A 59-year-old man comes to the clinic, with a 45 cigarette pack-year history, complaining of breathlessness on exertion and a productive cough of white sputum over the last 6 months. Cardiological investigations are normal (see report).

Spirometry:
Shows an FEV1/FVC of 60% with minimal reversibility after a 2-week trial of oral steroids.

Which of the following is the most likely diagnosis?

A. Asthma

B. Lung fibrosis

C. Left ventricular failure

**D. Chronic obstructive pulmonary disease

A 62-year-old woman is seen in the clinic with a history of weight loss, loss of appetite and shortness of breath for the last 6 weeks. On examination, trachea is shifted to left side; there is reduced air entry and dullness to percussion on the lower to midzones of the right lung.

Blood pressure 110/70 mmHg
Heart rate 102 /min
Respiratory rate 22 /min
Temperature 37 °C
Oxygen saturation 91 %

Which of the following is the most likely diagnosis?

**A. Right-sided pleural effusion

B. Right middle lobe pneumonia

C. Pulmonary embolism

D. Right pneumothorax

A 19-year-old man known to have asthma. He has never been admitted to hospital with an asthma exacerbation and experiences symptoms once or twice a week but he is not on any medication. Today he come to discuss the treatment options and he prefer to start medications only if needed during the attacks. His peak expiratory flow reading is currently 85% of the normal predicted value expected for his age and height.

Which of the following is the most appropriate first step in treatment?

**A. Short-acting beta-2 agonist inhaler

B. Long-acting beta-2 agonist inhaler

C. Leukotriene receptor antagonists

D. Low-dose steroid inhaler

A 40-year-old man diagnosed with pulmonary TB who started treatment 3 months ago, presents to the clinic with a week's history of pins and needles in his hands and feet with associated numbness. He tells that his symptoms started since he stopped taking the vitamins given to him at the start of his TB treatment. 6th June DHA

Which of the following drugs is responsible for the symptoms described by the patient?

A. Pyrazinamide

B. Ethambutol

C. Rifampicin

**D. Isoniazid

An 18-year-old woman complains of dizziness feeling light-headed frequently with standing up and weight loss around 5 kg over the last 5 months. She has noticed a recent scar on the back

Synacthen
Hyperpigmentation
Adrenal

of her hand, which has started to turn very dark.

Blood pressure 90/60 mmHg
Heart rate 99 /min

What is the most appropriate investigation to confirm the diagnosis?

A. Low-dose dexamethasone test

B. Abdominal ultrasound scan

C. Cortisol measurement

**D. Synacthen test

A 70-year-old man was hospitalized 6 days ago for a 4-day history of acute leg ischemia treated with angioplasty and stenting. He is now asymptomatic. He has a history of stage 3 chronic kidney disease and hypertension that is well-controlled with diltiazem and captopril. Other medications are aspirin and clopidogrel. On physical examination, the patient is afebrile and normal blood pressure. The remainder of the examination is unremarkable (see lab results).

Test Result Normal Values
Creatinine 140 44-115 µmol/L
Total Cholesterol 5.9 <5.1 mmol/L
LDL (cholesterol) 4.9 <4.0 mmol/L

Which of the following is the most appropriate therapy for secondary prevention of cardiovascular disease in this patient?

A. Niacin

B. Ezitimibe

**C. Rosuvastatin

D. No additional treatment

A 43-year-old woman is evaluated during a follow-up visit. She is overweight and has hypertension and type 2 diabetes mellitus, both of which are well controlled. For several years, she has attempted to lose weight through various commercial diets; dietician-monitored, calorie-restricted diets; and physical activity but her weight has remained stable. Head, neck, lung, and heart examinations are normal.

Blood pressure 110/70 mmHg
Heart rate 76 /min
Respiratory rate 13 /min
Temperature 36.6 °C
BMI 28,5 kg/m2

In addition to continuing calorie restriction and exercise, which of the following is the most appropriate management to help this patient achieve weight loss with tolerable side effect?

**A. Orlistat

B. Lorcaserin

C. Phentermine-topiramate

D. Roux-en-Y gastric bypass

A 48-year-old woman had terminal ileum resection due to Crohn's disease. She presents this time with difficulty in walking. She is anaemic and has lost position sense bilaterally.

Which of the following is the most likely diagnosis?

A. Aplastic anaemia

B. Folate deficiency

C. Haemolytic anaemia

**D. Vitamin B12 deficiency

A 46-year-old man presents with a 1-day history of abdominal pain, vomiting and hematemesis. History reveals he is a heavy alcohol drinker. He has previously been admitted with peptic ulceration and is receiving proton pump inhibitor therapy. On examination, he has tenderness over the epigastrium.

Blood pressure 110/69 mmHg
Heart rate 112 /min

Which of the following is the most likely diagnosis?

A. Acute pancreatitis

B. Chronic pancreatitis

**C. Oesophageal varices

D. Pancreatic pseudocyst

Cystic fibrosis

A 22-year-old woman with cystic fibrosis presents with a 4-month history of weight loss, diarrhoea and abdominal bloating. She has pale stools. There are no specific abnormalities on examination of the abdomen other than she is clubbed with scattered chest crackles.

Which of the following is the most likely diagnosis?

A. Acute pancreatitis

B. Pancreatic carcinom

C. Pancreatic pseudocys

**D. Chronic pancreatitis

Pancreatic insufficiency (90% of cases) with steatorrhea and vitamin A, D, E, and K malabsorption

Gilbert

A 30-year-old man comes to the clinic to discuss his recent blood test results. A few months ago, he had a health visit that showed an abnormality on his liver function tests when the bilirubin level of 41 mol/L (normal 3-20) with the remainder of the liver function profile being within normal limits. He has no significant medical history. On examination, no significant findings. The physician orders second blood test, results show a normal full blood count, renal

function and thyroid function. The liver function test is done (see lab results).

Test Result Normal Values
Alkaline phosphatase 115 39-117 IU/L
Alanine aminotransferase 38 5-40 IU/L
Direct bilirubin 7 1.5-6.5 µmol/L
Total bilirubin 42 3.5-16.5 µmol/L

Which of the following is the most likely diagnosis?

A. Cholestasis

B. Viral hepatitis

**C. Gilberts syndrome

D. Haemochromatosis

A 61-year-old man complains of indigestion that has been bothering him for the past 2 months. He has never had these symptoms before and he is eating and drinking well. He says he has lost weight over this period. His bowel habits are normal and he does not complain of any abdominal pains. Abdominal examination is normal. Blood tests including full blood count, renal function, and liver function as well as C-reactive protein are normal.

Which of the following is the best management plan?

**A. Urgent endoscopy

B. Routine abdominal ultrasound

C. Abdominal and erect X-ray today

D. Routine referral to gastroenterology

CKD
Mortality
IHD

6th June DHA

A 58-year-old man with chronic kidney disease has been on haemodialysis for chronic kidney disease for the past 8 years.

What is most likely cause of mortality in such case?

**A. Ischaemic heart disease

B. Dialysis related sepsis

C. Hyperkalaemia

D. Malignancy

A 29-year-old man diagnosed with coeliac disease 2 years ago. He complains of ongoing diarrhoea, feeling tired and bloating. Poor compliance with a gluten-free diet is suspected.

Which of the following is the most appropriate method to ascertain this?

A. Food diary

B. Refer for a duodenal biopsy

C. Anti-endomysial antibodies

**D. Tissue transglutaminase antibodies

BNP

A 61-year-old man with suspected left ventricular heart failure. He had B-type natriuretic peptide (BNP) test, which came back as being slightly elevated.

Which of the following factors cause a falsely elevated BNP?

A. ACE inhibitor therapy

B. Furosemide

C. Obesity

**D. COPD

(N) BNP → EXCLUDES
- CHF
- Pulmonary Edema

Vomiting
Diarrhoea

A 22-year-old woman develops severe vomiting 4 hours after having lunch at a restaurant.

What is the most likely causative organism?

A. Shigella

B. Campylobacter

C. Escherichia coli

**D. Staphylococcus aureus

Which of the following extra-intestinal manifestations of Crohn's disease activity?

A. Clubbing

**B. Erythema nodosum

C. Pyoderma gangrenosum

D. Primary sclerosing cholangitis

Celiac

A 28-year-old woman comes to the clinic for a check-up. She believes that she is allergic to wheat; her symptoms of abdominal bloating and loose stool have improved over the past few months by eating a gluten-free diet.

Which of the following is the most appropriate advice to her?

A. Dietician referral

B. Gastroenterology referral

C. No need to Continue on gluten-free diet

**D. Resume eating gluten, bloods for celiac screen

COPD
PO2

A 58-year-old man with chronic obstructive pulmonary disease (COPD) is ready to be discharged home after acute exacerbation of the disease.

Which of the following parameters indicate offering long-term oxygen therapy?

A. 1 arterial blood gas measurement with pO2 < 7.7 kPa

**B. 2 arterial blood gases measurements with pO2 < 7.3 kPa

C. 1 arterial blood gas measurement with pO2 < 8.0 kPa

D. 2 arterial blood gases measurements with pO2 < 6.3 kPa

A 27-year-old man who has a sister with adult polycystic kidney disease came to screen for the disease.

Which of the following is the most appropriate screening test?

A. CT abdomen

B. Urine microscopy

**C. Ultrasound abdomen

D. Anti-polycystin 1 antibodies levels

CKD

A 61-year-old man with stable chronic kidney disease stage 3.

Which of the following drugs is it safe to prescribe for this patient?

A. Nitrofurantoin

B. Metformin

**C. Warfarin

D. Lithium

Drug Interaction
Clopidogrel

A 57-year-old man who is intolerant of aspirin is started on clopidogrel for the secondary prevention of ischemic heart disease.

Which of the following drugs can make clopidogrel less effective?

A. Warfarin

**B. Omeprazole

C. Beta blockers

D. Selective serotonin reuptake inhibitors

Hepatitis
Vaccine

A nurse is bitten by a patient who is known to have hepatitis B. She has a documented full history of hepatitis B vaccination and was known to be a responder.

What is the most appropriate action to reduce the chance of contracting hepatitis B?

A. Give hepatitis B immune globulin + hepatitis B vaccine booster

B. Give hepatitis B immune globulin

**C. Give hepatitis B vaccine booster

D. Give oral ribavirin for 4 weeks

A 44-year-old man who was recently diagnosed as chronic kidney disease stage 4, presented to the clinic to discuss the diet in regard to his condition. He has read that potassium rich food should be consumed in moderate amount.

Which of the following foods should he eat in moderation?

A. Grapes

**B. Tomatoes

C. Green beans

D. Cranberry juice

Hepatitis
Serology

A 40-year-old woman is noticed to be jaundiced (see lab

Test Result
Anti-HBs Negative
Anti-HBc Positive
HBs antigen Positive
IgM anti-HBc Negative

What is the patient's hepatitis B status?

**A. Chronic hepatitis B

B. Acute hepatitis B infection

C. Previous hepatitis B infection

D. Previous immunisation to hepatitis B

TABLE 2.6-19. Key Hepatitis Serologic Markers

SEROLOGIC MARKER	DESCRIPTION
IgM HAVAb	IgM antibody to HAV; the best test to detect acute HAV
HBsAg	Antigen found on the surface of HBV; continued presence indicates carrier state
HBsAb	Antibody to HBsAg; indicates immunity to HBV
HBcAb	Antibody to HBcAg; IgM ⊕ during the window period IgG HBcAb is an indicator of prior or current infection
H**Be**Ag	A different antigenic determinant in the HBV core An important indicator of transmissibility (**Be**ware!)
HBeAb	Antibody to e antigen; indicates low transmissibility

	Surface antigen	A-antigen	Core antibody	Surface antibody
Acute or chronic infection	Positive	Positive	Positive IgM or IgG	Negative

	Surface antigen	A-antigen	Core antibody	Surface antibody
Resolved, old, past infection	Negative	Negative	Positive IgG	Positive
Vaccination	Negative	Negative	Negative	Positive
"Window period"	Negative	Negative	Positive IgM, then IgG	Negative

UTI
Pregnant
Nitrofurantoin

A 28-year-old woman who is 38 weeks pregnant presents with dysuria and urinary frequency. A urine dipstick is positive for nitrites and leucocytes.

6th June DHA

Which of the following is the most appropriate management?

**A. Cefalexin

B. Doxycycline

C. Nitrofurantoin

D. Advise to increase fluid intake

1st Trimester & >37 wks
GIVE AUGMENTIN/Amoxicillin
Cefalexin
AVOID NITROFURANTOIN

A 36-year-old man has just completed a 2-week course of Helicobacter pylori therapy for dyspepsia. He has stopped his eradication therapy today and he wants to repeat the test.

How soon can the test be re-performed to test for eradication?

**A. In 4 weeks

B. In 2 weeks

C. In 1 weeks

D. Straight away

IBS

A 28-year-old woman with irritable bowel syndrome comes to the clinic complaining that loperamide and antispasmodic medication have not eased her symptoms. She has no new symptoms suggestive of any serious condition.

Which of the following is the most appropriate treatment?

A. Cognitive behaviour the rap psychological therapy

**B. Tricyclic antidepressant

C. Psychological therapy

D. Acupuncture

Hepatitis
Non alcoholic
Prevention

A 44-year-old woman is diagnosed with non-alcoholic steatohepatitis following a liver biopsy.

What is the single most important step can help to prevent the progression of her disease?

**A. Weight loss

B. Stop smoking

C. Start statin therapy

D. Eat more omega-3 fatty acids

Atrial fibrillation
ACS
Warfarin

6th June DHA

A 77-year-old man with a history of atrial fibrillation is admitted to the hospital following an acute coronary intervention and treated with a percutaneous coronary intervention. His medication on admission were warfarin, paracetamol and allopurinol. Antithrombotic therapy immediately given after his event.

Which of the following regimen should he be prescribed?

**A. Continue warfarin with the addition of 2 antiplatelets

B. Stop warfarin, start 3 antiplatelets

C. Stop warfarin, start 2 antiplatelets

D. Continue warfarin monotherapy

ACE
Side Effects

A 59-year-old man presents 4 weeks after being discharged from hospital. He had been admitted with chest pain and thrombolysed for a myocardial infarction. 2 days later, he developed marked tongue and facial swelling. His vital signs are within the normal limits.

Which of the following drugs is most likely to be responsible?

A. Atenolo

**B. Ramipril

C. Aspirin

D. Atorvastatin

HTN
Uncontrol
Thiazide diuretic.
Indapamide

A 66-year-old man with hypertension comes to the clinic for a follow-up. He is currently taking a combination of losartan and amlodipine, which is failing to keep his blood pressure within target. Examination is unremarkable. His blood test and renal function profile were within the normal limits.

What is the most appropriate next step assuming he has no relevant contraindications?

A. Add ramipril 1.25mg od

B. Add atenolol 50mg od

C. Add doxazosin 1mg od

**D. Add indapamide MR 1.5mg od

Asthma

A 51-year-old woman with asthma complaining of increasing shortness of breath and wheeze in the past few hours. She has a long-standing diagnosis of asthma but her medication history suggests a lack of compliance. Her best peak flow measurements in previous consultations have been 300 L/min.

Which of the following features suggests acute severe asthma in this patient?

A. Heart rate 100/min

B. Respiratory rate >20/min

C. Peak flow rate 200 L/min

**D. Inability to complete sentences in one breath

Asthma
Exacerbation
PEF

A 31-year-old man with asthma complaining of increasing wheeze in the past few hours. His medication history suggests a lack of compliance. His best peak flow measurements in previous consultations have been 600 L/min.

Which of the following features suggests acute severe asthma in this patient?

ASTHMA EXACERBATION

PEF < 250 L/min

RR > 25 /min 33-50% of predicted

HR > 110 bpm

**A. A peak flow rate of 250 L/min

B. Respiratory rate >20/min

C. Heart rate 100/min

D. SpO2 95%

Asthma
Side effects

Steroids side effects

A 22-year-old man, whose asthma is uncontrolled on beta agonist therapy, is commenced on a steroid inhaler.

SILENT CHEST

SpO_2 < 92%

Which of the following is the most likely adverse effect?

**A. Dysphonia

B. Dental abscess

C. Peptic ulceration

D. Thrombocytopaenia

Clubbing

A 58-year-old man presents with a 6-month history of breathlessness. He has been smoking all his adult life, he smokes 10-15 cigarettes per day. On examination, he has lost the nail fold angle of his fingers.

Which of the following is the most likely diagnosis?

A. Chronic obstructive pulmonary disease

**B. Bronchial carcinoma

C. Aspergillosis

D. Asthma

Asthma

A 36-year-old man with multiple health problems presents to the Emergency Department with an episode of bronchospasm. He has a history of asthma and hypertension. He is undergoing a medication review.

Which of the following medications is most likely to be responsible?

A. Salmeterol

**B. Atenolol

C. Ramipril

D. Aspirin

Vaccine
Immunisation

A 21-year-old man presents with paroxysms of coughing for the past week, following a mild flue illness. The paroxysms have been so severe that they have resulted vomiting and chest pain. He had been immunised for pertussis as a child.

What is the best advice about the protection following immunisation?

A. Immunisation offers lifelong immunity against pertussis

**B. Immunity following immunisation wanes within 3 years

C. Immunity following immunisation wanes within 10 years

D. Immunity following immunisation wanes after 25 years

A 31-year-old man with asthma complaining of increasing wheeze in the past few hours. He rarely attends asthma clinic and his previous best peak flow readings has been 400 L/min.

Which of the following would suggest acute severe asthma?

A. O2 saturation <95%

**B. Respiratory rate >25

C. Carotid pulse >100 bpm

D. Peak flow rate <300 L/min

Asthma

A 38-year-old woman presents for annual asthma review. Her symptoms are very well controlled and she has not had any attacks since her last review a year ago and has not used her salbutamol inhaler once in that year. She is prescribed an inhaled beclomethasone steroid twice daily in addition to her salbutamol inhaler.

What is the most appropriate next step in modifying her medication?

A. Add a leukotriene receptor antagonist

B. Double the dose of the inhaled corticosteroid

C. Stop both the salbutamol and beclomethasone inhalers

**D. Half the beclomethasone dose and review in 6 months

Risk factor
Pneumothorax
Smoking

A 38-year-old man is admitted with a sudden onset dyspnoea and pleuritic chest pain. He is a smoker but has no history of respiratory disease. He considers himself healthy and regularly plays football. On admission, he has a chest x-ray that shows a pneumothorax with a 3cm rim of air. Aspiration is successful and he is discharged. A follow-up chest x-ray 2 weeks later shows a complete resolution.

What is the single most important piece of advice to reduce his risk of further pneumothoraces?

**A. Stop smoking

B. Avoid flying for 12 months

C. Avoid sports for 12 months

D. Arrange a course of respiratory physiotherapy pnemothorax

Asthma

A 28-year-old wood worker presents to the clinic complaining of episodic shortness of breath. He describes feeling wheezy and having a tendency to cough. A diagnosis of occupation asthma is suspected.

Which of the following is the most appropriate diagnostic investigation?

**A. Serial peak flow measurements at work and at home

B. Specific IgE measurements

C. Skin prick test

D. Patch testing

Restrictive lung
Disease
SOB

A 66-year-old man presents with shortness of breath. He smokes 20 cigarettes/day but is otherwise well. Spirometry shows a restrictive picture.

Which of the following is the most likely diagnosis?

**A. Pulmonary fibrosis

B. Bronchiectasis

C. Heart failure

KEY FACT

FEV_1/FVC ratio $<70\%$ suggests obstructive ventilatory defect (eg, asthma, bronchiectasis, COPD).

FEV_1/FVC ratio $\geq 70\%$ suggests restrictive ventilatory defect (eg, interstitial lung disease, neuromuscular diseases, obesity, scoliosis).

D. Asthma

Smoking
Cessation
Drug interactions

A 31-year-old man came for smoking cessation support as his father has recently been diagnosed with lung cancer. He has a past medical history of epilepsy, which is well-controlled on carbamazepine.

Which smoking cessation medication would be contraindicated for this patient?

A. Nicotine replacement therapy

B. E-Cigarettes

C. Varenicline

**D. Bupropion

LBBB
ECG
RBBB

A 47-year-old man presents with intermittent chest pains for the past 2 days. He complains of worsening pain. On examination, he tachycardic and sweaty. ECG is done (see image).

Blood pressure 133 /81 mmHg

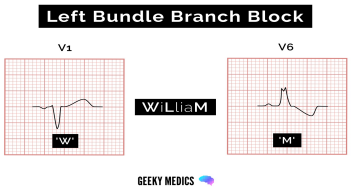

What does the ECG show?

A. Posterior myocardial infarction

B. Right bundle branch block

C. Ventricular tachycardia

**D. Left bundle branch block

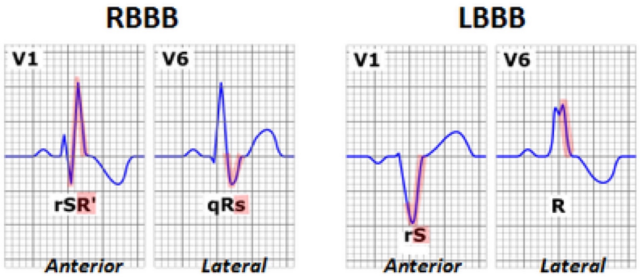

A 61-year-old man comes to the clinic with a 2-day history of dyspnoea on exertion. He has a long-standing hypertension and a 30-pack-year smoking history. Physical examination is unremarkable except for rare crackles at the bases of the lungs.

Which of the following tests would be most helpful for detecting left ventricular dysfunction?

**A. B-type natriuretic peptide (BNP)

B. C-reactive protein (CRP)

C. Creatinine Kinase (CK)

D. Troponin T

Urine albumin/creatinine
Microalbumin

6th June DHA

A 58-year-old man with diabetes mellitus came for follow-up. He is on metformin (Glucophage), 1000 mg/day, as well as atorvastatin (Lipitor), 40 mg daily for hyperlipidaemia. There is no diagnosis of hypertension. His urine albumin/creatinine ratio is in the microalbuminuria range for the first time (see lab results).

Blood pressure 128/77 mmHg

Test Result Normal Values
HbA1C 6.3 4.7-5.6 %
LDL (cholesterol) 2.1 <4.0 mmol/L

Which of the following would be most appropriate next step?

A. Renal ultrasonography

**B. Repeat urine albumin/creatinine ratio

C. Stopping metformin

D. 24-hour urine for microalbumin

PSGN
Sreptococci
Bloody urine
ASO

A 25-year-old woman presents with symptoms of extreme fatigue, no appetite, and bloody urine. She developed a very sore throat 3 weeks ago but did not have it examined or treated. 3 days ago, she began to have bloody urine and swelling of her hands and feet. Her past health has been excellent. There is no family history of significant illness. She has no allergies. On examination, she has significant edema of both lower extremities.

Blood pressure 166/108 mmHg
Heart rate 82 /min

PSGN (1-3 wk post infection)
↓
Streptococcus (MC)
(Gp A β-hemolytic)
• UA, ASO titer, anti DNA ase
Rx: Antibiotics + DIURETICS

Which of the following is the most likely diagnosis?

A. Berger disease

B. Immunoglobulin A nephropathy

**C. Poststreptococcal glomerulonephritis

D. Membranous glomerulonephritis

A 51-year-old man with chronic and progressing renal disease. His GFR is decreasing and most likely he will need dialysis sometime within the next year.

Which of the following will be the most likely cause of death in his case?

A. Renal failure

B. Coagulopathy

C. Pulmonary edema

**D. Cardiovascular disease

HTN
Asymmetrical kidneys

A 77-year-old man with a history of ischemic heart disease is seen in the Hypertension Clinic. He is taking 4 anti-hypertensives drugs. Physical examination is unremarkable. Abdominal ultrasound shows asymmetrical kidneys.

Blood pressure 169/99 mmHg
Heart rate 79 /min

Which of the following is the most likely diagnosis?

**A. Renal artery stenosis

B. Cushing's syndrome

C. Primary hyperaldosteronism

D. Adult polycystic kidney disease

Crohns

What is the most common location of Crohn's disease?

A. Ileal

B. Colonic

C. Duodenum

**D. Ileocolonic

Pt Inr
Jaundice

A 30-year-old woman presented with 1-week history of fatigue malaise and nausea. 2 days ago, she noticed yellowish discoloration of the sclera. She denied any history of abdominal pain or drugs intake. She has no significant medical history. On examination, she is jaundiced with no stigmata of chronic liver disease, conscious with no flapping tremors (see lab results).

Blood pressure 110/70 mmHg
Heart rate 76 /min
Temperature 36.6 °C

Test Result Normal Values
Direct bilirubin 108 1.5-6.5 µmol/L
Total bilirubin 129 3.5-16.5 µmol/L
Aspartate aminotransferase 1235 12-40 IU/L
Alanine aminotransferase 1987 5-40 IU/L
Alkaline phosphatase 156 39-117 IU/L
Gamma glutamyltransferase 60 6 to 37 IU/L
Albumin 41 34-56 g/L

Which of the following is the most appropriate management?

**A. Order PT, INR

B. Discharge her home

C. Admit and start IV dextrose

D. Refer her to liver transplant center

Diarrhoea
Watery

A 40-year-old man comes to the clinic complaining of diarrhoea and abdominal cramps. The symptoms started a day after he returned home from trip to India. The stool are watery with no mucus or blood.

Blood pressure 100/70 mmHg
Heart rate 98 /min
Temperature 37.3 °C

KEY FACT

Organisms that cause watery diarrhea include *Vibrio cholerae*, rotavirus, enteropathogenic *E coli* (ETEC), *Cryptosporidium*, *Giardia*, and norovirus.

Which of the following is the most likely pathogen?

KEY FACT

Organisms that cause bloody diarrhea include *Salmonella*, *Shigella*, enterohemorrhagic *Escherichia coli* (EHEC), and *Campylobacter*.

A. Rotavirus

**B. Escherichia coli

C. Bacillus cereus

D. Clostridum perfringens

A 60-year-old man with chronic hepatitis C and liver cirrhosis presented to Emergency Room with perforated peptic ulcer that requires urgent laparotomy (see lab results).

Test Result Normal Values
Hb 90 130-170 g/L (Male)
120-160 g/L (Female)
Platelets count 90 150-400 x 109/L
INR 2 0.8-1.2
Prothrombin time 17 10-13 sec

Which of the following is the most appropriate next step in the management prior to the procedure?

A. Platelets

B. Cryoprecipitate

**C. Fresh frozen plasma

D. Packed red blood cells

What is the recommended age for screening colonoscopy for average risk population?

A. 40

**B. 50

C. 55

D. 60

Jaundice
Abdominal Pain
ALP
BILIRUBIN

A 45-year-old obese woman presented with 1-week history of jaundice, anorexia and abdominal pain. She has no chronic illnesses and not on any medications. On examination, she is jaundiced with stable vital signs and no fever. Abdomen exam showed mild tender liver with span of 13 cm, no splenomegaly (see lab results).

Test Result Normal Values
RBC 4 4.7-6.1 x 1012/L (Male)
4.2-5.4 x 1012/L (Female)
Hb 110 130-170 g/L (Male)
120-160 g/L (Female)
Platelets count 212 150-400 x 109/L
WBC 18 4.5-10.5 x 109/L
Direct bilirubin 79 1.5-6.5 µmol/L
Total bilirubin 98 3.5-16.5 µmol/L
Aspartate aminotransferase 70 12-40 IU/L
Alanine aminotransferase 150 5-40 IU/L
Alkaline phosphatase 1000 39-117 IU/L

Which of the following is the next step in the management?

A. MRCP

B. Liver biopsy

**C. Abdominal ultrasound

D. Abdominal CT scan of the liver

Charcot

Charcot triad of fever, upper abdominal pain and jaundice is diagnostic of which of the following conditions?

A. Hepatitis

**B. Cholangitis

C. Pancreatitis

D. Cholecystitis

A 60-year-old woman with recent history of feeling tiredness, fatigue and weight loss. She noticed as well worsening of her chronic constipation. Stool for occult blood was positive (see lab results).

Test Result Normal Values
RBC 3 4.7-6.1 x 1012/L (Male)
4.2-5.4 x 1012/L (Female)
Hb 89 130-170 g/L (Male)
120-160 g/L (Female)
HCT 0.25 0.42-0.52 (Male)
0.37-0.48 (Female)
Platelets count 234 150-400 x 109/L

Which of the following is the best next step in diagnosis?

A. CT enterography

B. Barium enema

C. Sigmoidoscopy

**D. Colonoscopy

Ethics

A 48-year-old woman with 4-months history progressive dysphagia for solid and liquid and she noticed as well weight loss. Lab investigation was normal apart from mild anaemia. Upper GI endoscopy was recommended but she refused as her relative died post colonoscopy.

Which of the following is the best next action?

**A. Explore her concern

B. Discharge her from the clinic

C. Ask her son to sign the consent

D. Call for a meeting with the family

Ethics
Polyposis syndrome

A 20-year-old man present to the clinic for advice. He has a positive family history of familial polyposis syndrome. He is asymptomatic with normal Lab tests.

Which of the following is the best advice at this stage?

A. Close follow-up

**B. Order colonoscopy

C. Tumour markers panel

D. His risk is very low and no further action

Ethics

A 55-year-old man presented to the Colonoscopy Unit to perform screening colonoscopy. The consent was taken and procedure started. During colonoscopy, a large polyp 4 cm was seen which need to be removed by snare polypectomy which carries a high risk of bleeding and perforation than the screening colonoscopy.

Which of the following is the best action?

A. Perform the polypectomy

B. Ask the relative to sign the new consent

C. Let the patient sign after the procedure

**D. Repeat the procedure with high risk consent

Ethics

A 32-year-old man with 1-year history of intermittent dysphagia for solid with no other alarm symptoms. He has no chronic medical illness. Upper GI endoscopy was recommended but he refused the procedure.

Which of the following is the best next action?

A. Discharge from the clinic

B. Ask the brother to sign the consent

C. Show him that you are upset with his decision

**D. Discuss with him other alternative like barium swallowing

A 30-year-old woman presented with hematemesis after a bout of prolonged vomiting. She has no significant medical history and not on any medications.

Which of the following is the most likely diagnosis?

A. Gastritis

B. Duodenal ulcer

**C. Mallory-Weiss tear

D. Barrett's oesophagus

Crohns
Diarrhoea
Cholestyr

A 32-year-old man diagnosed with fibrostenotic ileal crohn's disease underwent ileocecal resection of 70 cm from the ileum. 1-month post-operative, started to complain of diarrhoea watery 5 times/day with no mucus or blood. No history of abdominal pain. On examination, he is unremarkable. All basic work up was normal including stool culture (see lab result and report).

Test Result Normal Values
ESR 7 2-10 mm/h (Male)
3-15 mm/h (Female)

CT scan of abdomen:
Showed normal anastmosis site.

Which of the following is the most appropriate treatment?

A. Mesalamine

B. Prednisolone

C. Metronidazole

**D. Cholestyramine

Lupus Nephritis
SLE
Biopsy

6th June DHA

A 45-year-old woman with systemic lupus erythematosus comes for routine follow-up visit. She was asymptomatic and currently on no medications. Her condition is stable for several years (see lab results).

Blood pressure 140/90 mmHg

Test Result Normal Values
24 hr urine protein 35 0.8-14 mg/dl (Male)
2.5-11 mg/dl (Female)
Protein 500 0-150 mg/24 hr
RBC 5000 up to 4,000 in 1 ml
Urea 20 2.75-7.4 mmol/L
Creatinine 160 44-115 µmol/L

Lupus Nephritis

Which of the following is the most appropriate next step in management?

A. Anti Ds-DNA

**B. Renal biopsy

C. Doppler renal ultrasound

D. Repeat urine analysis in next visit

Hypercalciuria
Hypercalcemia
Stone
Thiazide
Ala Medicine

Which of the following is the most useful therapy to reduce stone formation in a patient with hypercalciuria?/hypercalcemia

A. Allopurinol

B. Pencillamine

Losartan (ARB) lowers uric acid. It is the best drug for BP in gout.

🍓 case about hyperuricemia and negative birefringent urate crystal, how to manage?
Probenecid ✅✔ is a medication that increases uric acid excretion in the urine. It is primarily used in treating gout and hyperuricemia.

Most effective method to decrease stone formation in patient with **hypercalcemia**?
A. decrease protein B. **thiazide** C. allopurinol D. decrease calcium intake

**C. Thiazide diuretics

D. Dietary calcium restriction

CKD

A 50-year-old man presented to the clinic with recent onset of numbness of his feet and hands .History revealed he has chronic kidney disease for 3 years. Examination showed decrease sensation to pinprick and vibration stimuli below the knee with absent ankle reflexes (see lab results).

Blood pressure 140/90 mmHg

Test Result Normal Values
RBC 4 4.7-6.1 x 1012/L (Male)
4.2-5.4 x 1012/L (Female)
Hb 9 130-170 g/L (Male)
120-160 g/L (Female)
MCV 73 80-95 fl
Potassium 5.3 3.5-5.1 mmol/L
Urea 46 2.75-7.4 mmol/L
Creatinine 674 44-115 µmol/L

Which of the following is the most appropriate next step in the management?

A. Erythropietin

B. Oral bicarbonate

C. Vitamin B complex

**D. Initiation of dialysis

AV Block

A 65-year-old man presents with severe chest pain to Emergency Room. ECG showed st segment elevation of inferior leads. He received thrombolytic therapy (tPA). 3 hours later, started to feel dizzy. ECG showed 2:1 AV block. IV atropine given with no effect.

Vital signs 3 hours later: Blood pressure 80/45 mmHg
Heart rate 39 /min
Respiratory rate 18 /min
Oxygen saturation 90 %

Which of the following is the best management option?

A. IV fluid

B. Dopamine

C. Isoprenaline

**D. Temporary pacemaker

Inferior MI
heart block

A 65-year-old man presented to Emergency Room with severe chest pain. He was diagnosed as inferior MI and received thromolytic therapy (tPA). Few hours later, he developed dizziness. ECG is done (see image).

Blood pressure 80/50 mmHg
Heart rate 41 /min

Which of the following is the most likely diagnosis?

A. 1st degree heart block

**B. 2nd degree heart block

C. 3rd degree heart block

D. 4th degree heart block

Pregnant
Mitral stenosis
SOB

A 34-year-old woman presented to the clinic with new onset SOB and fatigue. She is diagnosed as a case of mitral stenosis with pulmonary hypertension. She is planning to get pregnant and she is hiding the diagnosis from her husband.

Which of the following is the most appropriate advice?

A. Close monitor and follow-up

B. She can go ahead with her plan

C. Call her husband and tell him the diagnosis

**D. Counselling her about the risk and squally of the pregnancy

Murmur
Aortic Regurg

A 33-year-old man presented with shortness of breath, orthopnea and paroxysmal nocturnal dyspnea. Exanimation revealed collapsing pulse and wide pulse pressure. Early diastolic murmur over left sternal border and pistol-shot sound heard over femoral arteries.

Which of the following is the most likely diagnosis?

A. Coarctation of aorta

**B. Aortic regurgitation

C. Cardiac tamponade

D. Ventricular septal defect

A 55-year-old patient comes to the clinic. He is hypertensive and on captopril. ECG showed tall, tented T waves.

Which of the following is the best next step in management?

A. Reassurance

B. Order cardiac enzyme

**C. Check potassium level

D. Admit him with urgent echo

CHF
SOB

A 70-year-old woman known to have chronic heart failure resented with sever shortness of

breath, paroxysmal nocturnal dyspnea and orthopnea. On examination, she looks unwell, high JVP with bilateral basal crackles at both lungs. S3 was heard at the apex.

Blood pressure 110/70 mmHg
Heart rate 100 /min
Oxygen saturation 88 %

Which of the following is the best next step in management?

A. 100% O2

B. Metalazone

**C. IV furosemide

D. Order urgent echo

S3 gallop
CHF
Orthopnea
Pulmonary edema

A 65-year-old woman known to have heart failure presented with sever shortness of breath, paroxysmal nocturnal dyspnea and orthopnea. On examination, she looks unwell, high JVP with bilateral basal crackles at both lungs. S3 was heard at the apex.

Blood pressure 100/70 mmHg
Heart rate 93 /min
Oxygen saturation 88 %

Which of the following is the most likely diagnosis?

A. Myocardial infarction

**B. Pulmonary oedema

C. Right-sided heart failure

D. Acute mitral regurgitation

Bradycardia

A 24-year-old athlete man attended routine clinic visit. He is asymptomatic and has no significant past medical history but found to have a resting pulse of 47 beat/min, normal blood pressure and cardiac examination. Normal CBC, renal function, LFT, and TSH. ECG normal only sinus bradycardia.

Which of the following is the best advice?

**A. Reassurance

B. Order urgent echo

C. Genetic counselling

D. Repeat ECG every 3 months

CHF

A 67-year-old woman diagnosed with heart failure being treated with loop diuretic and ACE inhibitor with good control of her symptoms.

Which of the following medications helps in reducing her long-term mortality?

A. Digoxin

B. Nifedipine

C. Amiodarone

**D. Spironolactone

Atrial fibrillation
Thromboembolism

A 67-year-old diabetic patient with atrial fibrillation is hesitant to start anti-coagulant due to its risk of inducing bleeding.

Which of the following factors is the most important in making the decision?

A. The patient has no risk for bleeding

B. The patient has mild risk of thrombosis

C. The bleeding risk is higher than thrombosis risk

**D. His risk of thromboembolic events is higher than bleeding

ETHICS

A 60-year-old woman admitted to the hospital for cardiac catheterization but she is concerned about its complications.

Which of the following is the best way to address her concerns?

A. Tell her it is very rare and no need to worry

B. Inform her that her husband will sign the consent

C. Listen to her concern and explain what are the expected complications

**D. Listen to her concern and explain what are the expected complications and give alternative

Asthma
CHF
Hypokalemia

A 57-year-old man with known history of asthma, congestive heart failure and peptic ulcer disease was admitted with asthma exacerbation and rapid atrial fibrillation. He was managed with nebulized salbutamol, IV digoxin, and his home medications was continued (ACE inhibitor, Ranitidine, Spironolactone). 24 hours later, his serum potassium is noted to be 2.8 mEq/L.

Which of the following medications is the most likely to cause this abnormality?

A. Digoxin

B. Ranitidine

**C. Salbutamol

D. Spironolactone

WPW Syndrome
Palpitations
Syncope

A 21-year-old woman with history of recurrent palpitations, light-headedness and 2 attacks of fainting. ECG showed short PR interval and Inferior leads Q waves. She was diagnosed as Wolf-Parkinson-White (WPW) syndrome. She was given atenolol with no response.

Which of the following is the best management option?

A. Digoxin

WPW syndrome constitutes a group of ECG findings when there is an abnormal fast accessory conduction pathway from atria to ventricle (bundle of Kent) that bypasses the AV node and causes preexcitation of the ventricles. It is commonly associated with AVRT (see earlier).

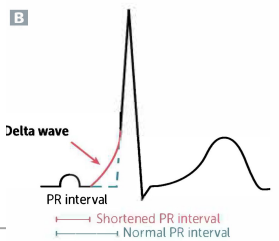

B. Amiodarone

C. Increase atenolo dose

**D. Radiofrequancy ablation

Trphozoites
Watery diarrhoea
Giardiasis

A 20-year-old man presented with 3-months history of watery diarrhoea, weight loss of 3 kg and abdominal cramps. He gave a history of travel to Mecca few months back. No other symptoms. Upper GI endoscopy was normal. Smear from duodenal aspirate revealed many trophozoites (see lab results).

Test Result Normal Values
Hb 109 130-170 g/L (Male)
120-160 g/L (Female)
Platelets count 459 150-400 x 109/L

KEY FACT

Organisms that cause watery diarrhea include *Vibrio cholerae*, rotavirus, enteropathogenic *E coli* (ETEC), *Cryptosporidium*, *Giardia*, and norovirus.

Which of the following is the most likely diagnosis?

A. Salmonella

**B. Giardia lambia

C. Clostridium difficile

D. Campylobacter jejuni

A 19-year-old man presented with 3-months history of watery diarrhoea, weight loss of 3 kg and abdominal cramps. He gave a history of travel to India few months back. No other symptoms. A smear from duodenal aspirate revealed many trophozities (see lab results).

Test Result Normal Values
Hb 108 130-170 g/L (Male)
120-160 g/L (Female)
Platelets count 458 150-400 x 109/L

Which of the following is the most appropriate management?

A. Doxacyclin

B. Rifampicin

**C. Metronidazole

D. Chloramphenicol

What is the best and simplest way to prevent giardiasis infection?

**A. Hand washing

B. Avoid eating fruits

C. Avoid eating vegetables

D. Prophylactic antibiotics

A 67-year-old diabetic patient admitted to Intensive Care Unit with sepsis and urinary tract infection. Blood culture revealed methicillin-resistant staphylococcus aureus.

Which of the following is the most appropriate treatment option?

A. Cefuroxime

**B. Vancomycin

C. Gentamycin

D. Flucloxacillin

What is the best and simplest precaution to prevent spread of MRSA infection?

**A. Hand hygiene

B. Wearing gowns

C. Wearing face mask

D. Daily disinfection of the beds

Infective endocarditis
CRp

A patient with infective endocarditis started on antibiotics.

What is the simplest way in monitoring antibiotics response?

A. Blood culture

B. Daily full blood count

C. Serial echocardiography

**D. Serum C-reactive protein concentration

Syphilis

A 25-year-old man developed fever, malaise and rash on his palm and soles. He gave a history of painless ulcer on his penis 6 weeks earlier. Examination was unremarkable a part from generalised lymphadenopathy.

Which of the following is the most likely organism causing his presentation?

A. Coxiella burnetii

**B. Treponema pallidum

C. Staphylococcus aureus

D. Chylamdia trachomatis

HIV
candidiasis

A 33-year-old man presented with 2-weeks of lethargy, fever, generalised lymphadenopathy and cough. History revealed he is a business man travels frequently to Far East. On examination, he has oral candidiasis (see lab results).

Test Result Normal Values
RBC 4 4.7-6.1 x 1012/L (Male)
4.2-5.4 x 1012/L (Female)

Hb 13 130-170 g/L (Male)
120-160 g/L (Female)
Platelets count 145 150-400 x 109/L
WBC 11 4.5-10.5 x 109/L
Neutrophils 22 40-60%
Lymphocytes 69 20-40 %
Monocytes 9 2-8 %

Which of the following is the most likely diagnosis?

**A. HIV

B. Syphilis

C. Brucellosis

D. Toxoplasmosis

Precaution
Cough
Lung cavitation
Airborne
Droplet

A 56-year-old diabetic man presented with cough and fever. Chest-XR showed cavity at upper lobe of the left lung.

What is the type of precaution required when dealing with this patient?

A. Droplet

B. Contact

**C. Airborne

D. Standard

Infectious
Mononucleosis
EBV

A 22-year-old woman previously healthy was admitted with 3-days history of fever, myalgia and pharyngitis. She gave history of 1-day macular rash over the trunk after she received amoxicillin from private clinic. On examination, she has generalised lymphadenopathy.

Which of the following is the most likely diagnosis?

A. Diphteria

B. Hodgkin's disease

**C. Infectious mononucleosis → EBV Rx: Supportive

D. Cytomegalovirus infection

Encephalitis
Low attenuation
Neck stiffness

A 25-year-old woman presented with 4-days history of confusion, lethargy and fever. On examination, she was drowsy with mild neck stiffness (see report).

CT scan brain:
Showed area of low attenuation at right tempo-parietal region.

Which of the following is the most likely diagnosis?

A. Brain abscess

B. Pneumococcal meningitis

**C. Herpes simplex encephalitis

D. Listeria meningoencephalitis

Brucellosis

A 43-year-old veterinarian man presents with 2-months history of progressive fatigue, back pain and fever. He also noticed a recent history of headache, mood /behaviour changes and paraesthesia. He is does not smoke with no history of alcohol or other significant medical history. On examination, he was uncooperative and agitated. Abdomen examination showed mild hepatosplenomegaly and tender right sacroiliac joint (see lab results).

Blood pressure 110/70 mmHg
Heart rate 88 /min
Temperature 38.6 °C

Test Result Normal Values
RBC 4 4.7-6.1 x 1012/L (Male)
4.2-5.4 x 1012/L (Female)
Hb 93 130-170 g/L (Male)
120-160 g/L (Female)
Platelets count 120 150-400 x 109/L
WBC 9 4.5-10.5 x 109/L

Which of the following is the most likely diagnosis?

A. Syphilis

**B. Brucellosis

C. Tuberculosis

D. Toxoplasmosis

Brucellosis

A 41-year-old veterinarian man presents with 3-months history of progressive fatigue, back pain and fever. He also noticed a recent history of headache, mood /behaviour changes and paraesthesia. He does not smoke and with no history of alcohol or other significant medical history. On examination, he was uncooperative and agitated. Abdomen examination showed mild hepatosplenomegaly and tender right sacroiliac joint (see lab results).

Blood pressure 110/70 mmHg
Heart rate 86 /min
Temperature 38.6 °C

Test Result Normal Values
Hb 98 130-170 g/L (Male)
120-160 g/L (Female)
Platelets count 122 150-400 x 109/L
WBC 8 4.5-10.5 x 109/L

Infection with Brucella may present as fever for weeks/months, hepatosplenomegaly, endocarditis, osteomyelitis, meningitis, or chronic joint pain. Look for:

- Patient from outside the United States
- Exposure to unpasteurized milk or uninspected meat
- "Returning war veteran" in medical history

Diagnose with culture of blood, CSF, urine, marrow. Treatment is doxycycline and gentamicin. Add rifampin for bone and heart infection.

Rx: FOR 6 MONTHS

Which of the following is the most appropriate next step in management?

A. Liver function

B. X-ray sacroiliac joint

C. Tuberculin skin test

**D. Tube agglutination test

A 43-year-old man was recently diagnosed with neurobrucellosis. He is started on rifampicin (600 mg/day) and doxycycline (100 mg twice daily orally).

Which of the following is the recommended treatment duration?

A. 6 weeks

B. 8 weeks

C. 4 months

**D. 6 months

AIDS
Toxoplasmosis
Ring enhancing

Antibiotics

A 22-year-old man known case with AIDS on active antiretroviral therapy (HAART) presented with history of headache and weakness at left side of the body. On examination, he is found to have left hemiparesis, hemianopia, aphasia, ataxia, and 6/7 cranial nerve palsies. Investigation showed a rising titers of anti-toxoplasma immunoglobulin G (IgG) antibodies and positive immunoglobulin M (IgM) antibody (see report).

Brain MRI scans:
Demonstrated multiple hypodense lesions in white matter and basal ganglia with mass effects.

Which of the following is the best treatment option?

KEY FACT

Ring-enhancing lesions in patients with AIDS should always prompt consideration of toxoplasmosis and CNS lymphoma.

A. Rifampicin and cefuroxime

B. Doxacyclin and clindamycin

C. Cholramphenicol and leucovorin

**D. Sulfadiazine and pyrimethamine + Leucovorin (folic acid analogue to prevent hematological toxicity)

Hyperkalemia

A 55-year-old man presents in the Emergency Department with nausea, pallor and lethargy. He has no past medical history of note. On examination, he has normal vital signs and unremarkable systemic examination (see lab results and report).

Test Result Normal Values
Sodium 139 134-146 mmol/L
Potassium 6.9 3.5-5.1 mmol/L
Bicarbonate 14 21-28 mmol/L
Blood urea nitrogen 14 2.8 to 8.9 mmol/L
↑ Creatinine 240 44-115 µmol/L

ECG:
Showed tall peaked T waves.

Which of the following is the most appropriate initial management?

A. Haemodialysis

B. Nebulised salbutamol

C. Insulin dextrose infusion

**D. Intravenous calcium gluconate

Thiazide
Furosemide

A 62-year-old man presents with progressive lower limbs edema for the last 4 months otherwise he is asymptomatic. He is known to have diabetes complicated with diabetic nephropathy and hypertension. His current medications are insulin, thiazide, ramipril and amlodipine. On examination blood pressure is 144/78 mmHg, JVP not raised, +3 lower limbs edema with normal cardiac and respiratory examination. Renal function was similar to 3 months ago (see lab results).

Test Result Normal Values
Sodium 138 134-146 mmol/L
Potassium 4.8 3.5-5.1 mmol/L
Urea 12.9 2.75-7.4 mmol/L
Creatinine 230 44-115 µmol/L
Creatinine clearance 22 70-103 µmol/L

Which of the following is the most appropriate action?

**A. Switch thiazide to furosemide

B. No change to his medication

C. Add a beta-blocker

D. Stop ramipril

A 55-year-old man who has developed chronic kidney disease secondary to focal segmental glomerulosclerosis is reviewed in the clinic. His renal function is deteriorating. Haemodialysis is planned to start soon (see lab result).

Test Result Normal Values
Creatinine clearance 10 70-103 µmol/L

What is the preferred method of access to start Haemodialysis?

A. Arteriovenous graft

**B. Arteriovenous fistula

C. Tunelled venous catheter

D. Non-tunelled venous catheter

Dialysis
Hyperkalemia
AKI

Which of the following scenario with acute kidney injury should be referred for urgent Haemodialysis?

A. Patient with eGFR < 5

**B. Potassium of 7.5 after 3 courses of medical management

C. Patient who has had 10ml of urine output over the last 24 hours

D. Patient who has previously had acute kidney injury three times

Contrast CT
CKD

A 65-year-old man has been admitted with abdominal pain and he need urgent contrast-enhanced CT but there is a concern regarding his kidney status as he has chronic kidney disease stage 3 (see lab results).

Test Result Normal Values
Sodium 143 134-146 mmol/L
Potassium 4.5 3.5-5.1 mmol/L
Blood urea nitrogen 9 2.8 to 8.9 mmol/L
Creatinine 160 44-115 µmol/L

Which of the following is the most important step in reducing the risk of contrast-induced nephropathy?

A. Oral N-acetylcysteine

B. Oral sodium bicarbonate

C. Intravenous furosemide pre-procedure

**D. Intravenous 0.9% sodium chloride pre- and post-procedure

Hyperkalemia
DKA

A 55-year-old man is seen in the Emergency Department complaining of lethargy for the last 2 days. On physical examination, vital signs are stable with unremarkable physical examination. ECG shows no acute changes (see lab results).

Test Result Normal Values
Sodium 139 134-146 mmol/L
Potassium 6.6 3.5-5.1 mmol/L
Bicarbonate 15 21-28 mmol/L
Blood urea nitrogen 9 2.8 to 8.9 mmol/L
Creatinine 118 44-115 µmol/L

Best **initial treatment**: It is critical to administer calcium gluconate for cardiac cell membrane stabilization if K^+ >6.5 mEq/L or if ECG changes are present.

Dialysis is needed for patients with renal failure and hyperkalemia refractory to the aforementioned medical management.

Which of the following is the most appropriate initial treatment?

A. Haemodialysis

B. Intravenous bicarbonate

**C. Insulin dextrose infusion

D. Intravenous normal saline

Nephrotic syndrome
Proteinuria
Prednisone

A 26-year-old woman is recently diagnosed as nephrotic syndrome secondary to minimal change glomerulonephritis after being presented with proteinuria.

Which of the following is the most appropriate initial treatment to reduce proteinuria?

**A. Prednisolone

B. Low protein diet

C. No treatment required

If a patient is on digitalis, K^+ levels must be carefully monitored. Hypokalemia sensitizes the heart to digitalis toxicity, because K^+ and digitalis compete for the same sites on the Na^+/K^+ pump.

D. Angiotensin-converting-enzyme inhibitor

Hypokalemia

A 30-year-old woman with Crohn's disease presents with hypokalemia refractory to aggressive paranteral and oral KCl supplementation.

Which of the following is the next step in managment?

. ECG may show T-wave flattening, U waves (an additional wave after the T wave), and ST-segment depression, leading to atrioventricular (AV) block and subsequent cardiac arrest.

A. Assess her serum plasma aldosterone to plasma renin ratio

**B. IV magnesium sulfate

C. Start spironolactone

D. Observation

- Treat the underlying disorder.
- Oral and/or IV K^+ repletion. Oral is the preferred route for safety purposes. If IV is necessary, a continuous rate of K^+ as an additive is preferred over an IV K^+ bolus. IV boluses should be reserved for symptomatic hypokalemia or ECG changes. Treatment should not exceed 20 mEq/L/hr.
- Replacement of magnesium. This deficiency makes K^+ repletion more difficult.

DM
Proteinuria

A 60-year-old woman presents to the clinic with a 10-year history of type 2 diabetes treated with insulin. Recently diagnosed to have hypertension and proteinuria (see lab results).

Blood pressure 150/90 mmHg
Heart rate 87 /min
BMI 29 kg/m2

Test Result Normal Values
Blood urea nitrogen 4 2.8 to 8.9 mmol/L
Creatinine 80 44-115 µmol/L
Glucose, fasting 6.4 3.5-6.5 mmol/L
HbA1C 7 4.7-5.6 %

A diabetic patient is evaluated with a UA that shows no protein. Microalbuminuria is detected (30–300 mg/24 hr). What is the next best step in management?

a. Enalapril
b. Kidney biopsy
c. Hydralazine
d. Renal consultation
e. Low-protein diet
f. Repeat UA annually and treat when trace protein is detected

Which of the following is the most appropriate management?

A. Life style modification for 6 months

B. Increase Insulin doses

**C. Start ACE inhibitors

D. Start atenolol

Answer: A. An ACE inhibitor or angiotensin receptor blocker (e.g., losartan, valsartan) is the best initial therapy for any degree of proteinuria in a diabetic patient. They decrease the progression of proteinuria and delay the development of renal insufficiency in diabetic patients. ★ ACE ⊖ → To control HTN in Diabetic patient

HTN
Hyperlipidemia

A 69-year-old man is evaluated during a routine examination. He reports his blood pressure to be around 150/84 mmHg on several occasions. He is known to have mild benign prostatic hyperplasia, and hyperlipidemia for which he is taking simvastatin. Cardiac examination is normal, and the remainder of the physical examination is unremarkable. Laboratory studies show a normal chemistry panel; a urine dipstick demonstrates no blood or protein. An electrocardiogram shows no evidence of left ventricular hypertrophy

Blood pressure 147/86 mmHg
Heart rate 80 /min
Respiratory rate 14 /min
Temperature 36.6 °C
Oxygen saturation 95 %
BMI 31 kg/m2

Which of the following is the most appropriate next step in management?

A. Repeat blood pressure determination in 4 months

**B. Lifestyle modifications and weight loss

C. Start Amlodipine

D. Start B-blockers

HTN
DM
Antihypertensive

A 60-year-old man is evaluated during a follow-up visit for management of newly diagnosed hypertension and diabetes mellitus started on metformin and gliclazide but not started on antihypertensive therapy. Physical examination is unremarkable (see lab results).

Blood pressure 155/95 mmHg
Heart rate 80 /min
BMI 32.5 kg/m2

Test Result Normal Values
Blood urea nitrogen 5 2.8 to 8.9 mmol/L
Creatinine 100 44-115 µmol/L
Random Glucose 6 3.9-5.5 mmol/L
HbA1C 6.9 4.7-5.6 %
Protein Present absent
Glucose Absent absent

Which of the following is the most appropriate antihypertensive treatment for this patient?

**A. Lisinopril

B. Atenolol

C. Amlodipine

D. Hydrochlorothiazide

DM
DKA
Insulin

A 20-year-old woman is diagnosed of type 1 diabetes mellitus after presenting with diabetic ketoacidosis. Her blood sugars are now stable and she is ready for discharge.

Which of the following is the best insulin regime she should be offered as outpatient?

A. Twice daily NPH insulin

B. Once daily mixtard insulin

**C. Basal-bolus insulin regimen with once-daily insulin glargine

D. Rapid-acting insulin analogue before each meal with no longer acting insulin

DM
Metformin

A 70-year-old woman known to have type 2 diabetes mellitus. She is currently taking metformin 1g bid physical examination is unremarkable (see lab results).

Test Result Normal Values
Creatinine 80 44-115 µmol/L
Glucose, fasting 6 3.5-6.5 mmol/L
Random Glucose 7.5 3.9-5.5 mmol/L

HbA1C 6.9 4.7-5.6 %

Which of the following is the most appropriate next step in management plan?

A. Increase dose of metformin

B. Add glimepiride

C. Add Sitagliptin

**D. No changes

A 30-year-old woman presents with secondary amenorrhoea after stopping the oral contraceptive pill 6 months ago. She gets regular headaches and visual disturbance. On examination, she has visual fields showed bilateral defects in the upper outer quadrants (see lab results and report).

Test Result Normal Values
Thyroid-Stimulating Hormone 0.1 0.4 - 5.0 µU/mL
Thyroxine (T4 free serum) 7.5 8.5 - 15.2 pmol/L
Follicle-stimulating hormone 0.2 5-20 IU/L (Follicular phase)
15-35 IU/L (Mid cycle peak)
5-15 IU/L (Luteal phase)
50-100 IU/L
(Postmenopausal women)
5-20 IU/L (men)
Luteinizing hormone 0.3 3-15 U/L (Male)
5-22 U/L (Follicular phase)
5-22 U/L (Luteal phase)
30-250 U/L (ovulatory phase)
> 30 U/L (Postmenopausal)
Prolactin 950 < 652 pmol/L (Male)
< 870 pmol/L (Female)
Cortisol 8 a.m. 30 138-635 nmol/L

Pituitary MRI:
4 cm pituitary mass compressing optic chiasm.

Which of the following is the definitive treatment option?

A. Octreotide

B. Bromocriptine

C. Stereotactic radiotherapy

**D. Trans-sphenoidal surgery

Addison
Synacthen
Hydrocortisone

A 32-year-old woman was admitted 2 days ago complaining of feeling unwell with vomiting, postural dizziness and weight loss. Synacthen test confirmed the diagnosis with Addison's disease. She was started on treatment with hydrocortisone 3 times a day, as well as fludrocortisone on a daily basis. She has been taking hydrocortisone 10mg at 9:00 and then 5mg at 12:00 and 15:00. On discharge, she informs the medical team that she sometimes does shift-work.

What is the most appropriate advice to give regarding steroid dosing for night shifts?

A. On shift days omit taking steroids

B. Take doses at 09:00, 12:00 and 15:00 regardless of shift patterns

C. On shift days take doses at 09:00, but then take other doses at night

**D. Adjust to take first dose at waking, then doses at 3 and 6 hours from starting

Hyperthyroidism
Thyroid
Pregnant
PTU
Ala gynae obs

A 34-year-old woman presents with increasing symptoms of heat intolerance, diarrhea and anxiety over the past couple of weeks. She is 28 weeks pregnant with her first baby and has a past medical history of hyperthyroidism, currently treated with 15 mg carbimazole. She has no other past medical history. She does not smoke, drink alcohol nor take any other drugs (see lab results).

First trimester: fertilization until up to 14 weeks
↳ * PTU is used. Carbimazole contra-indicated

Second trimester: 14 weeks until 28 weeks

Third trimester: 28 weeks until delivery

Blood pressure 110/70 mmHg
Heart rate 120 /min
Respiratory rate 18 /min
Temperature 37.6 °C
Oxygen saturation 95 %

Test Result Normal Values
Thyroid-Stimulating Hormone 0.1 0.4 - 5.0 µU/mL
Triiodothyronine (T3 free serum) 12 3.5 - 6.5 pmol/L
Thyroxine (T4 free serum) 25 8.5 - 15.2 pmol/L

Which of the following is the most appropriate next step in management?

A. Refer patient for immediate caesarean section

**B. Increase carbimazole dose to 20mg once daily

C. Switch carbimazole to propylthiouracil

D. Refer for a thyroidectomy

Pregnant
Hyperthyroidism
PTU
Ala Gynae obs

A 40-year-old woman is 6 weeks pregnant, presented to Endocrinology Clinic with diarrhea, heat intolerance and palpitation for the last month. She has no past medical history but she has strong family history of thyroid disease (see lab results).

Heart rate 90 /min
Respiratory rate 18 /min
Temperature 37.2 °C

Test Result Normal Values
TSH 0.001 0.4 - 5.0 µU/mL
Free T4 45 8.5 - 15.2 pmol/L
TSH receptor antibodies Positive negative

Which of the following is the most appropriate initial management?

A. Propranolol

B. Carbimazole

**C. Propylthiouracil

D. Total thyroidectomy

Thyroid
Hypothyroidism

A 45-year-old woman is referred to the Endocrinology Clinic due to abnormal thyroid function tests. Otherwise, she is asymptomatic. On examination, there is no evidence of goiter (see lab results).

Blood pressure 139/85 mmHg
Heart rate 66 /min
Temperature 36.6 °C
BMI 29 kg/m2

Test Result Normal Values
Thyroid-Stimulating Hormone 15 0.4 - 5.0 µU/mL
Thyroxine (T4 free serum) 6.5 8.5 - 15.2 pmol/L

Which of the following is the most appropriate management plan?

A. Reassure and discharge

B. Arrange for US of the neck

C. Repeat blood tests in 6 months

**D. Start levothyroxine replacement

Dm
DKA

A 27-year-old woman presents with 2-day history of generally unwell, nausea, vomiting and lethargy. She is a known type 1 diabetic using a long-standing subcutaneous insulin regime. She was started on treatment for diabetic ketoacidosis with intravenous fluids and fixed rate insulin. Her blood sugar is reviewed 3 hours after treatment was initiated. On admission, blood tests are done (see lab results).

Test Result Normal Values
ABG HCO3- 8 22-28 mmol/L
pH 7.2 7.36-7.45
Random Glucose 32 3.9-5.5 mmol/L

What should be the aim in managing hyperglycemia in a diabetic ketoacidosis patient?

A. Reduce blood glucose to under 14 mmol/l as quickly as possible

**B. Reduce blood glucose by 3mmol/l per hour

C. Reduce blood glucose by 6 mmol/l per hour

D. Aim blood glucose above 18 mmol/l

DKA
Insulin

A 20-year-old man with type 1 diabetes presents to the Emergency Department with vomiting and abdominal pain. He has been suffering from diarrhea for 2 days and then became severely dehydrated and started to vomit. He has not had his insulin for the last 24 hours. Normally, he

has a basal bolus regime with Glargine as a long-acting insulin, and Humalog as short-acting. On admission, he is found to have acidosis, elevated serum ketones and elevated blood glucose, and was diagnosed with diabetic ketoacidosis. He is started on IV fluid

What insulin should he be prescribed now?

**A. Fixed rate IV insulin as well as long-acting insulin

B. Sliding scale SC insulin

C. Fixed rate IV insulin

D. Insulin mixtard bid

Acromegaly

A 55-year-old man presents with excessive sweating and headache. An oral glucose tolerance test and MRI brain were ordered to confirm the diagnosis of acromegaly.

What other investigation will be required in the future?

A. Transesophageal echocardiography

B. No further investigations required

**C. Colonoscopy

D. CT abdomin

1. TTE
2. Colonoscopy

DM
Metformin

A 55-year-old man is referred to the Diabetes Clinic after presenting with polyuria and polydipsia with strong family history of type 2 diabetes mellitus. Physical examination is unremarkable (see lab results).

Blood pressure 136/85 mmHg
Heart rate 76 /min
Temperature 36.6 °C
BMI 34 kg/m2

Test Result Normal Values
Glucose, fasting 9 3.5-6.5 mmol/L
HbA1C 7.8 4.7-5.6 %

Which of the following is the most appropriate first-line treatment?

**A. Dietary advice, exercise and metformin

B. Dietary advice and exercise

C. Sulphonylurea

D. Exenatide

A 43-year-old man comes to the clinic for a follow-up. He has been recently diagnosed with type 2 diabetes and has been following a plan of lifestyle measures to improve his diet and increase his level of exercise (see lab result).

Blood pressure 129/80 mmHg

BMI 32 kg/m2

Test Result Normal Values
HbA1C 6.9 4.7-5.6 %

Which of the following is the most appropriate treatment option now?

A. Insulin

**B. Metformin

C. Sulphonylurea

D. Further diet and exercise

Hyperparathyroidism
PTH
Osteoporosis

A 40-year-old man was diagnosed with primary hyperparathyroidism based on the biochemistry results (elevated calcium, low phosphate and raised PTH levels) and parathyroid ultrasound images, which showed left lower parathyroid adenoma.

Which of the following is considered a valid indication for consideration for elective parathyroidectomy?

A. Age >50 years

**B. Evidence of osteoporosis

C. Normal renal function test

D. High parathyroid hormone level

An 18-year-old woman presented to the Emergency Room with spasms of hands along with twitching around the mouth. Her general physical and systemic examination was unremarkable except for pallor, dental caries and small body built. She had prolonged QT interval on ECG (see lab results).

Test Result Normal Values
Calcium 1.6 2.15-2.62 mmol/L
Phosphate, inorganic 0.7 0.82-1.51 mmol/L
Parathyroid hormone (intact PTH levels) 4.5 1.1-5.3 pmol/L
25-Hydroxy Vitamin D3 (Women) 10 25-90 nmol/L

Which of the following is the most appropriate initial treatment approach?

A. Oral calcium

B. Cholecalciferol

**C. Intravenous calcium

D. Oral phosphate supplementation

Antidote
Beta blockers
Atenolol

A 70-year-old man with ischemic heart disease developed dizziness and confusion following accidental ingestion of a higher dose of atenolol.

Blood pressure 70/40 mmHg
Heart rate 46 /min

In addition to holding atenolol and administration of intravenous fluid, which of the following drugs is the most appropriate?

A. Nifedipine

**B. Glucagon

C. Salbutamol nebulizer

D. Aminophylline infusion

Discuss Hypertension Beta blocker Claudication Angina CCB

A 60-year-old man with diabetes, hypertension and intermittent claudication due is diagnosed to have stable angina. Decision is made to manage him with intensive medical therapy. He is started on aspirin, rosuvastatin and nitroglycerine but still gets angina with moderate exercise.

Blood pressure 130/85 mmHg
Heart rate 86 /min

Which of the following is the most appropriate additional drug?

**A. Diltiazem

B. Nifedipine

C. Amlodipine

D. Metoprolol

🍒Elderly KC of DM and uncontrolled hypertensive, history of **chest tightness with exertion, he is on insulin, ACE, nitroglycerin,** what to add?
A.metoprolol ✅. B.diltiazem. C.nifedipine. D.Amlodipine

SVT vagal Adenosine

A 20-year-old woman presents to the Emergency Department with palpitations for 2-hours (see image and lab results).

6th June DHA ECG SVT

Blood pressure 135/80 mmHg
Heart rate 150 /min

Test Result Normal Values
Hb 138 130-170 g/L (Male)
120-160 g/L (Female)
Thyroid-Stimulating Hormone 3.2 0.4 - 5.0 µU/mL

Which of the following is the most appropriate initial management?

A. Oral amiodarone

**B. Carotid sinus massage

C. Intravenous adenosine

D. Electrical cardioversion

Supraventricular Tachycardia

Supraventricular tachycardia (SVT) presents with palpitations in a patient who is usually hemodynamically stable (based on reentry around the AV node). The best initial therapy is:

1. Vagal maneuvers (e.g., carotid massage, Valsalva, dive reflex, ice immersion)
2. If no response to vagal maneuvers, give adenosine
3. If no response to adenosine, give BBs (metoprolol), CCBs (diltiazem), or digoxin

Vagal maneuvers both slow and convert SVT. They do not convert A-fib.

Radiofrequency catheter ablation is curable in many cases.

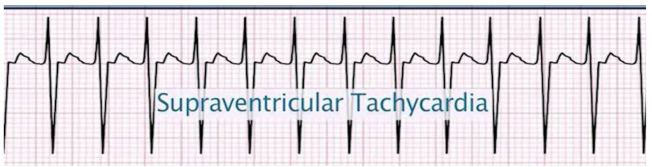

Figure 13.9 Supraventricular tachycardia (SVT) is a narrow complex tachycardia without P waves, fibrillatory waves, or flutter waves.

Antidote. Streptokinase

A 65-year-old man with diabetes is admitted to the Coronary Care Unit with diagnosis of acute

ST elevation anterior myocardial infarction. He developed massive hematemesis following streptokinase infusion.

Which of the following drugs would reverse the action of streptokinase?

A. Factor VIII concentrate

**B. Aminocaproic acid

C. Protamine

D. Vitamine K

Ethics

A 69-year-old man is admitted with acute chest pain and shortness of breath. Workup confirmed acute myocardial infarction. Upon discharge, he is advised to quit smoking, but he is unwilling to do so.

What should be said to the patient during the counseling session?

A. "We feel that you are uncooperative"

B. "We will involve the family in this issue"

C. "If you do not stop smoking you will die"

**D. "Continuing smoking means more complications"

Post MI exercise

A 50-year-old man who works as a bank employee is discharged following a 7-day admission for acute myocardial infarction. He was given 5 different drugs.

What further information regarding life style and daily activities should be given to him?

A. Advise him to change his job

B. Start driving 2 days after discharge

C. Refrain from sexual activities for 3 months

**D. Perform mild aerobic exercise from next week

Ethics

A 50-year-old man known to have advanced dilated cardiomyopathy is admitted to the Coronary Care Unit for the 5th time during the past 2 months. This admission, he is in refractory heart failure despite being on high doses of inotropic agents and nasal CPAP. Decision is made to consider him for heart transplantation.

After setting the scene, how would you break the news?

**A. Start with a warning shot and deliver the news in small steps

B. Do not waste time, tell him the decision directly

C. Deal with his concerns by expressing sympathy

D. Discuss the decision with his son

GIT
Weight loss
Endoscopy

A 60-year-old man presents with epigastric pain and early satiety associated with 10% weight loss over 8 months (see lab results).

Test Result Normal Values
Hb 98 130-170 g/L (Male)
120-160 g/L (Female)
MCV 70 80-95 fl

Which of the following is the best initial action in management?

**A. Gastroscopy

B. Ultrasound of abdomen

C. Empirical therapy for H. pylori

D. Trial of proton pump inhibitor for 6 weeks

GIT
heartburn
PPI

A 30-year-old woman complains of epigastric pain, heartburn and bloating after meals for 3 months. No history of hematemesis or weight loss. A trial of esomeprazole 40mg for 8 weeks did not relief her symptoms (see lab result and reports).

Test Result Normal Values
Hb 140 130-170 g/L (Male)
120-160 g/L (Female)

Gastroscopy:
Normal.

Urea breath test:
Negative.

Ultrasound of abdomen:
Normal.

Which of the following is the best next step in management?

A. Ranitidine

B. Hyoscine butylbromide

**C. Tricyclic antidepressant

D. Increase the dose of esomeprazole to 80mg/day

GIT
Esophageal varices

In a patient with liver cirrhosis and bleeding esophageal varices, treated with esophageal banding, which of the following drugs is effective in preventing future bleeding?

**A. Nadolol

B. Verapamil

C. Octreotide

D. Vasopressin

GIT
Crohns
Diarrhoea

An 18-year-old girl presents with chronic diarrhea and intermittent abdominal pain. No history of

upper or lower GI bleeding. On examination, she is slim and has pallor. No jaundice (see lab results).

Test Result Normal Values
Hb 100 130-170 g/L (Male)
120-160 g/L (Female)
MCV 100 80-95 fl
Platelets count 540 150-400 x 109/L
WBC 6 4.5-10.5 x 109/L
Vitamin B12 (Women) 0.074 0.12-0.66 nmol/L
Folic Acid (Women) 0.099 <0.1 µmol/L

Which of the following is the most likely diagnosis?

A. Celiac disease

**B. Crohns disease

C. Ulcerative colitis

D. Whipples disease

GIT
Wilson disease
Copper
Ceruloplasmin
Jaundice

An 18-year-old girl brought by her parents to the Gastroenterology Clinic as they noticed her to have a fine tremor of both hands. Further examination showed jaundice and just palpable spleen (see lab results).

Test Result Normal Values
Copper 0.8 1.72-3.54 mmol/L (Male)
1.72-3.76 mmol/L (Female)
Direct bilirubin 22.32 1.5-6.5 µmol/L
Total bilirubin 38.2 3.5-16.5 µmol/L
Aspartate aminotransferase 243 12-40 IU/L
Alanine aminotransferase 165 5-40 IU/L
Albumin 23 34-56 g/L
Total Proteins 46 60-84 cc
Serum ceruloplasmin Low
24 hours urine copper High (Most Accurate Test)

Which of the following is the most appropriate treatment?

A. Corticosteroid

**B. D-penicillamine

C. Desferrioxamine

D. Ursodeoxycholic acid

Treatment is penicillamine, which will chelate copper and remove it from the body (trientine is an alternative). Zinc is also used, which interferes with intestinal copper absorption.

GIT
Coffe ground vomitus
Gastritis

A 70-year-old man is mechanically ventilated in the Intensive Care Unit following massive cerebral hemorrhage. 7 days later, he developed coffee ground vomitus. history is only significant for hypertension.

Which of the following is the most likely the cause?

**A. Stress gastritis

B. Functional dyspepsia

C. Helicobacter gastritis

D. Gastroesophageal reflux

GIT
Hepatitis

A 45-year old with chronic hepatitis B is noted to develop increasing jaundice for the last 2 weeks associated with fatigue (see lab results).

Test Result Normal Values
Direct bilirubin 28.43 1.5-6.5 µmol/L
Total bilirubin 39 3.5-16.5 µmol/L
Aspartate aminotransferase 345 12-40 IU/L
Alanine aminotransferase 523 5-40 IU/L
Albumin 34 34-56 g/L
Total Proteins 60 60-84 cc
Hepatitis B DNA level Low

Which of the following is the most appropriate next step in management?

A. Start vitamin E

B. Perform liver biopsy

C. Start alpha interferon

**D. Request anti-Delta antibody

GIT
Liver lesion
Hemangioma

A middle-aged woman with hepatomegaly underwent upper abdomen MRI and found to have a 3cm lesion in the liver that shows peripheral beaded enhancement in the early phase with progressive central filling in the delayed phase.

Which of the following is the most likely diagnosis?

A. Hepatoma

B. Metastasis

C. Hydatid cyst

**D. Hemangioma

A patient presents with chronic dyspepsia and recurrent upper GI bleeds. Urea breath test is positive.

Which of the following regimen is the best to treat the underlying cause?

A. Oral omeprazole for 6 weeks

B. Ranitidine plus bismuth for 6 weeks

C. Sucralfate plus metronidazole for 6 weeks

**D. Esomeprazole, amoxicillin and clarithromycin for 14 days

A 40-year-old woman is under treatment for a recurrent helicobacter-associated duodenal ulcer. She noticed that her stool is turned non-tarry black (see lab result).

Blood pressure 110/70 mmHg
Heart rate 70 /min

Test Result Normal Values
Hb 152 130-170 g/L (Male)
120-160 g/L (Female)

What drug is likely to be the cause of the black stools?

A. Ranitidine

B. Pantoprazole

**C. Bismuth subsalicylate

D. Alumunium hydroxide

Celiac disease
Diarrhoea
Skin lesion

A 25-year-old patient presented with diarrhea for 5 months, which is mostly related to eating bread and wheat products.

Which of the following skin lesions would suggest the likely diagnosis?

A. Psoriasis

B. Hyperpigmentation

**C. Dermatitis herpitiformis

D. Pyoderma gangrenous

GIT
Black stools
Endoscopy

A 38-year old woman who was previously healthy came to the Emergency Department with recurrent episodes of passing black stools and sometimes fresh blood per-rectum over the last 2 months. Physical examination was unremarkable apart from pallor (see lab results and reports).

Test Result Normal Values
Hb 88 130-170 g/L (Male)
120-160 g/L (Female)

Upper and lower GI endoscopy:
Showed no significant pathology.

Which of the following is the best next investigation?

A. CT abdomen

**B. Capsule endoscopy

C. Barium meal and follow

D. Radio-isotope scan of abdomen

Antidote

A 23-year-old woman is brought to the Emergency Department after she ingested 15 tablets of paracetamol in a suicidal attempt 6 hours earlier. Activated charcoal is administered by the Emergency doctor.

Which of the following is the best next option in management?

A. Hyperbaric oxygen

**B. N-acetylcysteine

C. D-penicillamine

D. Hemodialysis

GIT
CLD
Ascitis
SAAG

A 43-year-old man is known to have hepatitis B virus infection presented with fever and confusion. On examination, he is disoriented, has asterixis and positive shifting dullness (see report).

Ascetic Fluid analysis:
Showed serum albumin ascitic fluid gradient (SAAG) of 1.2 and 350 neutrophils. Culture is bending.

Which of the following is the best management?

A. IV diuretics and metronidazole

**B. Lactulose enema and IV ceftriaxone

C. Oral Lactulose and sedation with diazepam

D. High volume ascetic fluid aspiration and propranolol

Hyponatremia
Euvolemic
Small cell CA

A 60-year-old man presents to Emergency Department with altered sensorium. He was recently diagnosed to have inoperable small cell carcinoma of the lung. On examination, he is euvolemic (see lab results).

Blood pressure 110/70 mmHg
Heart rate 76 /min

Test Result Normal Values
Sodium 115 134-146 mmol/L
Potassium 3.8 3.5-5.1 mmol/L
Urea 4.3 2.75-7.4 mmol/L
Creatinine 76 44-115 µmol/L

Which of the following is the best initial management?

A. 5% dexstrose

B. Normal saline

**C. Hypertonic saline

D. Half normal saline

TIA
Ct scan contrast
Renal impairment

A 70-year-old man presented to Emergency Department with generalized fatigability. 2 days ago, he had CT brain with contrast for possible transient ischemic attack. Physical examination is unremarkable (see lab results).

Blood pressure 130/70 mmHg
Heart rate 76 /min

Test Result Normal Values
Hb 170 130-170 g/L (Male)
120-160 g/L (Female)
Urea 30.4 2.75-7.4 mmol/L
Creatinine 378 44-115 µmol/L

Which of the following is the most likely mechanism for the renal impairment?

A. Pre-renal azotemia

**B. Acute tubular necrosis

C. Acute interstitial nephritis

D. Acute glomerular nephritis

Endo
Hypokalemia
BP
Hyperaldosteronism

A 30-year-old man is found to have a repeated BP of 170/110 mmHg. He is not on any medications. Physical examination is unremarkable (see lab results).

Test Result Normal Values
Sodium 138 134-146 mmol/L
Potassium 2.1 3.5-5.1 mmol/L
Urea 3.67 2.75-7.4 mmol/L
Creatinine 66 44-115 µmol/L

Which of the following is the most likely diagnosis?

**A. Primary hyperaldosteronism

B. Polycystic kidney disease

C. Coarctation of the aorta

D. Primary hypertension

Nephro
IgA
Hematuria

A 20-year-old man presents with hematuria, 1-day following a throat infection.

Which of the following is the most likely diagnosis?

**A. IgA nephropathy

B. Membranous nephropathy

C. Post-infectious glomerular nephritis

D. Focal segmental glomerulosclerosis

IgA nephropathy — Hematuria, HTN

- ACE for everybody
- High protein gets steroids
- BP goal <130/80 mm Hg

IGA NEPHROPATHY (BERGER DISEASE)

IgA nephropathy is the most common cause of acute glomerulonephritis in the United States. Look for IgA nephropathy with recurrent episodes of gross hematuria 1-2 days after an upper respiratory tract infection (synpharyngitic). All the other causes have some specific physical findings.

Poststreptococcal glomerulonephritis follows pharyngitis by 1–2 weeks. 1-4 wk

Nephro
Glomerulonephritis
Polyangitis

A 22-year-old woman is admitted with pulmonary hemorrhage and rapidly progressive glomerulonephritis. She has history of recurrent sinusitis and numbness in her right upper limb and left lower limb.

Which of the following is the most likely diagnosis?

A. Giant cell arteritis

B. Polyarteritis nodosa

C. Henoch-Schonlein purpura

**D. Granulomatosis with polyangiitis

Nephro
Hyperkalemia
DM
CKD
HTN

A 50-year-old man with diabetes, hypertension and chronic kidney disease, presents to the Nephrology Clinic for follow-up (see image and lab results).

Blood pressure 160/98 mmHg
Heart rate 80 /min

Test Result Normal Values
Potassium 6.5 3.5-5.1 mmol/L
Creatinine 440 44-115 µmol/L

Which of the following is the best immediate step in management?

**A. Intravenous calcium gluconate

B. Intravenous NAHCO3

C. Insulin with dextrose

D. Dialysis

Nephro
Hematuria
Nephritis

An 18-year-old man is complaining of red urine for 5 days. He has no abdominal pain and no dysuria, urgency or frequency. His history is significant for tonsillitis 3 weeks ago. Physical examination is normal except for elevated blood pressure.

Blood pressure 160/100 mmHg
Heart rate 76 /min

Which of the following is the most likely diagnosis?

A. Kidney stone

B. Hypernephroma

C. IgA nephropathy

**D. Post streptococcal glomerulonephritis

Nephro
EF 30
Dilated cardiomyopathy

A 68-year-old woman known to have dilated cardiomyopathy with an ejection fraction of 30% one month ago is admitted with a diagnosis of acute gastroenteritis. She had repeated vomiting

and watery diarrhea for 3 days. Her urine output is reduced in volume. She is on furosemide, lisinopril, spironolactone, and carvedilol. On examination, she is dehydrated, confused, has cold clammy skin and the JVP is 1 cm above the sternal angle (see lab results and reports).

Blood pressure 88/55 mmHg
Heart rate 70 /min

Test Result Normal Values
Sodium 142 134-146 mmol/L
Potassium 5.5 3.5-5.1 mmol/L
Urea 230 2.75-7.4 mmol/L
Creatinine 220 44-115 µmol/L
Sodium 15 40-230 mmol/day
Osmolality 1300 280-910 mOsm/Kg H2O

Central venous line:
inserted and is 3 cm of H2O.

Fractional excretion of sodium:
0.6%.

What is the best option in management?

A. Increase the dose of furosemide

B. Intravenous dobutamine infusion

**C. Carful intravenous saline infusion

D. Increase the dose of spironolactone

Pleural effusion
RA
Pleural fluid
Exudative

A patient with active rheumatoid arthritis presents with pleural effusion.

Which of the following is typical finding in the pleural fluid analysis?

A. Hemorrhagic

B. Transudative

C. High pH, > 7.64

**D. Glucose content of 1 mmol/L

Asthma
Spirometry
Methacholine

A 40-year-old woman presents with recurrent attacks of dyspnea and cough when exposed to dust and perfumes. Physical examination is normal except for mild expiratory wheeze on lung auscultation.

Which of the following tests has the highest diagnostic value?

**A. Spirometry

B. Chest X-ray

C. Arterial blood gases

Best diagnostic test for asthma?
A- Spirometry ✅✅ → 1st diagnostic test
↳ 2nd line diagnostic if PFT is nondiagnostic
B- B- Methacholine test (if asymptomatic or normal spiro do methacholine test.

Patient presented with **SOB only exertional, did spirometry and was normal:**
A- repeat spirometry B- **methacholine challenge test**

Pregnant lady presents with cough of **white sputum then cough** increased in severity and she developed SOB she is allergic to dust, mites and pollens what is the most imp investigation? **Spirometry** ✅ ✓

accurate test for Asthma = Spirometry

How to monitor asthmatic response to treatment : A. **spirometery** ✅. B. PEF

D. Methacholine challenge test

Respo
Dyspnea
Embolism
Spiral CT

A 44-year-old obese woman presents with sudden onset dyspnea. No cough, chest pain orthopnea or PND. History is significant for hemorrhoidectomy 2 weeks ago (see image, lab results and report).

Blood pressure 110/70 mmHg
Heart rate 105 /min

Test Result Normal Values
ABG HCO3- 20 22-28 mmol/L
ABG PCO2 4.5 4.7-6.0 kPa
pH 7.5 7.36-7.45
ABG PO2 10 10.6-14.2 kPa

Chest x-ray:
Normal except for the obliterated left costophrenic angle.

Which of the following has the highest diagnostic value?

A. D-dimer

B. Spirometry

**C. Spiral CT-scan

D. Echocardiogram

Respo
Dyspnea
Clubbing
Pulmonary fibrosis

A 30-year-old woman with rheumatoid arthritis presents with progressive dyspnea and dry cough for 3 months. No fever or weight loss. Physical examination revealed cyanosis, digital clubbing and bibasilar end-inspiratory crackles (velcro type) on lung auscultation.

Which of the following is the most likely diagnosis?

A. Lung abscess

B. Bronchiectasis

C. Bronchogenic carcinoma

**D. Interstitial pulmonary fibrosis

Respo
Sputum
Clubbing
Aspiration

A 44-year-old man with poorly controlled epilepsy presented with fever, cough and left side chest pain for 6 weeks. The cough is productive of copious foul-smelling sputum. Physical examination revealed digital clubbing and course crepitations in the right infra-clavicular area. Heart examination is normal (see image and report).

Blood pressure 110/70 mmHg
Heart rate 100 /min
Respiratory rate 25 /min
Temperature 39 °C

Sputum culture:
Mixture of aerobic and anaerobic organisms.

What is the most likely mechanism for the underlying condition?

**A. Aspiration

B. Vegetation embolism

C. Bronchogenic carcinoma

D. Direct extension from infected chest wall

Respo
Acute asthma exacerbation

A 30-year-old woman with bronchial asthma developed worsening dyspnea and cough following paint inhalation from neighborhood apartment. On examination, she is in respiratory distress, cannot complete a sentence and cyanosed. Chest auscultation revealed reduced breath sounds in both sides with short inspiratory and exploratory rhonchi (see lab results).

Blood pressure 110/70 mmHg
Heart rate 130 /min
Respiratory rate 20 /min
Oxygen saturation 85 %

Test Result Normal Values
ABG HCO3- 24 22-28 mmol/L
ABG PCO2 7.8 4.7-6.0 kPa
pH 7.3 7.36-7.45
ABG PO2 7.5 10.6-14.2 kPa

Which of the following is the best immediate action in management?

A. Intravenous magnesium infusion

B. Intravenous aminophylline infusion

**C. Intubation and mechanical ventilation

D. Nasal continuous positive airway pressure ventilation

A patient with poorly controlled bronchial asthma developed hypertension, which of the following antihypertensive medications is contraindicated?

**A. Beta blocker

B. Calcium channel blocker

C. Angiotensin II receptor blocker

D. Angiotensin converting enzyme inhibitor

Respo
Effusion
Bronchogenic CA

A 60-year-old man with advanced squamous cell bronchogenic carcinoma presents with massive malignant right pleural effusion. He has been admitted several times with similar findings for which he undergoes several therapeutic pleural taps.

Which of the following is the next best option in management?

A. Diuretics

B. Ultrafiltration

**C. Chemical pleurodesis

D. Low salt human albumin

Respo
Dyspnea
Red Shins
Cervical LN
Diffuse interstitial infiltrates

A 40-year-old woman presents with progressive dyspnea, dry cough and reddish nodular skin lesion over both shins. On examination, she has palpable cervical lymph nodes and bilateral diffuse fine crepitations in both lungs (see reports).

Chest radiograph:
Diffuse bilateral interstitial infiltrates with bilateral hilar lymph nodes enlargement.

Purified protein derivative (PPD):
Negative.

Cervical lymph node biopsy:
Non-caseating granuloma.

Which of the following is the next best option in management?

A. Montelukast

**B. Glucocorticoids

C. Anti-tuberculosis

D. Salmeterol inhaler

Respo
Hemoptysis
Coarse crepitations
Bronchiectasis

A 60-year-old man with post pulmonary tuberculosis bronchiectasis presents with massive hemoptysis. Physical examination shows course crepitations in the right scapular area (see image).

Which of the following is the most appropriate initial management?

A. Sedation

B. Pneumonectomy

C. Chest physiotherapy

**D. Positioning on right lateral decubitus

Ethics

A 78-year-old woman is admitted with fever and confusion due to pneumonia. The doctors decided to start her IV antibiotics. However, her son, who is the next of kin, disagreed and argued that antibiotics will cause more harm.

What is the best way to deal with this situation?

A. Ignore the opinion of the son and give the antibiotics to save the patient

**B. Counsel the son in the presence of the consultants

C. Respect the opinion of the next of kin

D. Take the opinion of the patient

Ethics

A young woman with long-standing rheumatoid arthritis is diagnosed to have non-specific interstitial lung disease. The physician decided to start her on oral glucocorticoid. However, the patient is concerned about the side effects related to this treatment.

What is the best approach to deal with this situation?

**A. Stress the importance of the treatment and give the patient time to decide

B. Inform the patient that refusing this treatment might cause death

C. Inform the patient that there is no alternative treatment

D. Tell the patient that most of the side effects are not serious

Ethics

An elderly patient is diagnosed with pulmonary tuberculosis and started on anti-TB treatment. He developed jaundice, which progressed to liver failure for which he was admitted to the Critical Care Unit. His son was very angry and decided to complain against the treating team.

What is the appropriate response to the son?

A. Tell him that this incident can happen to anyone

B. Inform him that the doctors offered the right management

C. Advise him against complaining as there is no medical error

**D. Calm him down and inform him that this incident will be investigated

Ethics

An elderly patient who has poorly controlled bronchial asthma with repeated admission to the hospital is found to be non-compliant with his medications.

Which of the following is the most appropriate action?

A. Tell the patient that it is not acceptable to disrespect the advice of doctors

B. As the patient is noncompliant, just keep him in the hospital

**C. Involve the next of kin to help to give his medications as prescribed

D. Tell the patient that he might die if he does not comply with the medications

Clostridium difficile

A 71-year-old man who has been admitted due to clostriduim difficile infection last year. In order to search for possible risk factors that increase the risk of recurrent infection, his medications have been reviewed thoroughly.

Which of the following medications is associated with increased risk of C. difficile infection?

**A. Omeprazole

B. Ferrous sulfate

C. Calcium carbonate

D. Multivitamin tablet

Respo
COPD
progression

A 69-year-old man with chronic obstructive pulmonary disease on oxygen therapy for the last 5

years.

Which of the following markers is most useful for monitoring the progression of this patient?

A. Oxygen saturations

B. Number of exacerbations per year

C. FEV1/FVC ratio

**D. FEV1

GIT
CLD
Ascitis
Diuretic

A 48-year-old man with a history of cirrhotic liver disease presents with abdominal distension. Clinical examination reveals tense ascites, which was drained.

What is the appropriate type of diuretic to help prevent reaccumulation of ascites?

**A. Aldosterone antagonist

B. Thiazide diuretic

C. Osmotic diuretic

D. Loop diuretic

A 43-year-old woman with complex regional pain syndrome comes to the clinic. She suffers from pain around her hand and wrist, which started after carpal tunnel release surgery. She was reviewed by orthopaedics and a specialist in Pain Clinic.

Which of the following is the most appropriate management option?

A. Opiate analgesia

**B. Physiotherapy

C. Counselling

D. Triptans

A 41-year-old man complains of double vision. Whilst looking forward the patients left eye turns towards the nose. On looking to the patient's right there is no obvious squint. However, on looking to the left, the patient is unable to abduct the left eye and double vision worsens.

Which of the following is the most likely cranial nerve palsy?

A. Left 3rd

B. Left 6th

C. Right 3rd

**D. Right 6th

CNS
dementia

A 42-year-old man comes to the clinic with his brother. The brother is concerned that he has been acting strangely over the past 4 months. In particular, he has been irritable and criticizes everyone at home. The changes were subtle at first but now arguments arise every other day. He has difficulty initiating conversation and even pauses halfway through sentences. There is

no family history of note and he is not taking any medications.

Which of the following is the most likely diagnosis?

A. Alzheimer's disease

B. Vascular dementia

C. Huntington's disease

**D. Frontotemporal dementia

A 71-year old man with history of osteoarthritis and previous cervical laminectomy for degenerative cervical myelopathy presents with a 2-month history of worsening gait instability and urinary urgency.

Which of the following is the most likely explains his symptoms?

A. Multiple sclerosis

B. Transverse myelitis

C. Cauda equina syndrome

**D. Recurrent degenerative cervical myelopathy

CNS
Cervical myelopathy

A 66-year-old man is referred to Neurology Outpatients with arm pain, stiffness and imbalance. Following investigations, he is diagnosed with degenerative cervical myelopathy. He misses his next Outpatient Clinic due to admission with acute coronary syndrome. He attends his appointment 2 months later and mentions his ongoing neurological symptoms.

Which of the following is the most important next step in his care?

**A. Refer to spinal surgery

B. Refer for physiotherapy

C. Commence neuropathic analgesia

D. Reassure the patient of his diagnosis

HEMATOLOGY
petechial skin
Factor 8
VWd

A 20-year-old man is noted to bleed excessively during an elective dental extraction. Following the procedure, examination reveals petechial skin haemorrhages. Blood results showed factor VIII, activity 87% (see lab results).

Test Result Normal Values
Hb 125 130-170 g/L (Male)
120-160 g/L (Female)
Platelets count 288 150-400 x 109/L
WBC 8 4.5-10.5 x 109/L
Prothrombin time 13.5 10-13 sec
APTT 38 30-40 sec

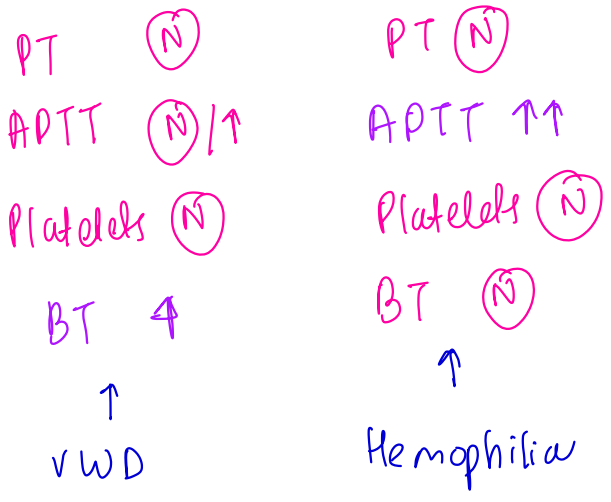

Which of the following is the most likely diagnosis?

A. Idiopathic thrombocytopenic purpura

**B. Von Willebrands disease

C. Haemophilia B

D. Haemophilia A

HEMATOLOGY
Sickle cell anemia
Crisis

A 26-year-old man with sickle cell anaemia presents with pallor, lethargy and headache (see lab results).

Test Result Normal Values
Hb 44 130-170 g/L (Male)
120-160 g/L (Female)
Reticulocyte 2.8 0.2-1.2 %

A 43-year-old man with sickle cell disease is admitted with an acute pain crisis. His only routine medication is folic acid. His hematocrit on admission is 34%, and on hospital day 3 it drops to 22%. What is the best initial test?

a. Reticulocyte count
b. Peripheral smear
c. Folate level
d. Parvovirus B19 IgM level
e. Bone marrow

Answer: A. Patients with sickle cell disease usually have very high reticulocytes because of the chronic compensated hemolysis. When reticulocyte count is normal in sickle cell disease, it is a very bad sign. Parvovirus B19 causes an aplastic crisis that freezes the growth of the marrow. Nothing will be visible on blood smear. Although the bone marrow will show giant pronormoblasts, this would not be done routinely, and certainly never as the initial test. The first clue to parvovirus is a sudden drop in reticulocyte level.

↓ Retic count

Which of the following is the most likely diagnosis?

A. Sequestration crisis

B. Thrombotic crisis

C. Haemolytic crisis Corrected

**D. Aplastic crisis

★ SICKLE CELL DISEASE

Diagnostic testing includes peripheral smear (best initial test). Sickle cell trait (AS disease) does not produce sickled cells. Hemoglobin electrophoresis is the most accurate test.

The most accurate test for parvovirus B19 is a PCR for DNA. This is more accurate than the IgM level. IV immunoglobulin is the best initial treatment.

Hematology
CLL

A 66-year-old woman presents with lethargy for the past 2 weeks. Her past medical history includes polymyalgia rheumatic and ischemic heart disease. Clinical examination is unremarkable (see lab results).

Test Result Normal Values
Hb 131 130-170 g/L (Male)
120-160 g/L (Female)
Platelets count 144 150-400 x 109/L
WBC 21 4.5-10.5 x 109/L
Neutrophils 44 40-60%
Lymphocytes 60 20-40 %

🍓patient with polymyalgia rheumatica, which of the following is associated? CLL
🍓Patient k/c of polymyalgia rheumatica , presents with fatigue CBC shows high lymphocyte count Dx: -CML. -lymphoma _CLL ✅ ((**Chronic lymphocytic leukemia))**

🍒old pt with Chronic kidney disease **present w**ith labs show **high WBC** with **arthritis**= CLL

Which of the following is the most likely diagnosis?

**A. Chronic lymphocytic leukemia

B. Infectious mononucleosis

C. Transient viral illness

D. Lymphoma

GIT
Cirrhosis
Ascites

A 55-year-old man known case of liver cirrhosis with ascites presented to the Emergency Department complaining of progressive non- specific abdominal pain for 6 days, which was associated with vomiting. Examination confirmed generalized abdominal tenderness (see lab result and report).

Blood pressure 100/55 mmHg

Test Result Normal Values
WBC 23.3 4.5-10.5 x 109/L

SURGERY

CT scan abdomen:
Moderate ascites with cirrhotic liver.

Which of the following is the most appropriate step in treatment?

**A. Antibiotics

B. Observation

C. Diagnostic laparoscopy

D. Exploratory Laparotomy

Turbid secretions
Abdominal pain

A 45-year-old man presented to the Emergency Department complaining of lower abdominal pain for 3 days. He gave a history of being hit by a piece of wood in the same site of pain 4 days back. Examination revealed lethargic patient in pain, which was aggravated by moving his leg, there was grayish turbid semipurulent secretions from a small break in the skin of right lower quadrant (see lab result).

Test Result Normal Values
WBC 33.1 4.5-10.5 x 109/L

Which of the following is the most appropriate next step in the management?

A. Observation

**B. Surgical drainage

C. CT scan abdomen

D. Culture and sensitivity for secretions

Stab wound
Neck trauma
Neck Zones

A 37-year-old man was involved in a fight and sustained a stab wound to the neck. On presentation, patient was conscious, alert. Examination showed a 2 cm wound anterior to the left ear and close to the angle of the mandible with blood ooze.

Which of the following is the most appropriate next step?

A. Chest X ray

B. Observation

**C. CTA of the neck

D. Exploration of the wound

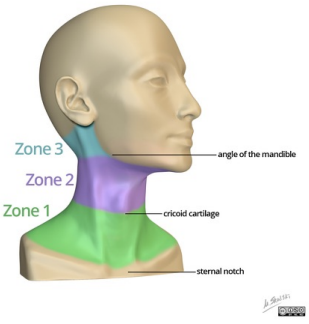

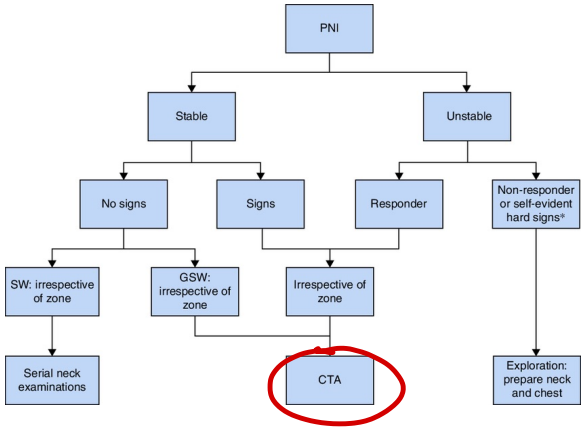

Surgery
Stab wound

A 19-year-old woman brought to the Emergency Department after being stabbed to the right upper quadrant. On arrival, she was conscious and oriented. Examination showed only a penetrating wound to the anterior abdominal wall at anterior axillary line just below the right

costal margin.

Which of the following is the most appropriate next step?

A. Observation

**B. CT scan abdomen

C. Ultrasound abdomen

D. Exploratory laparotomy

Penetrating stab wound. Patient is stable. What is the next step
A. US. B. CT

Pt presented with stabbed wound after wound exploration you found anterior abdominal fascia penetration, (his vitals were stable) what's your next step?
A. CT abdomen B. MRI abdomen C. Exploratory laparotomy D. Diagnostic laparoscop
bit unstable

A 25-year-old man brought to the Emergency Department after he was involved in motor vehicle crash, which was driving at a speed of 130 km/hour. Patient was wearing seat belt. On arrival to the Emergency Department, he was conscious, and alert (see report).

Chest X-ray:
Normal.

Which of the following is the most appropriate next step?

A. US abdomen

**B. CT scan abdomen

C. Diagnostic laparoscopy

D. Exploratory Laparotomy

Surgery
Neck wound
Low saturation

A 33-year-old man was involved in a motor vehicle crash. On arrival to the Emergency Department, he was conscious and alert. Examination showed an open wound to the anterior surface of the neck with devitalized tissue.

Blood pressure 100/60 mmHg
Heart rate 104 /min
Respiratory rate 28 /min
Oxygen saturation 87 %

Pt with small stab wound in anterior aspect of neck. On exam he is Alert and conscious but in labs oxygen sat 82%. What to do
A. Oxygen mask B. Cricothyroidotomy C. Endotracheal intubation

Indications for intubation: expanding hematoma, stridor, respiratory distress.

Which of the following is the most appropriate next step?

A. Oxygen mask

B. Tracheostomy

C. Cricothyroidotomy

**D. Endotracheal intubation Corrected

Chemical burn

A 56-year-old woman was exposed to chemical burns to her trunk. On arrival to the Emergency Department, she was conscious and alert. Examination showed a 6 cm x 11 cm wound at her back with burned clothe and powder of chemicals on her clothes and skin.

Which of the following is most appropriate next step after removing her clothes?

A. Antibiotics

**B. Powder sweeping

C. Surgical debridement

D. Water irrigation for 30 minutes

A 23-year-old man presented to the Emergency Department after he fell down from 3 m height on his right leg. Examination revealed a deformity of right leg with an open wound in the mid-leg and devitalized tissue and dirt in the wound. The leg was put in a splint.

Blood pressure 112/70 mmHg
Heart rate 99 /min
Respiratory rate 22 /min
Oxygen saturation 95 %

Which of the following is the most appropriate next step?

A. Antibiotics

B. External fixator

**C. Surgical debridement

D. Urgent internal fixation

Compartment

A 17-year-old man had a crush injury to his left leg after a heavy object fell on it, 5 hours prior to presentation. He was complaining of severe pain in his leg. Examination revealed a conscious and alert patient. His left leg was cold with delayed capillary refilling.

Blood pressure 116/67 mmHg
Heart rate 95 /min
Respiratory rate 23 /min
Oxygen saturation 95 %

Which of the following is the most appropriate next step?

A. Angiography

B. CT angiography

C. Duplex ultrasound

**D. Compartment pressure

Mallory Vomiting

A 37-year-old man presented to the Emergency Department with vomiting blood after attacks of excessive vomiting (see lab results).

Blood pressure 112/63 mmHg
Heart rate 89 /min
Respiratory rate 21 /min
Oxygen saturation 96 %

Test Result Normal Values

Hb 135 130-170 g/L (Male)
120-160 g/L (Female)
WBC 7.8 4.5-10.5 x 109/L

Which of the following is the most appropriate management plan?

A. Upper GI endoscopy

**B. Conservative treatment

C. Exploratory laparotomy

D. Sengstaken-blakmore tube

A 63-year-old woman presented to the Surgical Clinic complaining of upper abdominal pain and shortness of breath and occasional attacks of palpitation after meals, for several years. These symptoms relieved by vomiting.

Which of the following is the most appropriate method of investigations?

A. CT scan abdomen

B. Upper GI endoscopy

C. Plain abdominal X-Ray

**D. Upper GI barium study

Surgery
Reflux esophagitis

A 40-year-old woman presented with heartburn at the epigastric and retrosternal areas, and symptoms of regurgitation. The patient has tried conservative measures, including proton pumps inhibitors with no improvement in symptoms (see report).

Endoscopy:
Erythema of the esophagus consistent with reflux esophagitis.

Which of the following is the most appropriate next step?

A. Manometry study

B. 24-hour pH monitoring

**C. Lifestyle modification

D. Nissin's fundoplication

🌹Female with history of regurgitation and heartburn.. all conservative management failed include PPI ..endoscopy done showed erythema and erosion suggest esophagitis (most common complication of GERD)
A. manometry B. 24 h PH monitoring C. Lifestyle modification

Surgery
Upper GI bleed

A 73-year-old woman underwent percutaneous trans-hepatic cholangiography for treatment of obstructive jaundice. 24 hours after the procedure, she started to have upper gastrointestinal bleeding (see lab results).

Blood pressure 105/62 mmHg
Heart rate 89 /min
Respiratory rate 22 /min
Oxygen saturation 94 %

Test Result Normal Values

Hb 103 130-170 g/L (Male)
120-160 g/L (Female)
WBC 7.8 4.5-10.5 x 109/L

Which of the following is the most appropriate next step in the management plan?

A. CT scan

B. Endoscopy

C. Ultrasound

**D. Angiography

Old patient had percutaneous cholecystostomy, presented after 24hrs with upper GI bleeding what is the most important investigation?

A. angiography. B. Endoscopy. C. Ultrasound D. CT (they didn't mention w contrast)!@

Pseudoaneurysm of hepatic artery is a rare but known complication of laparoscopic cholecystectomy (LC). Such pseudoaneurysms may bleed in biliary tree, upper gastrointestinal (GI) tract or peritoneal cavity leading to life-threatening internal haemorrhage. It is very rare for them to present as lower GI bleeding.

Surgery
Pseudocysts

A 24-year-old man recovers from an attack of severe pancreatitis. He has mild epigastric discomfort, sensation of bloating, and loss of appetite. Examination reveals an epigastric fullness. The swelling increases in size over a 3-week period of observation (see report).

Ultrasound:
Confirmed to be a pseudocyst.

Which of the following is the most appropriate next step in management?

A. Observation

B. Internal drainage

**C. Percutaneous drainage

D. Excision of pseudocyst

<6 cm and asymptomatic → observe
>6 cm and symptomatic → Endoscopic Drainage
if infected → percutaneous !

Hypodense
OCP
RUQ Pain

A 32-year-old diabetic woman has taken contraceptive pills for 12 years develops right upper quadrant pain (see report).

CT scan:
A 5-cm hypodense lesion in the right lobe of the liver.

Which of the following is the most appropriate next step in management?

A. Excision

B. Follow up CT scan

C. Right hepatectomy

**D. Stop oral contraceptive

Hernia

A 68-year-old man has been advised to undergo surgical treatment for a left reducible inguinal hernia. He is otherwise healthy.

Which of the following is the most appropriate treatment?

A. Simple repair

**B. Open mesh repair

* Laparoscopic Repair
- Bilateral Hernias
- Recurrent Hernias

C. Laparoscopic repair

D. Non-surgical treatment

A 27-year-old man presented to the Surgical Clinic complaining of right groin pain for few weeks, which is aggravated by exercising. Examination confirmed normal external genitalia and groin region.

Which of the following is the most appropriate next step?

A. MRI

B. CT scan

**C. Ultrasound

D. Re-examination after 3 months

Post cholecystectomy
Subhepatic collection

A 42-year-old woman underwent an uneventful laparoscopic cholecystectomy. 2 weeks later, she presents to the Emergency Department with vague abdominal pain (see lab results and report).

Blood pressure 117/59 mmHg
Heart rate 83 /min
Respiratory rate 19 /min
Temperature 37.4 °C
Oxygen saturation 95 %

Test Result Normal Values
Hb 103 130-170 g/L (Male)
120-160 g/L (Female)
WBC 7.8 4.5-10.5 x 109/L
Total bilirubin 3.7 3.5-16.5 µmol/L

CT scan:
Large collection in the sub-hepatic area.

Which of the following is most appropriate next step?

A. Operative drainage

B. CT-guided drainage

C. Laparoscopic drainage

**D. ERCP with biliary stent placement

Intestinal obstruction

A 57-year-old man presents with 2 days of abdominal pain, nausea, and vomiting. Examination revealed a distended, tympanic and mildly tender abdomen without rebound or guarding (see lab results and reports).

Test Result Normal Values
Hb 153 130-170 g/L (Male)
120-160 g/L (Female)
WBC 12.6 4.5-10.5 x 109/L

Plain Abdominal X-ray:
Multiple air-fluid levels.

CT scan:
Multiple dilated loops of small bowel with a transition point in the distal small bowel, with some adjacent mesenteric fat stranding.

Which of the following is the most appropriate next step in management?

A. Observation

B. Colonoscopy

C. Diagnostic laparoscopy

**D. Exploratory laparotomy

A 35-year-old woman 1-day post total thyroidectomy was observed by the nurses to develop a spasm of her right hand during blood pressure measurement from the right arm.

Which of the following is the most appropriate next step?

A. Reassurance

B. Give analgesia

**C. Check her calcium level

D. Recheck the blood pressure

Ethics

A 30-year-old man presented to Surgical Clinic with right inguinal hernia. He was complaining of cough for the last 6 months, and did not use any treatment for it. He insisted to have the surgery and threatened the surgeon that he will raise a complain if did not book him for surgery.

Which of the following is the most appropriate action?

A. Do the surgery

**B. Call the social worker

C. Consult the physician

D. Inform the administration

Ethics

During a laparoscopic cholecystectomy, the surgeon encountered a difficult anatomy and there was a CBD injury, which was repaired and patient did very well.

Which of the following is the most appropriate post-operative action?

A. Talk to the family

**B. Talk to the patient

C. No need to tell them

D. Call a colleague to tell them

Ethics

A 32-year-old man was operated for a self-induced rectal injury. After the surgery, the family was asking about the cause of his illness.

Which of the following is the most appropriate response?

A. Inform the police

B. Tell them the truth

C. Involve social worker

**D. Refer them to the patient

Ethics

A 5-year-old girl brought by her family with rectal bleeding. During examination, it was observed that there is an abnormal relation between the parents. Examination confirmed multiple bruises over the child body.

Which of the following is the most appropriate action?

A. Inform the police

**B. Admit the patient

C. Inform the social worker

D. Talk to the family about your concern

Ethics

A 60-year-old woman was admitted for elective laparoscopic cholecystectomy. During the procedure, the surgeon found a big mass in the stomach.

Which of the following is the most appropriate action?

A. Cholecystectomy

**B. Stop the procedure

C. Resection of the mass

D. Cholecystectomy and mass resection

GCS

A 28-year-old man is brought to Emergency Room with head injury after motor vehicle accident, he is making incomprehensive sounds, open his eyes to painful stimuli and flexes his limbs to painful stimuli, and his pupils react sluggishly to light.

What is his Glasgow Coma Score?

Behaviour	Response
 Eye Opening Response	4. Spontaneously 3. To speech 2. To pain 1. No response
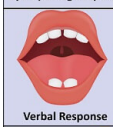 Verbal Response	5. Oriented to time, person and place 4. Confused 3. Inappropriate words 2. Incomprehensible sounds 1. No response
 Motor Response	6. Obeys command 5. Moves to localised pain 4. Flex to withdraw from pain 3. Abnormal flexion 2. Abnormal extension 1. No response

A. 5

B. 6

**C. 7

D. 8

A 33-year-old woman diagnosed with papillary thyroid cancer and planed for total

thyroidectomy, she have mitral valve prolapse with mild regurgitation, no other co-morbidity.

Which of the following is most appropriate option to prevent infection?

A. Amoxicillin to prevent endocarditis

B. Cefazolin to prevent wound infection

**C. No indication for antibiotic prophylaxis

D. Administer both cefazolin and amoxicillin

You cant give Enoxaprin when you are taking pt. to theatre immediately

DVT prophylaxis

A 55-year-old woman is admitted with obstructed ventral hernia for emergency exploration; patient is obese, diabetic and was discharged 7 days ago after surgical correction of retinal detachment.

Which of following is most appropriate DVT prophylaxis?

Intermittent Pneumatic Compression Device

A. Subcutaneous heparin

**B. Mechanical prophylaxis

C. Subcutaneous enoxaparin

D. Enoxaparin and mechanical prophylaxis

Surgery
TPN
Electrolyte abnormality

A 65-year-old man diagnosed with obstructing lower esophageal cancer and planed for surgery, patient is cachectic with more than 20% weight loss over 3 months. The treating team decided to start on preoperative TPN.

Which of the following is the most expected electrolyte abnormality?

**A. Hypokalemia

B. Hypocalcemia

C. Hypernatremia

D. Hyperphosphatemia

HIT
heparin
Direct thrombin inhibitors

A 33-year-old woman otherwise healthy, underwent laparoscopic sleeve gastrectomy, complicated by pulmonary embolism, she was started on heparin infusion, and after 5 days (see lab results).

Test Result Normal Values
↑ Platelets count 59 150-400 x 109/L
APTT 53 30-40 sec
INR 1.2 0.8-1.2
Prothrombin time 14 10-13 sec

HIT: more common with Unfractionated Heparin than LMWH

Rx: Fondaparinux (IV/SC) or Direct thrombin (II) inhibitors (Lepirudin, Dabigtran, Argatroban) Oral ← → Idarucizumab reversal

Which of the following is the most appropriate management?

**A. Stop heparin and start lepirudin

B. Increase IV heparin to reach PTT 60-70

C. Shift to subcutaneous therapeutic enoxaparin

D. Continue on same dose and repeat labs after 6 hours

Appendicitis
RLQ pain
Anorexia

A 17-year-old man presented to Emergency Room with right lower quadrant pain and anorexia. Examination revealed tenderness and rebound tenderness at Mc Burney's point (see image, lab result and report).

Heart rate 92 /min
Temperature 38.2 °C

Test Result Normal Values
WBC 21.3 4.5-10.5 x 109/L

Abdominal X-ray:
Round 1.5 cm Radio-opaque area at right iliac fossa.

Which of the following is the most appropriate next step?

**A. Appendectomy

B. Urgent urology consult

C. Non contrast CT abdomen

D. Ultrasound of the gall-bladder

Sickle Cell

A 44-year-old woman is admitted electively for laparoscopic cholecystectomy for chronic cholelithiasis. She is obese, diabetic and sickle cell trait.

Which of the following is most likely type of her gallstones?

Trait : Mixed

Disease : Pigmented

**A. Mixed

B. Oxalate

C. Pigmented

D. Pure cholesterol

A 65-year-old man presented to Emergency Room with history of vague upper abdominal pain and loss of appetite and weight. Examination revealed he was jaundiced; abdomen is soft and lax with palpable non-tender gallbladder.

Which of the following is the most likely diagnosis?

A. Liver cancer

**B. Pancreatic cancer

C. Primary choledocholithiasis

D. Secondary choledocholithiasis

Acalculi
Gall bladder
Cholecystitis

A 75-year-old man admitted to Coronary Care Unit with acute MI, complicated with bacterial

pneumonia, patient on tazocin for 12 days. Examination revealed abdomen severe tenderness in the right upper quadrant (see report).

Blood pressure 100/60 mmHg
Heart rate 96 /min
Respiratory rate 22 /min
Temperature 38.3 °C

Ultrasound abdomen:
Distended gallbladder with thick wall and pericystic fluids, there is no gallstones.

Which of following is the most appropriate management?

A. ERCP drainage

B. Emergency cholecystectomy

C. Change tazocin to meropenem

**D. US guided tube cholecystostomy drainage

Surgery GIT
Jaundice
RUQ pain
CBD stone
Post cholecystectomy

A 35-year-old woman presented to Emergency Room with vague upper abdominal pain. She underwent elective cholecystectomy for cholelithiasis 7 days ago. Examination revealed she was jaundiced with mild right upper quadrant tenderness (see lab results and report).

Temperature 37.1 °C

Test Result Normal Values
WBC 9.3 4.5-10.5 x 109/L
Alkaline phosphatase
169 39-117 IU/L

Alanine aminotransferase 35 5-40 IU/L
Amylase 102 24-151 IU/L
Direct bilirubin 10 1.5-6.5 µmol/L
Total bilirubin 17 3.5-16.5 µmol/L

Ultrasound:
Minimal fluids in gall-bladder fossa, CBD measure 9 mm.

Which of the following is the most likely diagnosis?

A. CBD injury

**B. Retained CBD stone

C. Sub-hepatic collection

D. Slipped cystic duct clip

A 70-year-old women p7+1 with chronic constipation presented to Emergency Room with abdominal distension and vomiting. Examination revealed abdomen is distended, tympanic, with round tender non-reducible swelling in the right groin bellow and lateral to pubic tubercle (see report).

X-ray abdomen:
Distended small bowel with multiple fluid levels.

Which of the following is the most likely diagnosis?

**A. Femoral hernia

B. Direct inguinal hernia

C. Metastatic lymphnode

D. Indirect inguinal hernia

Surgery
Iron deficiency anemia
Cecal CA

A 61-year-old man presented to Outpatient Clinic with general fatigue and mild on and off stool mixed with streaks of blood for 4 months. Examination revealed he was pale; abdomen is soft and lax, per rectal examination revealed 2nd degree piles (see lab result).

Test Result Normal Values
Hb 8.3 130-170 g/L (Male)
120-160 g/L (Female)

Which of the following is the most likely diagnosis?

**A. Cecal cancer

B. Rectal cancer

C. Sigmoid cancer

D. Chronically bleeding haemorrhoids

Intestines obstruction
Carcinoma

A 52-year-old woman presented to Emergency Room with abdominal distension and vomiting, she has history of ventral hernia repair with mesh 12 years back. Examination revealed distended abdomen, no tenderness, and no signs of hernia recurrence (see reports).

X-ray abdomen:
Dilated bowels with air/fluid levels.

CT scan:
Contrast cut off at terminal ilium with soft tissue mass and target sign.

Which of the following is likely diagnosis?

**A. Small bowel cancer

B. Adhesion to the mesh

C. Meckel's diverticulum

D. Late onset crohn's disease

Ingestion of bleach

A 12-year-old boy is brought to the Emergency Room 30 min after accidentally ingesting bleach; vital signs are stable with maintained airway. He was kept NPO, started on IV fluids and broad-spectrum antibiotics.

Blood pressure 110/70 mmHg
Heart rate 76 /min
Respiratory rate 18 /min
Temperature 36.6 °C
Oxygen saturation 95 %

Which of the following is most appropriate next step?

A. Induce emesis

**B. Close observation

C. Water ingestion to dilute the bleach

D. Insert NGT and drain gastric content

An 18-year-old man involved in burn accident, he has 2nd degree burn to his both lower limbs.

Weight 70 kg

Using Parkland formula, which of the following is most appropriate fluid resuscitation?

A. Lactate ringer's 200 ml/hr for 24 hrs

B. Normal saline 1L bolus then 120ml/hr

**C. Lactate ringer's 5 L over 1st 8 hrs then 5 L over next 16 hrs

D. Lactate ringer's 2.5 L over 1st 6 hrs then 2.5 L over the next 16 hrs

Thyroid nodule

A 32-year-old healthy woman had neck ultrasound to evaluate lipoma; incidentally, there was right thyroid lobe 2.3 cm solid hypoechoic nodule (see lab results and report).

Test Result Normal Values
Thyroid-Stimulating Hormone 2.3 0.4 - 5.0 µU/mL
Thyroxine (T4 free serum) 11.3 8.5 - 15.2 pmol/L

Fine Needle Aspiration:
Follicular neoplasm, Bethesda 4.

Which of the flowing is most appropriate management?

A. Nodule excision

**B. Hemithyroidectomy

C. Repeat US in 3 months

D. Radiofrequency ablation

A 27-year-old man is brought to Emergency Room after motor vehicle accidents, he was complaining of severe pain in his right leg. Examination revealed intact skin, tens swollen leg, foot paresthesia at the 1st web space with palpable distal pulses (see reports).

Blood pressure 121/70 mmHg
Heart rate 109 /min
Respiratory rate 23 /min
Temperature 37.0 °C
Oxygen saturation 95 %

X-ray:
Comminuted, right bicondylar tibial plateau fracture.

Posterior leg deep compartment pressure:
35 mmHg.

Which of the following is the most appropriate management?

A. Closed reduction and elevation

B. External fixation and leg elevation

C. Internal fixation and leg elevation

**D. External fixation and 4 compartment fasciotomy

A 24-year-old man had gunshot wound in the left side of his chest; chest tube was inserted with minimal hemothorax and no air leak. The bullet entry lateral the nipple, exit point was below the left scapula. Suddenly patient becomes agitated and hypotensive. Examination revealed distended neck veins, good air entry both side of the chest with unclear heart sounds.

Which of the following is the most appropriate management?

A. Fluid bolus

**B. Pericardiocentesis

C. Emergency room thoracotomy

D. Needle thoracostomy in the left 2nd intercostal

A 2-month-old baby is brought to the clinic because of umbilical bulge that appears when child is crying. Examination revealed 1 cm reducible umbilical hernia.

Which of the following is most appropriate treatment?

**A. Observation

B. Hernia sling

C. Surgical repair

D. Delayed surgical repair at age of 6 months

A 12-year-old boy had isolated blunt abdominal injury, is complaining of vague upper abdominal pain. Examination revealed the abdomen was soft with mild left upper quadrant tenderness (see lab results and report).

Blood pressure 100/65 mmHg
Heart rate 91 /min

Respiratory rate 18 /min
Temperature 37.3 °C
Oxygen saturation 97 %

Test Result Normal Values
Hb 11.3 130-170 g/L (Male)
120-160 g/L (Female)
HCT 0.39 0.42-0.52 (Male)
0.37-0.48 (Female)
Platelets count 238 150-400 x 109/L
WBC 14.1 4.5-10.5 x 109/L

CT scan:
Minimal pelvic fluids, 4 cm splenic tear with 7 cm subcapsular hematoma (Grade 3), no other abnormality.

Which of the following is most appropriate management?

**A. Close observation

B. Open splenectomy

C. Splenic preserving surgery

D. Per-cutaneous drainage of pelvic fluids

A 28-year-old man has chronic history of episodes of sharp anal pain with defecation, occasionally associated with small amount of fresh blood. Examination revealed posterior anal fissure with skin tag. All conservative treatments failed. 6th June DHA

Which of the following is most appropriate surgical management?

A. Anal dilatation

**B. Lateral internal sphincterotomy

C. Lateral external sphincterotomy

D. Curettage of the fissure and excision of skin tag

A 55-year-old man presents to the clinic. He is a smoker with long history of sever gastrointestinal reflux disease on proton bump inhibitors. His last endoscopy revealed lower esophageal redness and ulceration (see report).

Biopsy from lower esophagus:
Squamous cells with high-grade dysplasia.

Which of the following is the most appropriate therapeutic option?

A. Add ranitidine

B. Council to stop smoking

C. Repeat endoscopy after 6 months

**D. Refer for possible esophageal resection

A 37-year-old P5+0 woman comes to the clinic. History reveals she has grave's disease since 5 years; her condition is well-controlled with antithyroid medications, trials of stopping medication failed. Examination reveals she has severe exophthalmos (see report).

Ultrasound thyroid:
Hypervascular homogenous normal size thyroid.

Which of the following indicates thyroidectomy over radioactive iodine?

A. The patients age

**B. Severe exophthalmos

C. Hypervascular thyroid

D. Failure of medical treatment

Penetrating stab injury
Neck trauma
Neck zones

Which of the following is most appropriate management of penetrating zone 3 neck vascular injury?

A. Vascular ligation

B. Open primary repair

C. Open vascular bypass

**D. Endovascular intervention

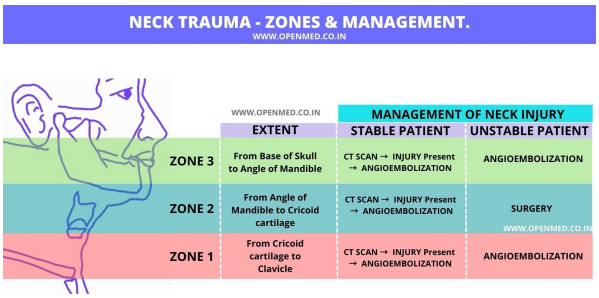

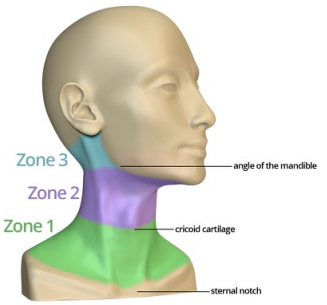

Blunt thoracic trauma
Ligamentun arteriosum

Which of the following is the most common location for blunt thoracic aortic injury?

A. Aortic arch

**B. At the ligamentum arteriosum

C. Disal to left subclavian artery

D. Proximal to the left subclavian artery

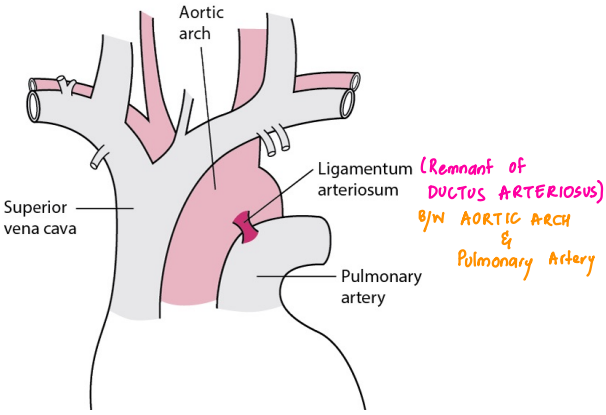

Femur fractures

A 32-year-old man fell from his motorbike and broke his femur.

Which of the following is most essential before reduction?

A. Give sedation

B. Give analgesia

C. Call the operating room

**D. Examine his peripheral pulses

VASCULAR

Limb ischemia
Gold standard
Angiography

Which of the following is the most appropriate diagnostic gold standard in critical limbs ischemia?

A. Ultrasound

**B. CT Angiography

C. MR Angiography

D. Conventional angiography Corrected

Vascular malformation

Which of the following is an absolute indication for treatment of vascular malformations?

A. Pain

B. Cosmesis

C. Claudication

**D. Congestive heart failure

Risk Factor
PAD

Which of the following is the most appropriate strategy in managing medical risk factors in Peripheral Atrial disease?

pt with dm, smoker, with peripheral artery disease, what would you do to improve his condition? A. dual aspirin. B. **smoking cessation program** C. exercise program D. strict glucose control program

A. Weight reduction

B. Aerobic exercised

**C. Supervised exercised program

D. Non supervised exercised program

Acute Limb ischemia
Atrial fibrillation
Absent distal pulse
PAD

A 40-year-old healthy woman presents to Emergency Room with a 4-hour history of sudden onset right lower limb pain. Her examination reveals intact femoral pulse but absent distal pulses, diminished sensory exam with an altered motor exam. Her labs are normal (see report).

Blood pressure 110/70 mmHg
Heart rate 95 /min
Respiratory rate 18 /min
Temperature 36.6 °C
Oxygen saturation 98 %

PAD pain occurs when walking up or down hills. Severe disease is associated with loss of:
Hair follicles
Sweat glands
Sebaceous glands
The skin becomes smooth and shiny.

Peripheral artery disease (PAD) is the stenosis of peripheral arteries with the same causative factors as coronary and carotid disease such as:

- Tobacco smoking
- Diabetes mellitus
- Hyperlipidemia
- Hypertension

Initial Test: ABPI
Most Accurate: Angiogram

Rx:
Aspirin or vorapaxar
— (Vorapaxar: antiplatelet medication that is an alternative to aspirin and clopidogrel
— Do not use when there is a history of stroke or TIA because it can cause bleeding
Stopping smoking
Cilostazol (most effective medication)
Surgery to bypass stenosis if medical therapies are ineffective
ACE INHIBITORS for HTN
STATINS

ECG:
Shows atrial fibrillation.

Which of the following is the most appropriate next step?

**A. Heparin

B. Morphine

C. CT angiogram

D. Vascular Ultrasound

Acute limb ischemia:
- Initial step (heparin infusion)
- Investigations: Initial (doppler US or CT angio), Best (angiography)
- Management (grade 1, 2A) within 24 hours
- **Grade 2A**: minimal or none sensory loss
  - Tx if caused by Embolism > fogarty catheter
  - Tx if caused by Thrombus > thrombectomy + - revascularization.
- **Grade 2B** (sensory loss and motor deficit): operate within 6 hours:
  - Revascularization
- **Grade 3** (irreversible)
  - Amputation

1st heparin → angiography

Acute Limb ischemia
Atrial fibrillation
Absent distal pulse
PAD

A 40-year old healthy woman presents to Emergency Room with a 4-hour history of sudden onset right lower limb pain. Her examination reveals intact femoral pulse but absent distal pulses, diminished sensory exam with an altered motor exam. Her labs are normal (see report).

Blood pressure 110/70 mmHg
Heart rate 95 /min

Respiratory rate 18 /min
Temperature 36.6 °C
Oxygen saturation 98 %

ECG:
Shows atrial fibrillation.

Which of the following is the most appropriate management?

**A. Femoral embolectomy

B. Above knee amputation

C. Catheter-directed thrombolysis

D. Heparinization and observation

Acute Limb ischemia
Atrial fibrillation
Absent distal pulse
PAD

A 40-year old healthy woman presents to Emergency Room with a 4-hour history of sudden onset right lower limb pain. Her examination reveals intact femoral pulse but absent distal pulses, diminished sensory exam with an altered motor exam. Her labs are normal (see report).

Blood pressure 110/70 mmHg
Heart rate 95 /min
Respiratory rate 18 /min
Temperature 36.6 °C
Oxygen saturation 98 %

Δ Embolism sec. Atrial fibrillation

ECG:
Shows atrial fibrillation.

Which of the following is the most appropriate investigation?

A. CT angiogram

B. Vascular ultrasound

C. Conventional angiogram

**D. Embolectomy with no imaging

Acute Limb ischemia
DM HTN
Absent distal pulse
Angiogram

A 62-year-old man known diabetes and hypertension presents with 4-hour history of sudden left leg pain, he had a history of left leg pain after walking 200 meters that make him stop and is relieved by rest. He is on oral hypoglycemic and statin but not compliant to medication and has been smoking for the last 40 years. Pulse examination on the left reveals present femoral absent popliteal and distal, his right leg revealed intact femoral and popliteal but diminished distal pulses (see lab results and report).

Blood pressure 110/70 mmHg
Heart rate 76 /min
Respiratory rate 18 /min
Temperature 36.6 °C
Oxygen saturation 95 %

Test Result Normal Values

Random Glucose 10 3.9-5.5 mmol/L
HbA1C 8 4.7-5.6 %

ECG:
Normal.

Which of the following is the most appropriate investigation?

**A. CT angiogram

B. Vascular ultrasound

C. Conventional angiogram

D. Magnetic resonant angiogram

Acute Limb ischemia
DM HTN
Absent distal pulse
NEXT STEP

A 62-year-old man known diabetes and hypertension presents with 4-hour history of sudden left leg pain, he had a history of left leg pain after walking 200 meters that make him stop and is relieved by rest. He is on oral hypoglycemic and statin but not compliant to medication and has been smoking for the last 40 years. Pulse examination on the left reveals present femoral absent popliteal and distal, his right leg revealed intact femoral and popliteal but diminished distal pulses (see lab result and report).

Test Result Normal Values
Random Glucose 7 3.9-5.5 mmol/L

ECG:
Normal.

Which of the following is the most appropriate next step?

**A. Heparin

B. Morphine

C. CT angiogram

D. Vascular Ultrasound

Acute Limb ischemia
DM HTN
Absent distal pulse
Thrombus

A 62-year-old man known case of DM HTN presents with 4-hour history of sudden left leg pain, the patient had a history of left leg pain after walking 200 meters that make him stop and is relieved by rest. He is on an oral hypoglycemic and a statin but he is not compliant to his medication. He has been smoking for the last 40 years. His pulse exam on the left reveals present femoral absent popliteal and distal, his right leg revealed intact femoral and popliteal but diminished distal pulses His labs are normal apart from an elevated BSL (see report).

ECG:
Normal.

Which of the following is the most appropriate management?

**A. Catheter-directed thrombolysis

B. Femoral thrombectomy

Acute limb ischemia:
- Initial step (heparin infusion)
- Investigations: Initial (doppler US or CT angio), Best (angiography)
- Management (grade 1, 2A) within 24 hours
- **Grade 2A**: minimal or none sensory loss
  - Tx if caused by Embolism > fogarty catheter
  - Tx if caused by Thrombus > thrombectomy + - revascularization.
- **Grade 2B** (sensory loss and motor deficit): operate within 6 hours:
  - Revascularization
- **Grade 3** (irreversible)
  - Amputation

C. Above knee amputation

D. Heparinization and observation

Acute Limb ischemia
DM HTN
Thrombolysis
MCC Death

A 62-year-old man known diabetes and hypertension presents with 4-hour history of sudden left leg pain, he had a history of left leg pain after walking 200 meters that make him stop and is relieved by rest. He is on oral hypoglycemic and statin but he is not compliant to medication. He has been smoking for the last 40 years. Pulse examination on the left reveals present femoral absent popliteal and distal, his right leg revealed intact femoral and popliteal but diminished distal pulses. The patient had a successful thrombolysis with an endovascular correction of a long stenosis segment (see lab result and report).

Test Result Normal Values
Random Glucose 7 3.9-5.5 mmol/L

ECG:
Normal.

Which of the following is the most common cause of death during his hospital stay?

A. Stroke

B. Bleeding

C. Pulmonary embolism

**D. Myocardial infarction

A 54-year-old man known diabetic and heavy smoker presents with a history of classic vascular claudication of his left leg after 100m walk to the mosque. His pulse examination reveals intact pulses on the right leg and diminished distal pulses below the popliteal artery.

Which of the following is the most appropriate way to improve his claudication distance?

A. Dual antiplatlet therapy

**B. Supervised exercise program

C. Supervised smoking cessation

D. Aggressive blood sugar control start program

Acute Limb ischemia
DM HTN
Claudication
Angiogram

A 54-year-old man known diabetic and heavy smoker presents with a history of classic vascular claudication of his left leg after 100m walk to the mosque. His pulse examination reveals intact pulses on the right leg and diminished distal pulses below the popliteal artery.

Which of the following is the most appropriate investigation?

A. MRA

B. CT angiogram

C. Conventional angiogram

**D. None-invasive vascular lab exam

Claudication
PAD

A 54-year-old man known diabetic and heavy smoker presents with a history of classic vascular claudication of his left leg after 100m walk to the mosque. His pulse examination reveals intact pulses on the right leg and diminished distal pulses below the popliteal artery.

Which of the following is the most appropriate management?

**A. Medical risk factor stratification

B. Surgical bypass of the stenosis lesion

C. Endovascular repair of the stenotic lesion

D. Smoking cessation aggressive blood sugar level control

Varicose veins
Spider veins
Duplex

A 32-year-old woman presents with 5-year history of spider veins that are asymptomatic but she wants to treat it cosmetically. Her pulse examination is normal and there is no other varicosities noted part from the anterior thigh spider veins.

Which of the following is the most appropriate investigation?

A. CT venography

B. Venous plethysmography

**C. No investigation needed

D. Venous duplex ultrasound

Varicose veins
Spider veins
Duplex
Sclerotherapy

A 32-year-old woman presents with 5-year history of spider veins that are asymptomatic but she wants to treat it cosmetically. Her pulse examination is normal and there is no other varicosities noted part from the anterior thigh spider veins.

Which of the following is the most appropriate management?

**A. Sclerotherapy

B. Endovenous ablation

C. Ligation and stripping of GSV

D. Daflon, micronized purified flavonoid fraction 500mg PO twice daily

A 46-year-old woman presented with a 6-year history of bilateral varicosities, she complained of heaviness during standing and bilateral lower limb swelling. There is no history of claudication or rest pain. Examination revealed intact distal pulses and bilateral varicose on the GSV territory

Which of the following is the most appropriate investigation?

A. CT venography

B. Venous plethysmography

C. No investigation needed

**D. Venous duplex ultrasound

Varicose veins
Duplex
Ablation
Angiogram

A 46-year-old woman presented with a 6-years history of bilateral varicosities, she complained

of heaviness during standing and bilateral lower limb swelling. There is no history of claudication or rest pain. Examination revealed intact distal pulses and bilateral varicose on the great saphynous vein (GSV) territory.

Which of the following is the most appropriate management?

A. Sclerotherapy

**B. Endovenous ablation

C. Ligation and stripping of GSV

D. Daflon, micronized purified flavonoid fraction 500mg PO twice daily

AAA
Angiography

A 62-year-old man presents with an incidental finding of a 4.5 cm abdominal aortic aneurysm and gallstones on an ultrasound done for biliary colic, the general surgeon decided to do a laparoscopic cholecystectomy and referred him to vascular surgery for an opinion.

Which of the following is the most appropriate recommendation of the vascular surgeon?

A. Proceed with surgery and follow up with US

**B. CT angiography before proceeding for surgery

C. Proceed with surgery and follow up with CT angiography

D. Conventional angiography before proceeding for surgery

DM HTN
toe nail surgery

A 72-year-old man known to have diabetes and hypertension presents with an ingrowing toenail.

Blood pressure 110/70 mmHg
Heart rate 76 /min
Respiratory rate 18 /min
Temperature 36.6 °C
Oxygen saturation 99 %
Height 160 cm
BMI 20 kg/m2

Which of the following is the most appropriate step before operating on the toe?

A. Start antibiotics

B. Examine the other toes

C. Swab the toe for culture

**D. Examine peripheral pulses

Etiology	Arterial Ulcers	Venous Ulcers
Wound Depth	• Partial-thickness • Full-thickness	• Partial-thickness • Full-thickness
Location	• Between toes, over phalangeal heads, tips of toes, lateral malleolus	• Gaiter area
Characteristics	• Punched-out appearance • Pale or necrotic wound tissue • Minimally exudating wound • Pale skin, shiny, taut, thin • Absence of hair	• Irregular shape • Granular wound • Moderate to highly exudating wound • Hemosiderin staining • Lipodermatosclerosis • Firm edema
Risk Factors	• Diabetes, uncontrolled • Inadequate footwear • Foot deformities • Advanced age • Secondary to peripheral arterial disease • Peripheral vascular disease	• Diabetes • Pregnancy • Advanced age • Deep vein thrombosis, varicose veins • Congestive heart failure • Malnutrition • Obesity • Immobility

Venous ulcer
Arterial ulcer
Duplex

A 54-yearold man known to have diabetes and hypertension presents to the clinic with an ulcer over the right lateral malleolus for 3 months. Examination revealed intact distal pulses.

Which of the following the most appropriate next step?

A. MRA

▪most common location for arterial ulcer >> Lateral. No pulse>> arterial
▪Most common location for venous ulcer >> medial. pulse >>> Venous
But the pulse will be the clue.

B. CT angio

C. Conventional angio

**D. Venouse duplex of right lower limb

A 32-year-old woman presents with a 2-day history of right lower limb swelling, no history of trauma. Examination reveals bluish discoloration of the foot and intact distal pulses.

Blood pressure 110/70 mmHg
Heart rate 90 /min
Respiratory rate 18 /min
Temperature 36.6 °C
Oxygen saturation 99 %

Which of the following is the most appropriate next best step in diagnosis?

A. CT angio

B. CT venogram

**C. Venouse duplex

D. Arterial duplex

A 55-year-old man hypertensive with renal insufficiency was fully evaluated for arteriovenous fistula creation, he has intact distal pulses and no history of trauma or vascular procedures on his non-dominant hand.

Which of the following fistula type should be offered first?

**A. Radio-cephalic

B. Brachio-basilic

C. Brachio-cephalic

D. Basilic vein transposition

A 50-year-old man post-kidney transplant, 2-year on steroid treatment underwent emergency exploratory laparotomy for intestinal obstruction.

Which of the following will most likely promotes his wound healing?

**A. Vitamin A

B. Vitamin B1

C. Vitamin B2

D. Vitamin C

A 45-year-old man had laparoscopic cholecystectomy, developed fever on 3rd postoperative day. He had no abdominal pain.

Temperature 38.6 °C

Which of the following is most likely diagnosis?

A. Chest infection

B. Wound infection

**C. Urinary tract infection

D. Intra-abdominal abscess

A 40-year-old woman complains of painful right breast mass for 6 months increasing in size. Examination confirms a 3 cm mass at 9 O'clock (see report).

Core biopsy:
Benign phyllodes tumor.

Which is the following the most appropriate treatment?

**A. Wide local excision

B. Simple mastectomy

C. No surgical intervention

D. Wide local excision with radiation therapy

Gall bladder polyp

A 35-year-old woman had abdominal ultrasound as part of screening for essential hypertension. She has no abdominal symptoms (see report).

Ultrasound Abdomen:
Gall bladder single polyp measures 0.6 cm, no stones, and normal bile ducts.

Which is the following is the most appropriate management?

**A. Surgical consultation

B. No further intervention

C. Check Liver function test

D. Follow up ultrasound within 6 months

Ascending Cholangitis
RUQ pain

A 33-year-old women presents with history of right upper quadrant pain and yellow sclera. Examination reveals unwell patient with abdominal tenderness but no guarding (see lab results and report).

Test Result Normal Values
Total bilirubin 30 3.5-16.5 µmol/L
WBC 15 4.5-10.5 x 109/L
Alkaline phosphatase 280 39-117 IU/L

Ultrasound of Abdomen:
Multiple gallstone, no precholecystic fluid, common bile duct is dilated and measures 1 cm.

ASCENDING CHOLANGITIS

Cholangitis is a life-threatening emergency caused by obstruction of the common bile duct (CBD) with a gallstone that has escaped the gallbladder. Symptoms include:
Fever, Jaundice
RUQ pain
Hypotension, Alt. mental status

- U/S → Initial test
- MRCP → Most Accurate abdomen

Rx: I/V Abx + ERCP (Stable)
PTC (Unstable)
Elective Cholecystectomy (Eventually)

Which is the following is most likely diagnosis?

A. Acute pancreatitis

B. Acute chloecystitis

C. Choledocholithiasis

**D. Ascending cholangitis

Splenectomy
Pneumococcal
Vaccine

A 19-year-old man was involved in road traffic accident underwent emergency splenectomy.

Which the following is the optimal post-operative timing for administration of pneumococcal vaccine?

A. 2 day

B. 1 week

**C. 2 weeks

D. 1 month

A 31-year-old man was involved in road traffic accident; examination revealed he is fully oriented GCS15/15 before reaching the hospital paramedic reported interval unresponsiveness. The patient suddenly lost consciousness and dilatation of left pupil was noted (see report).

X-ray of the skull:
Left temporal fracture.

Which is the following most likely diagnosis?

A. Ruptured arteriovenous malformation

B. Subdural hematoma

**C. Epidural hematoma

D. Basal skull fracture

Haemorrhoids
Sclerotherapy

A 30-year-old man presented with history of bleeding per rectum. Anoscopy examination revealed swelling at 3,7 o'clock position. A treatment with injection of sclerosing agents is planned.

Which of the following is most indicated for sclerosing therapy?

A. External haemorrhoids

**B. Internal haemorrhoids

C. Prolapsed haemorrhoids

D. Thrombose haemorrhoids

Undescended testis

A 5-year-old boy presents to Emergency Room because the parents noticed that there is only one testis in the scrotum. Examination reveals that one testis is in the scrotum while the other one is felt in the inguinal canal.

Which the following is the most appropriate treatment?

**A. Orchidopexy

B. Orchidectomy

C. Wait till puberty

D. Androgens administration

Fracture femur
Angulation
Spica

A 6-year-old boy presents with a fracture of femur (mid shaft) with 30% of anterior angulation.

Which of the following is the most appropriate treatment?

A. Traction and bed rest

**B. Closed reduction and hip a Spica cast

C. Open reduction and intramedullary fixation

D. Open reduction and internal fixation (plate)

TPN
Hypomagnesemia
Hypokalemia

A 45-year-old man diagnosed as short bowel syndrome on total parenteral nutrition developed weakness vertigo and convulsions.

Which of the following is the most like diagnosis?

A. Hyperkalemia

B. Hypokalemia

C. Hyperammonemia

**D. Hypomagnesaemia

Pregnant
Abdominal Pain
Appendicitis

A 30-year-old women 16-week pregnant presents with nausea, vomiting and right sided abdominal pain. The obstetrician excluded any pregnancy related cause for pain.

Temperature 37.8 °C

Which of the following is the most likely cause?

A. Gastritis

B. Pancreatitis

C. Cholecystitis

**D. Appendicitis

Hydatid cyst

A 45-year-old man farmer presented with history of right side abdominal pain, vomiting and fever. Examination confirmed tenderness in right upper quadrant (see report).

Temperature 37.6 °C

CT abdomen:
Calcified cyst 5X6 cm. Hydatid cyst (echinococous) was confirmed.

Which of the following is the most appropriate treatment?

**A. Surgical excision

B. Administration of steroid

C. Percutaneous catheter drainage

D. Administration of metronidazole

ECHINOCOCCOSIS

- Animal source: dogs and sheep shedding Echinococcus eggs
- Eggs ingested by human
- Spreads to liver, lung, and brain, forming hydatid cysts
- Diagnosis: detect cysts with sonogram, CT, or MRI; confirm with ELISA
- Treatment:
  - Do not aspirate cysts—can spread the infection
  - Oral albendazole, injection of alcohol into the cysts

Thyroid
Goiter
Midline mass

A 35-year-old man presents with history of dyspnea during sleep and swallowing discomfort for 4 month. He is a known case of asthma (see report).

Chest X-ray:
Midline mass compressing trachea.

Which of the following is the most like diagnosis?

**A. Goiter

B. Thymoma

C. Lymphoma

D. Lung cancer

Dysphagia
Liquid
Barium

A 20-year-old women presents with history of dysphagia that was more with liquid than solid.

Which of the following is the most appropriate first investigation?

**A. Barium swallow

B. Upper GI endoscopy

C. Ultrasound of chest

D. CT scan of the chest

A 55-year-old woman complained of difficulty in breathing 6-hour post total thyroidectomy. Examination confirmed the presence of large neck swelling.

Which of the following is the most appropriate next step in management?

A. Treacheostomy

B. IV calcium glucante

C. Epinephrine injection

**D. Open the wound sutures in the ward

Renal colic
CT
Most diagnositc

A 20-year-old man presents to Emergency Department with renal colic.

Which of the following is most diagnostic imaging?

A. MRI abdomen

B. X-ray KUB region

**C. CT scan abdomen

D. Ultrasound abdomen

Bone tumors
Osteosarcoma
Sclerotic

A 4-year-old boy presented with history of pain above his right knee. Examination revealed there is swelling at distal femur no limitation of knee movement (see report).

X-ray:
3x3 sclerotic bone lesion at distal femur.

Which of the following is most likely diagnosis?

**A. Osteosarcoma

B. Chondrosarcoma

C. Ewing's sarcoma

D. Periosteal sarcoma

	Age	Site	Charcters	X ray	Treatment
OSTEOCHNDROMA	20 yrs	• Grow away from joint • Mostly: Ribs; Scapula; Pelvis; Long Bones	• Single or Multiple; bony hard; non tender • Accidentally Discovered; systemically well patient.	- Mushroom Appearance - Calcified Stalk - Radioluscent Cap	Resection
OSTEOID OSTEOMA		Long Bone Shaft,	• Pain worse at night, might relieved by Aspirin • CT shows Nidus	• Localized osteolytic lesion urrounded by a rim of sclerosis • <2cm radioluscent nidus, woven bone	Excision of nidus
GCT / OSTEO CLASTOMA		• 50% around knee • Metaphyseo-Epiphyseal region		• Thinning & fracture of cortex • Soap Bubble appearance	Radiotherapy
MULTIPLE MYELOMA			• COMMONEST In Adult • Monoclonal Ab (+) • B2 microglobulin in blood • Urine Bence-Jones Protein(+) • Serum (Ca & Urea)↑ • Fatigue; Pain; Weakness • Generalised Osteoporosis & Crushed Vertebrae	• Punched out Lesion • Lytic Lesion	
OSTEO SARCOMA Metaphysis of Long Bone	10-25 yrs	DIST. FEMUR (COMMONLY) Proximal Tibia Proximal Humerus Proximal Femur Pelvis "Remember- around knee"	• COMMONEST Among Children • 2 ND COMMONEST in Adult; arise from medullary cavity • Painful enlarging Mass, pain worse @ night • Pulmonary Metastasis (Cannon-Ball / Nodules) (CXR)	• Sun Ray / Sun Burst Effect • Codman's Triangle • Bony Elevation; Sub-periosteal New Bone Formation	Chemo + Surgery
EWING'S Onion, moth	10-20 yrs		• Onion Skin (Lamellated Periosteal Reaction) • Lytic Lesion ; Moth-Eaten appearance		

A 23-year-old military man presented to the clinic with history of bilateral groin swelling. Examination revealed there was bilateral inguinal hernia

Which of the following is the most appropriate treatment?

A. Observation

B. Open repair with mesh

C. Open repair without mesh

**D. Laparoscopic repair with mesh

RUQ Pain
Jaundice
ERCP

A 50-year-old woman presented with history of right upper guardant pain for the last 5 months associated with jaundice for 4 days. Examination revealed unwell patient, tender abdomen but no rebound. The patient started on I.V antibiotic (see report).

Blood pressure 99/70 mmHg
Heart rate 100 /min
Temperature 38 °C

Ultrasound:
Gall bladder stones, dilated common bile duct with stone.

Which is the following is the most appropriate treatment?

A. Lithotripsy

B. Open surgery

C. Laparoscopic cholecystectomy

**D. Endoscopic retrograde cholengiopancreatography ERCP

Pneumothorax
Fracture ribs
RTA

A 64-year-old man is involved in a high-speed car crash. He is resuscitated initially in a small hospital with limited resources he has head injury. It was decided to transfer this patient to trauma center, which is 40 km away (see report).

Blood pressure 110/70 mmHg
Heart rate 100 /min
Respiratory rate 18 /min
Temperature 36.6 °C

man after accident and resuscitation in small hospital u need to transfer to another hospital after stabilization, it is 30 mins far. **on xray u see fracture of 2-5 left ribs**. no pneumothorax what will u do?
a. intubate ✅ b. call the other hospital to inform the surgeon on call
↳ if severe
c. chest tube insertion

X-ray chest:
Widened mediastinum with fractures left ribs 2-5 but no pneumothorax.

Which is the following the most appropriate next step?

A. Insert chest tube

B. Intubate the patient

C. Perform diagnostic peritoneal lavage

**D. Call the receiving hospital and speak to the surgeon on call

Ethics

A 30-year-old man presented to the Surgical Clinic while taking medical history ,he want his perceptions of why he felt ill and the doctor wants more detail about his symptoms and medical problems.

Which is the following the most appropriate response?

**A. Allow him to complete his thought

B. Inform him to change his appointment with other doctor

C. Till him other patient are waiting outside and clinic is busy now

D. Politely interrupt him and continue with close-ended question

Ethics

A 22-year-old women presented to Surgery Clinic wearing revealing cloths, she come up very close to the doctor asking personal question in sedative tone with a language that is different from attending nurse language.

Which is the following is the best response by the doctor?

A. Shout at here

B. Call the security

C. Refer to other doctor

**D. Call for other nurse talk same language

Ethics

A 70-year-old man presented with history of skin lesion over the right check (see report).

Skin biopsy:
Malignant melanoma.

Which is the following is best way to make the patient comply with medical advice?

A. The illness has serous symptoms

B. He believes you are professional and right

C. Explain pathophysiology using medical terminology

**D. Taking time to provide information and gain his trust

Skin Lesion

A 23-year-old woman presented to the Surgical Clinic with a 1 X 2 cm skin lesion in the left forearm since childhood.

Which of the following is the most appropriate treatment?

A. Laser

**B. Excision

C. Radiation

D. Follow up

Skin lesion
Melanoma

A 43-year-old man presented to the Surgical Clinic complaining of a dark colored pigmented skin lesion in the upper thigh for few months. Examination revealed a 3 X 4 cm dark colored skin lesion at the anterior aspect of right thigh with irregular borders and it was elevated above the skin.

Which of the following is the most appropriate next step in management?

**A. Excision

B. Bunch biopsy

C. Radiotherapy

D. Chemotherapy

Varicose
Calf swelling
Nsaids

A 47-year-old woman presented to the Emergency Department complaining of painful cord-like swelling in the calf of left leg for 48 hours. She gave history of varicose veins for 20 years.

Which of the following is the most appropriate initial treatment?

**A. Non-steroidal anti-inflamatory drugs

B. Clexane

C. Heparin

D. Antibiotics

Abdominal pain
Sleeve gastrectomy

A 45-year-old man presents to the Emergency Department complaining of severe abdominal pain, which was increasing in intensity with time. Patient underwent laparoscopic sleeve gastrectomy 3 weeks back.

Which of the following is the most appropriate diagnostic test?

A. Ultrasound Abdomen

B. Plain Abdominal X-ray

C. Diagnostic laparoscopy

**D. CT scan abdomen with contrast

Abdominal pain
Sleeve gastrectomy

A 45-year-old man presents to the Emergency Department complaining of severe abdominal pain, which was increasing in intensity with time. Patient underwent laparoscopic sleeve gastrectomy 3 weeks back.

Which of the following is the most appropriate management?

A. Endoscopy

B. Exploration

Corrected

C. Nil per mouth

**D. Anticoagulation

respiratory distress
Newborn
Hyperlucent
Thoracostomy

A male newborn develops sudden respiratory distress (see report).

Chest radiograph:
A hyperlucent left upper lobe with adjacent lobar compression and mediastinal shift to the right.

Which of the following is most appropriate treatment?

A. Intubation

**B. Thoracotomy

C. Bronchoscopy

D. Thoracostomy

Projectile vomit
5 week old

A 5-week-old boy presents with persistent progressive projectile vomiting.

Which of the following is the most appropriate next step in management?

A. Antiemetics

**B. Normal saline

C. Ringer lactate

D. Potassium chloride

Abdominal pain
vomiting
Ultrasound

A 3-year-old boy presented to Emergency Department with progressive abdominal pain and vomiting. Examination revealed distended abdomen.

Which of the following is the most appropriate initial management?

A. MRI abdomen

B. CT scan abdomen

**C. Ultrasound abdomen

D. Plain abdominal X-ray

A 10-month-old girl brought by her family because of swelling in the umbilicus, which becomes more obvious when she is crying and disappears during sleeping.

Which of the following is the most appropriate management?

**A. Follow up

B. Mesh repair

C. Simple repair

D. Laparoscopic repair

Rouxen Y
Gastric bypass
Ct Scan

A 40-old woman had laparoscopic Roux-en-Y gastric bypass 5 days ago, presented with pain at the left shoulder, fever and rigors.

Blood pressure 90/60 mmHg
Heart rate 120 /min
Temperature 38.6 °C

Which of the following is the most appropriate next step in management?

A. Endoscopy

B. Ultrasound abdomen

C. Diagnostic laparoscopy

**D. CT scan abdomen with contrast

Sleeve gastrectomy
Vomiting
Reassure

A 26-year-old woman presented 17 days after laparoscopic sleeve gastrectomy complaining of persistent vomiting and change of her mode according to the family. Examination revealed soft abdomen (see reports).

Ultrasound abdomen:
Normal.

CT scan abdomen:
Normal.

Which of the following is the most appropriate management?

A. Endoscopy

B. Reassurance

C. Diagnostic laparoscopy

**D. Psychiatry consultation

Pregnant
Gallstones
2nd trimester

A 30-year-old woman who is 10-week pregnant and known case of gallstone presents to the Surgical Clinic complaining of recurrent attacks of biliary colic for the last 5 weeks.

Which of the following is the most appropriate management?

A. Immediate laparoscopic cholecystectomy

B. Laparoscopic cholecystectomy after delivery

**C. Laparoscopic cholecystectomy in 2nd trimester

D. Laparoscopic cholecystectomy in 3rd trimester

g2 P1+0 , 10 weeks pregnant has gallbladder stone years on medication and now she is having pain when to do cholecystectomy ? -2nd trimester ✅

pregnant lady with recurrent pain known case of gallstone what wll do? **belter laparoscopy in 2nd trimester.**

Pregnant in 9 week with colicystitis when should colicysectomy preform?
A-immediately B-delay to second trimester ✅✅ C-delay to third trimester D-delay to after delivery

poorly colic than Recurrent

Biliary colic symptomatic in pregnant women in 20 weeks What the management ?
a) Conservative ✅ b) Lap chole

Hypovolemic Shock
Sigmoid cancer
Laparoscopic surgery
Colostomy
Laparotomy

A 73-year-old man presented with abdominal pain and constipation for 1 week. Workup revealed a sigmoid cancer. He underwent laparoscopic surgery with a plan to perform a resection with a proximal colostomy. During the operation, his vital signs changed.

Blood pressure 86/45 mmHg
Heart rate 124 /min
Temperature 36.8 °C

Which of the following is the most appropriate next step in management?

A. Chest X-ray

**B. Echocardiography

C. Convert laparotomy Corrected

D. Terminate the surgery

Laparoscopic
Cholecystectomy
Angle of mouth pain

A 65-year-old man presented to the Emergency Department with pain over the angle of his mouth for 24 hours. He underwent laparoscopic cholecystectomy 8 days prior to presentation.

Blood pressure 110/72 mmHg
Heart rate 104 /min
Temperature 38.8 °C

Which of the following is the most appropriate management?

A. CT scan

B. Plain X-ray

**C. Antibiotics

D. Paracetamol

Appendectomy
Purulent discharge
Wound explortion

A 25-year-old woman underwent appendectomy. 20 hours after the surgery, she was complaining of severe pain at the wound site with purulent discharges.

Blood pressure 100/55 mmHg
Heart rate 114 /min
Temperature 38.8 °C

Which of the following is the most appropriate management?

A. Dressing

B. Antibiotics

C. Observation

**D. Wound exploration

ICU
Increase INR

A 35-year-old man has been in the Intensive Care Unit with severe pancreatitis, ventilator dependence, and pneumonia for 2 weeks. He is receiving nutrition parenterally (see lab results).

Test Result Normal Values
Platelets count 184 150-400 x 109/L
Total bilirubin 4.6 3.5-16.5 µmol/L
APTT 36 30-40 sec
INR 2,1 0.8-1.2

Which of the following is the most appropriate management?

A. Factor X

**B. Vitamin K

C. Vitamin C

D. Factor VIII

Perforated diverticulitis
Laparotomy
Fever
CT Scan

A 58-year-old man had laparotomy with sigmoidectomy and colostomy for perforated diverticulitis, presented to the clinic complaining of intermittent attacks of fever for 1 week. Examination revealed normal chest and abdominal examination with healthy looking wound.

Blood pressure 116/68 mmHg
Heart rate 106 /min
Temperature 38.2 °C

Which of the following is the most appropriate next step?

A. Exploration

B. Reassurance

**C. CT scan abdomen

D. Plain chest X-ray

Abdominal pain
Distension
Tender abdomen
Ascites

A 41-year-old man underwent laparoscopic cholecystectomy 5 days back started to experience severe abdominal pain and distension. Examination revealed a distended tender abdomen (see report).

Blood pressure 100/55 mmHg
Heart rate 103 /min
Temperature 37.9 °C

Ultrasound:
Revealed the presence of ascites.

Which of the following is most appropriate management?

A. Endoscopic retrograde cholangio pacreaticogram

**B. Diagnostic laparoscopy

C. Exploratory laparotomy

D. Percutaneous aspiration

RLQ pain
Wound site pain
Anterior abdominal fascia Penetration
CT Scan

A 36-year-old man was stabbed in the right lower quadrant of his abdomen 1 hour back. He complained of pain at the wound site. Local wound exploration revealed penetration of the anterior abdominal fascia.

Blood pressure 110/62 mmHg
Heart rate 87 /min
Temperature 37.2 °C

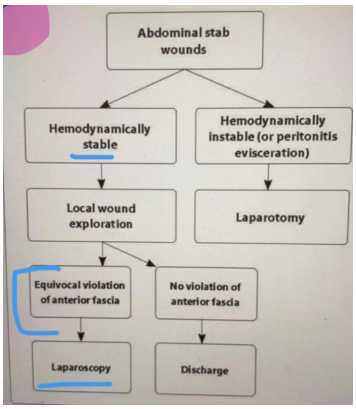

Which of the following is the most appropriate next step?

**A. CT scan abdomen

B. Hospital observation

C. Diagnostic laparoscopy

D. Exploratory laparotomy

A 40-year-old man had abdominal surgery 12 hours back; he noted drainage of 20 mL of fluid from her midline abdominal wound.

Which of the following is the most appropriate management?

A. Dressing

B. Antibiotics

C. CT scan abdomen

**D. Wound exploration

Laparotomy
Intestinal obstruction
Wound dicharge

A 40-year-old man who underwent a laparotomy and lysis for adhesive intestinal obstruction. On his regular follow up after discharge, there was discharges from the middle of the wound.

Which of the following is the most appropriate management?

A. Daily dressing

**B. Wound inspection

C. Abdominal CT scan

D. Wound exploration

Femoral hernia

A 63-year-old woman comes to the clinic for an annual check-up. On examination, she has a small and asymptomatic right femoral hernia.

Which of the following is the most appropriate management?

A. Observation

B. Open mesh repair

C. Open simple repair

**D. Laparoscopic repair

RUQ Pain
ERCP

A 45-year-old woman presented with postprandial right upper quadrant abdominal pain, nausea, and emesis for few days that became persistent for the last 20 hours (see lab results and report).

Blood pressure 110/70 mmHg
Heart rate 87 /min
Temperature 37.2 °C

Test Result Normal Values
WBC 11 4.5-10.5 x 109/L
Direct bilirubin 9.5 1.5-6.5 µmol/L
Total bilirubin 18.5 3.5-16.5 µmol/L
Alkaline phosphatase 463 39-117 IU/L

Ultrasound:
Cholelithiasis, gallbladder wall thickening, and a common bile duct of 12 mm.

Which of the following is the most appropriate management?

**A. Endoscopic retrograde cholangio pacreaticogram (ERCP)

B. Magnetic resonant cholangio pacreaticogram (MRCP)

C. Laparoscopic cholecystectomy

D. Conservative treatment

Liver parenchyma lesions
Liver Mets
Colon CA

A 73-year-old woman presents with new onset jaundice, generalized fatigability, weight loss and loss of appetite (see report).

CT scan:
Multiple lesions replacing approximately 70% of the liver parenchyma.

Which of the following is the most appropriate management?

Δ COLON CA
Metastasis to LIVER

**A. Colonoscopy

B. Upper GI endoscopy

C. Percutaneous biopsy

D. Diagnostic laparoscopy

Intubation

Which of the following confirms proper position of orotracheal intubation?

**A. Carbon dioxide monitor

B. Easy insertion

C. Movement of the chest

D. Distended abdomen

A trauma patient who lost 25% of his blood volume.

Blood loss
Pulse pressure

Which of the following is most expected to be decreased?

A. Urine output

**B. Pulse pressure

C. Respiratory rate

D. Glasco coma scale

Long bone fracture

Which of the following is the first priority when managing long bone fracture?

6th June DHA

A. Pain management

B. Improve function

**C. Decrease blood loss

D. Decrease soft tissue trauma

Fell from height
Heal pain

A 36-year-old man fell from a height of 4 meters, his GCS is 15 and vital signs are stable but he complains of severe bilateral heal pain.

Which of the following the most appropriate next step?

A. Pain control

**B. Examine pulses

C. Bilateral splint

D. Bilateral foot x-ray

Hit and run
Airway

An 18-year-old man involved in a hit and run, presented to the Emergency Room with multiple facial fractures and signs of severe brain injury.

Which of the following is the most appropriate next step?

**A. Secure airway

B. Consult neurosurgery

C. Secure cervical spine

D. Minimize fluid resuscitation

Vascular injury
Hard signs
Soft signs

Which of the following is a hard sign for vascular injury in a trauma patient?

A. Week pulse

**B. Palpable thrill

C. Skin color change

D. Extensive fractures

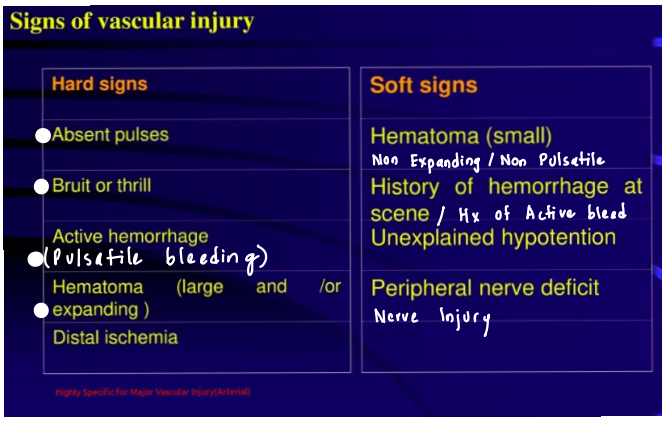

Which of the following is a hard sign for vascuoar injury?

A. Week pulse

**B. Audible bruit

C. Skin color change

D. Extensive fractures

Pregnant
abdominal trauma
Rh negative

A 23-year-old woman involved in a motor vehicle accident, after completing her primary and secondary survey and getting ready to transfer her to definitive care. Her pregnancy test was positive.

Which of the following will most indicates Rh immunoglobulin?

A. Rh positive, and abdominal trauma

**B. Rh negative, and abdominal trauma

C. Rh positive, and has a wrist fracture

D. Rh negative, and has a wrist fracture

Cardiac tamponade

A 42-year-old woman involved in a head on collision arrived at the Emergency Room talking coherently, with the following vital signs. Her examination revealed equal air entry bilaterally with ecchymosis on her anterior chest wall, distended neck veins and her abdomen is soft and lax.

Blood pressure 90/60 mmHg
Heart rate 130 /min
Respiratory rate 18 /min

Which of the following is the most likely diagnosis?

**A. Cardiac tamponade

B. Cardiac contusion

C. Massive heamothorax

D. Bilateral tension pneumothorax

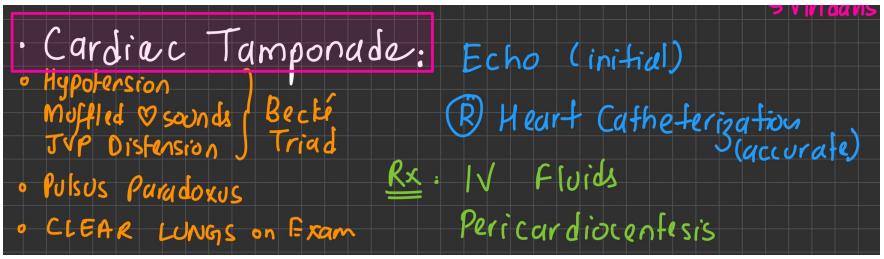

Motor vehicle accident
BP drop
Laparotomy

An 18-year-old man presented to a tertiary care hospital after he was involved in a motor vehicle accident. Primary survey was conducted and he was stabilized. While getting ready to transfer him his pressure dropped down (see report).

Blood pressure 60/40 mmHg

CT scan:
Thoracic aortic injury and a splenic laceration with free fluid in the abdomen.

Which of the following is the most appropriate transfer?

A. Angiography

**B. Operating room for laparotomy

C. Operating room for thoracotomy

D. A center that has a vascular surgeon

An 18-year-old man presented to the Emergency Room with bleeding from a deep 10 cm anterior laceration of his right thigh.

Which of the following is the most appropriate next step?

A. Apply tourniquet

B. Call a vascular surgeon

**C. Put direct pressure on the wound

D. Put pressure on the femoral artery above the wound

A 17-year-old girl was admitted with a 20% burn transferred to the burn unit for proper resuscitation.

Which of the following goals will most indicates that adequate resuscitation is achieved?

A. Normalizing heart rate

B. Normalizing blood pressure

**C. Urine out of 0.6 ml/kg/hr

D. Central venous pressure of 12

The vascular surgeon was called for help in the Operating Room by the colorectal surgeon who is doing a low anterior resection for colon cancer as he encountered pelvic bleeding that he could not control.

Which of the following is the most appropriate next step?

A. Do on table angiogram

**B. Heavily pack the pelvis

C. Infra renal aortic clamp

D. Supra celiac aortic clamp

Pelvic bleeding
BP drop
Aortic clamp

The vascular surgeon was called for help in the Operating Room by the colorectal surgeon who is doing a low anterior resection for colon cancer as he encountered pelvic bleeding that he could not control, the pelvis was packed and the bleeding slowed down but the patient dropped his pressure again.

Blood pressure 60/40 mmHg

Which of the following is the most appropriate next step?

A. Do on table angiogram

B. Infra renal aortic clamp

**C. Suprra celiac aortic clamp

D. Remove the packs and repair the injury

Lateral malleolus
Arterial ulcer

A 56-year-old woman presents to the clinic with a non-healing ulcer over her right lateral Malleolus, she is hypertensive but not diabetic.

Which of the following is the most appropriate next step?

A. Venous duplex

B. Arterial doppler US

**C. Examine distal pulses

D. Do ankle brachial index

Duplex

A 56-year-old woman presents to the clinic with a non-healing ulcer over her right lateral Malleolus, she is hypertensive but not diabetic. Her pulse examination is normal and her local examination shows dark discoloration of the skin around the ulcer and a viable ulcer bed.

Which of the following is the most appropriate next step?

A. CT angiogram

**B. Venous duplex US

C. Arterial doppler US

D. Conventional angiogram/venogram

A 7-year-old girl presents with a vascular anomaly on her left cheek.

Which of the following is the most likely diagnosis?

**A. Heamangioma

B. Venous malformations

C. Arterio-venouse fistula

D. Lymphatic malformations

Vascular malformation
CHF

A 13-year-old girl presents with a vascular malformation of her left leg that is growing over the years.

Which of following will most indicates treatment and intervention?

A. Pain

B. Claudication

C. Cosmetic reasons

**D. Congestive heart failure

History of trauma
Swelling of
Left leg

A 38-year-old woman presents with swelling of her left leg that is gradually increasing over the last 3 months, no history of travel or and surgeries over the last 6 months.

Which of the following is the most important further history to obtain?

A. Smoking

**B. History of trauma

C. Medication history

D. Family history of similar problems

Swelling of leg
Duplex ultrasound

A 38-year-old woman presents with swelling of her left leg that is gradually increasing over the last 3 months, no history of travel or surgeries or trauma over the last 6 months. Her distal pulses are palpable and her leg shows non-pitting edema with thickened skin and a dark discoloration.

Which of the following is the most appropriate next step in management?

A. CT angio

B. Conventional venogram

**C. Venous duplex ultrasound

D. Magnetic resonant venograoghy

🌹 Patient with unilateral left leg non-pitting edema, skin thickening and hyperpigmentation (dermal fibrosis) for 2 months. Next best appropriate step?
○ CT angiography. ○ MRV. ○ **Duplex US ✅ (initial and the next)**
NOTES: Non-Pitting edema is due to **Lymphedema**, Ultrasound is useful to exclude other etiologies like DVT, venous insufficiency and can also help in identifying tissue changes and masses that might be the cause of lymphatic compression.

A 38-year-old woman presents with swelling of her left leg that is gradually increasing over the

Swelling of leg
Lymphedema

last 3 months, no history of travel or surgeries or trauma over the last 6 months, no family history of similar problems. Her distal pulses are palpable and her leg shows non-pitting edema with thickened skin and a dark discoloration.

Which of the following is the most appropriate diagnostic test?

**A. Lymphoscintigraphy

B. Venous duplex ultrasound

C. Conventional angiography

D. Magnetic resonant venography

Lymphedema

A 38-year-old woman presents with swelling of her left leg that is gradually increasing over the last 3 months, no history of travel or surgeries or trauma over the last 6 months. Her distal pulses are palpable and her leg shows non-pitting edema with thickened skin and a dark discoloration.

Which of the following is the most appropriate management?

A. Anticoagulation

B. Lymphatic bypass

C. Prophylactic heparin

**D. Lymphatic massage and compression bandage

A 70-year-old man presents with abdominal pain. Examination revealed a pulsatile abdominal mass felt on deep palpation with mild tenderness just above the umbilicus (see lab results and report).

Blood pressure 110/70 mmHg
Heart rate 76 /min
Respiratory rate 14 /min
Temperature 36.6 °C
Oxygen saturation 99 %

Test Result Normal Values
RBC 6.0
4.7-6.1 x 1012/L (Male)
4.2-5.4 x 1012/L (Female)
Hb 135 130-170 g/L (Male)
120-160 g/L (Female)
HCT 0.42 0.42-0.52 (Male)
0.37-0.48 (Female)
Platelets count 155 150-400 x 109/L
WBC 13.5 4.5-10.5 x 109/L
Sodium 136 134-146 mmol/L

Potassium 4 3.5-5.1 mmol/L
Bicarbonate 25 21-28 mmol/L

Upright chest x-ray:

No air under diaphragm.

Which the following is the most appropriate lab investigation to be ordered next?

A. Cl level

**B. Amylase level

C. Calcium level

D. Arterial blood gas

Pulsatile abdominal mass
CTA

A 70-year-old man presents with abdominal pain. Examination revealed a pulsatile abdominal mass felt on deep palpation with mild tenderness just above the umbilicus (see lab results and report).

Blood pressure 110/70 mmHg
Heart rate 76 /min
Respiratory rate 16 /min
Temperature 36.6 °C
Oxygen saturation 99 %

Test Result Normal Values
RBC 6.0 4.7-6.1 x 1012/L (Male)
4.2-5.4 x 1012/L (Female)
Hb 135 130-170 g/L (Male)
120-160 g/L (Female)
HCT 0.42 0.42-0.52 (Male)
0.37-0.48 (Female)
Platelets count 155 150-400 x 109/L
WBC 13.5 4.5-10.5 x 109/L
Sodium 136 134-146 mmol/L
Potassium 4 3.5-5.1 mmol/L
Bicarbonate 25 21-28 mmol/L
Alanine aminotransferase 10 5-40 IU/L
Aspartate aminotransferase 20 12-40 IU/L
Amylase 100 24-151 IU/L
Lactate dehydrogenase 70 60-160 IU/L
Lipase 100 0-160 IU/L
Urea 3.5 2.75-7.4 mmol/L
Blood urea nitrogen 7.0 2.8 to 8.9 mmol/L
Creatinine 69 44-115 µmol/L

Upright chest x-ray:
No air under diaphragm.

Abdominal X-Ray:
Unremarkable.

Which of the following is the most appropriate diagnostic test?

A. US abdomen

**B. CT angiogram

C. MR angiography

D. Conventional angiography

A 5-day-old cyanotic infant with a diagnosis of Tricuspid Atresia.

ETHICS

Which of the following is the most important issue to consider during the discussion with parents?

A. Make sure that you have left no question unanswered

B. Make sure the parents understand the dismal prognosis

C. Make sure the parents understand that you are doing everything you can

**D. Make sure you leave the parents with a follow-up plan and provide them cardiac consultation

ETHICS

A 3-month-old infant diagnosed with congestive heart failure with follow-up by cardiology. Mother asks regarding the nutritional needs for her infant.

What is the most appropriate counseling should be given?

A. Less than a healthy infants

B. The same as 2-year-old infant

C. The same as a healthy infants

**D. Greater than a healthy infants

A 7-year-old boy case of congestive heart failure on digoxin.

ETHICS
Child participation

Which of the following is the most important step to improve his compliance?

A. Explain to child's parents

B. Send a nurse to his home to check on compliance

**C. Having the child participate in devising the plan

D. Inform the family about side effects of medication

ETHICS

Which of the following is the best advice to decrease anxiety of a child's parents who is scheduled for cardiac surgery?

A. Obtain an order for anti-anxiety medication for the parents

**B. Explain the steps that will occur before and after surgery

C. Send education material to parents and the child about the surgery

D. Tell the parents not to worry, because the surgeon performs this procedure daily

TOF
Squats

A child with tetralogy of fallot present for regular check-up. Mother asks why her child squats after exertion.

Which of the following is the best explanation?

A. Reduces muscle aches

**B. Increases cardiac efficiency

C. Enhances the pull of gravity

D. Decreases blood volume in the extremities

Baby spitting up

A 6-week-old infant presents to Well Baby Clinic by the mother complains that her baby "spitting up" all formula since birth. The baby weighs 5.5 kg and birth weight was 3.4 Kg.

What is the most appropriate counseling should be given?

A. Refer the child to a pediatric gastroenterologist

B. Return home and relax; the child will grow out of it

C. Start investigating the child for pyloric stenosis immediately

**D. Increase the time spent burping the infant and keep the infant semi upright after feedings

Counselling ADHD

A 10-years-old boy diagnosed attention deficit hyperactivity disorders, presents with his mother the clinic. She complains about his behavior. She is advised to identify and reward positive behaviors and ignore disruptive.

Which of the following helps to achieve this advice?

A. Systemic family therapy

B. Parent training programs

**C. Behavior management techniques

D. Time-out from positive reinforcement

Counselling

A 2-year-old boy presents with his mother complains that her child rebelling constantly with temper tantrums.

What is the most appropriate counseling should be given?

A. Use time out technique

**B. Set limits on the child's behavior

C. Punish the child every time the child says "no"

D. Allow the behavior because this is normal at this age period

Advising a mother regarding introducing solid foods to her child diet.

Counselling

Which of the following is the most appropriate advice?

A. Mix different foods together

B. Begins with one tablespoon of food

C. Eliminate a refused food from the diet

**D. Introduces each new food 4 to 7 days apart

MILESTONES When assessing development in a 9-month-old infant, which of the following is expected to observe at this age?

A. Creeping along the floor

B. Speaking in 2-word sentences

**C. Grasping objects with palmar grasp

D. Beginning to use a spoon rather sloppily

MILESTONES A 7-month-old infant visits Well Baby Clinic.

Which of the following this infant should be able to do?

A. Release cubes into a cup

B. Hold crayon and draw a circle

**C. Transfer objects from one hand to the other

D. Use thumb and index finger in crude pincer grasp

Counselling A 4-year-old child known to have bronchial asthma presents with the mother for primary clinic checkup. There is family history of asthma and father smokes at home.

What is the most appropriate counselling should be given?

A. Reassure the mother for now

B. Refer the child for allergy test

C. Prescribe inhaled steroid for regular use

**D. Counseling his parents regarding smoking cessations

Counselling A 12-year-old boy complains of bilateral leg pain at night time. He is diagnosed with growing pain.

What would be the best management?

A. Refer to orthopedic clinic

B. Use aspirin to relive the pain

C. Request bilateral lower limp X-ray

**D. Reassure the mother and the child

Counselling A 2-day-old baby seen in clinic with mother for counselling about breastfeeding.

Which of the following indicates adequate breastfeeding in a baby?

**A. Stool 4 times/day

B. Urine 2-3 times/ day

C. Does not cry frequently

D. Baby sleeps 2 hour after feeds

Counselling

A 20-day-old premature baby brought to the clinic with the mother for counselling about breast feeding.

Which of the following is low in mother's milk after premature delivery?

A. Fat

B. Protein

**C. Lactose

D. Sodium

Counselling

A 2-week-old baby girl brought by her mother to the clinic because she noticed mucus vaginal discharge. Baby is product of spontaneous vaginal delivery with normal urine and stool. Diagnosis is mucoid vaginal discharge.

Which of the following is the best response to this mother's concern?

A. Take swab

B. Request urinalysis

C. Refer to pediatrician

**D. Reassure the mother

ETHICS
DKA
Compliance

A 7-year-old boy presented to Emergency Department with newly diagnosed acute diabetic ketoacidosis.

Which of the following is most essential element in management plan to ensure compliance?

A. Refer to health educator

B. Provide written management plan

C. Involve the child in type1 diabetic patient's group

**D. Listen closely to the child's concerns and questions

Denial stage

A 7-year-old boy admitted with acute diabetic ketoacidosis. Mother states that her son was diagnosed with type1 diabetes mellitus started on insulin but she decided to stop it, as she was not sure of her son's diagnosis and thought to give chance for his pancreas to recover.

Which of the following term describes the mother action?

**A. Denial

B. Anxiety

C. Neglect

D. Depression

Agenda

A 9-year-old boy just diagnosed with growth hormone deficiency. In family meeting with the child and his patents after making introductions, the doctor makes the following comment, "I'd like to go over the diagnosis, then talk about what might happen next, that's to say how you might progress, then I'll try to answer all your questions"

Which of the following describes doctor phrase?

A. Probing

**B. Agenda setting

C. Safety netting

D. Checking understanding

Positive reinforcement
School phobia

An 8-year-old girl complaints of recurrent periumbilical pain lasting for 10-15 min morning time, no vomiting or loose stools. Abdomen examination is normal. Urine and stool analysis are normal. Mother says this pain is only during school days. Counseling to the mother and the teacher to manage school phobia/refusal includes behavior-management strategies such as providing positive reinforcements.

Which of the fowling is an example of positive reinforcements?

A. Allow student to have more TV time at home

**B. Comments focus on what the student did right

C. Give the student moderately challenging task to perform

D. Keep records of number of absent days during the semester

Neglected
Malnutrition
Ethics

A 6-year old girl presents to the clinic with malnutrition. She seems to be neglected with poor hygiene. Her mother express feeling anxious and busy with other children at home with poor social circumstances. During consultation, it is essential to explore mother perspective, feeling, ideas and beliefs.

Which of the following is the best next step?

A. Refer to social worker

B. Use close ended questions

C. Refer mother to psychiatry

**D. Encourage the mother to use her own words to clarify the issues

Neglected
Malnutrition
Counselling
Ethics

A 6-year-old boy presents with his mother to outpatient clinic with malnutrition, he seems to be neglected with poor hygiene.

Which of the following is an important skill needed to conduct consultation?

A. Lay out the consulting room with toys

B. Ask the mother to leave the room

C. Call the nurse to take vital sings, height and weight

**D. Put aside time at the beginning to build rapport with him

Ethics
Communication skills
Summary

A 42 hours-old full-term infant has not yet passed meconium was diagnosed with cystic fibrosis after Sweat chloride test. Family meetings with parents to discuss the diagnosis, management plan. The physician pulls together the main ideas, plan of management, prognosis and feelings of the parents to show understanding.

Which of the following describe the technique in this communication skill?

A. Reflection

**B. Summarizing

C. Paraphrasing

D. Verbal mirroring

Child Abuse
Burns
Communications skills
Report

A 14-month-old child is brought by his father with 2nd degree burns on both feet. He states that the child dipped in very hot bathtub water. There is a clear distinction line on the burn with no splash burns. There are other burses on the child limps of different age. Child abuse suspected.

Which of the following is the correct order of the four important advocacy skills for mandated reporters of child abuse?

A. Observing, documenting, reporting, self-care

B. Documenting, confirming, reporting, conferencing with parents

C. Observing, gathering information, making referrals, following up

**D. Observing, making referrals, gathering information, following up

Ethics
Disassociation

A 10-year-old boy comes with his uncle for follow-up after major car accident where he lost his mother and his 2 brothers. The uncle is worried after receiving teacher's note regarding child behavior in the class. Teacher wrote that the child becomes unresponsive sometimes, has a lapse in attention. He stares at nothing, and act as if he just woke up in response to being called to attention.

Which of the following term describe child's response mechanism?

A. Blame

B. Anger

C. Denial

**D. Disassociation

Ethics
Suicide

A 15-year-old boy brought by concerned mother for an evaluation her son problem of 3 months after the death of his friend in car accident, reluctantly mentioned to his mother that he wished he were dead, but would never do anything about these wishes.

Which of the following is the most appropriate action?

A. Asking him about his suicide may increase the risk

B. Indirect inquiries about his suicide risk will foster rapport

C. Since this is a normal grief reaction, he should be left alone

**D. Detailed questions about his suicidality are essential for prevention

Ethics
Language barrier

Surgical intern is assigned to stay with a 6-year-old boy who is waiting to have surgery to repair a cleft palate. The boy does not speak Arabic and appears anxious. The charge nurse has requested a translator but the translator has not yet arrived.

Which of the following is the most appropriate action for the intern to do?

A. Insert IV cannula and start preanesthetic

B. Sedate the child to decrease her anxiety level

C. Suggest that the nurse stay with the child so that he can review her chart

**D. Listen to the child's heart with a stethoscope and then let the child try to use the stethoscope to listen to his heart

Ethics
Panic attacks

A 15-year-old girl presents to the Emergency Department with chest pain, nausea, dizziness, and sweating. She states that she is afraid he is going to die. History includes 3 previous episodes during the past 2 months, each episode lasting about 15 minutes. She has been afraid to visit the doctor but she has become more afraid during the past month of having yet another episode.

Which of the following is the most likely diagnosis?

A. Malingering

B. Agoraphobia

**C. Panic attack

D. Factitious disorder

Ethics
Empathy
Communication skill

An effective interviewing skill behaviors of listening carefully by entering the world of the patient and communicating that you imagine the patients world as the patient sees and experiences it. Yet, not becoming the patient and remain separate from the patient.

Which of the following is the communication skill described above?

**A. Empathy

B. Transfernce

C. Respect and warmth

D. Authenticity or congruence

An angry father comes to the clinic because his 16-year-old daughter request to join sport class.

He claims that she was encouraged by her mother to do so and ask the doctor if he can convince her after physical examination that she is not fit. During consultation, the doctor needed to gather more information using confrontational communication skills.

Which of the following is an example of a confrontational response?

A. "I totally agree with your opinion"

B. "I can see that you have been worried a lot"

C. "you have been through this very thing myself"

**D. "You are looking very upset. What is happening?"

Which of the following is the appropriate action when caring for parents immediately after a newborn death?

A. Discussing future risk of malformed baby

B. Ask the father if he wants to file complaint

C. Arrange for early follow up with primary care

**D. Allowing the mother to spend time with her dead baby

PEADETRICS

Reassurance

A 15-month-old child brought to the clinic by his parents. He was born at 36 weeks by normal vaginal delivery. At 8 month' test for hearing was done, which was normal. The parents say that he babbles, but does not speak 2-3 word phrases yet. On physical examination, the child appears normal.

Which of the following is the appropriate action?

A. Refer to ENT

B. Reassess at 24 months

C. Arrange for audiometry testing

**D. Reassure the parents that this is a normal variant

A 12-month-old child with acute gastroenteritis seen in Emergency Department and being discharged with dietary advice and important worrying symptoms that need immediate care.

Which of the following describes the technique in this step?

A. Reflection

B. paraphrasing

**C. Safety netting

D. Verbal mirroring

Ethics

Which of the following is a common reaction to a parent's illness in 12-year old girl considering her developmental stage?

**A. Difficulty speaking directly about strong or difficult feelings

B. Unable to understand or appreciate details of diagnosis, prognosis and treatment

C. Incorporate themes of illness in their play, such as pretending to have their parent's symptoms

D. Likely to shift to earlier, less mature behaviors (e.g., fussiness, difficulty with separations or bedtime

Which of the following is the most successful strategy to prevent poisoning among young children?

A. Education about the risk using social media

B. Educating daycare providers on poisoning risks

C. Provide parents with education material regarding safety

**D. Enforce legislation to require childproof caps on hazardous household cleaners and medicines

Counselling

An 8-week-old infant presents by his mother to Well-Baby Clinic worried about her baby crying with diagnosis of infantile colic.

Which of the following is the most appropriate counseling should be given?

A. Infants cry an average of 5 hours per day, peaking at 6 weeks of age and gradually decreasing

B. Infants cry an average of 6 hours per day, peaking at 6 weeks of age and gradually increasing

C. Infants cry an average of 2 hours per day, peaking at 6 month of age and gradually decreasing

**D. Infants cry an average of 2.2 hours per day, peaking at 6 weeks of age and gradually decreasing

Counselling

A 2-year-old boy brought by his mother to clinic asking for help to control her child behavior. The child seems to be stubborn and he throws his toys away. When she walks him to daycare, he refuses to hold her hand, attempts to run away from her.

Which of the following is the most appropriate technique dealing with his behavior?

A. Spanking

**B. Time-out

C. Scolding

D. Verbal warning

Which of the following best describes time-out technique to control child behavior?

**A. Last 1 min/yr. of age

B. Last at least 10-15 min

C. If accompanied by penalty

D. If accompanied by verbal warnings

A 7-year-old boy with a diagnosis of separation anxiety. The mother asks for consultation.

Which of the following is the most appropriate strategy that the mother should do?

A. Let your child focus on what unlikely bad things might happen

B. Let your child stay home when he does not want to go to school

C. Punish for behaviors that are a result of separation anxiety/fears

**D. Help him think of ways a favorite superhero might handle the situation

Which of the following is most appropriate counseling regarding storage and handling of breast milk?

A. Can be frozen for up to 12-18 months

B. After freezing can be refrozen if not used

C. Can be stored up to 4-6 months in the refrigerator

**D. Can be safely stored up to 4-10 hours at room temperature

In consulting a new mother about vaccination, the doctor mentioned, "Giving your child a vaccination against a disease dramatically lowers the risk of him catching the illness which could be extremely harmful to him both in the short and long-term. By stopping the disease developing in your child, we also stop your child being able to spread the disease." The doctor asked the mother "Does everything I've said so far make sense?"

Which of the following describes doctor last phrase?

A. Paraphrasing

B. Safety netting

C. Verbal mirroring

**D. Check understanding

A 2-hour-old baby delivered by emergency cesarean section because of placental abruption, and required resuscitation with intubation and cardiac message (see lab results).

Test Result Normal Values
ABG HCO3- 7 13-22 mmol/L
ABG PCO2 65 27-40 mmHg
pH 6.9 7.36-7.45
ABG PO2 5 8-24 mmHg (Newborn)
55-80 mmHg (Child)
Base access -18 -2 to 2 mmol/L

Which of the following proven to reduce death and sever disability within 6 hours?

A. Fluid restriction

**B. Mild hypothermia

C. Respiratory support

D. Treatment of hypotension

6th June DHA

Newborn delivered with ventouse due to malposition. While assessment in the nursery, a hematoma from bleeding below the periosteum confined within the margins of the skull sutures noted.

Which of the following is the most likely diagnosis?

TABLE 2.12-13. Neonatal Extracranial Injuries

TYPE OF INJURY	DESCRIPTION
Caput succedaneum	Edema or hematoma of the scalp that commonly occurs secondary to vacuum extraction Located above the periosteum and crosses suture lines; resolves spontaneously without treatment
Cephalhematoma	Hematoma that forms below the periosteum commonly over the parietal or occipital bone and does not cross suture lines; resolves spontaneously without treatment Complications: Infection and infant jaundice (due to breakdown of a large hematoma)
Subgaleal hemorrhage	Bleeding into the subgaleal space between the periosteum and epicranial aponeurosis (galea aponeurotica) due to injury to emissary veins by traction during delivery; presents as a fluctuant diffuse swelling that can shift with movement and crosses suture lines; the subgaleal space extends from orbital ridges anteriorly to the nape of the neck posteriorly and can hold 40% of a neonate's total blood volume, resulting in significant volume depletion and hemorrhagic shock; treatment is by volume resuscitation and correction of coagulopathy

A. Chignon

**B. Cephalohematoma

C. Caput succedaneum

D. Subaponeurotic hematoma

Respiratory distress syndrome

A 30-minute-old, preterm at 27-week, delivered by emergency cesarean section for maternal reason have tachypnea, labored breathing and chest wall recession.

Blood pressure 55\35 mmHg
Heart rate 135 /min
Respiratory rate 65 /min
Temperature 36.2 °C
Oxygen saturation 86 %

Which of the following is the most likely diagnosis?

A. Pneumothorax

B. Apnea of prematurity

**C. Respiratory distress syndrome

D. Transient tachypnea of newborn

Necrotizing enterocolitis is a serious illness affecting preterm infants in the first few weeks of life.

Which of the following is true in regard this condition?

**A. Its associated with bacterial invasion of ischemic bowel wall

B. Treatment required antibiotics but rarely parenteral nutrition

C. Has low morbidity and mortality compared with inguinal hernia

D. Preterm infants fed cow's milk formula have low risk to develop it

A 5-day-old girl brought to Emergency Room with lethargy and poor feeding. On examination, she was irritable, deeply jaundiced and dehydrated. The mother gave history of previous babies'

required admission and exchange transfusion (see lab results).

Blood pressure 90/55 mmHg
Heart rate 95 /min
Respiratory rate 18 /min
Temperature 36.6 °C
Oxygen saturation 94 %
Weight 3 kg

Test Result Normal Values
Hb 95 165-195 g/L (Newborn)
112-165 g/L (Child)
Reticulocyte 3 0.2-1.2 %
Total bilirubin 360 <274 µmol/L (Preterm (3-5) days)
<205 µmol/L (Term (3-5) days)
<21 µmol/L (Older infant pre-term)
<20.5 µmol/L (Older infant term)

Which of the following is important to be obtained in the history?

A. Apgar score

B. Birth weight

C. Type of delivery

**D. Maternal blood group

A term baby delivered by cesarean section, started to be tachypnic with nasal flaring and expiratory grunting. Chest X-ray showed fluid in the horizontal fissure. 6th June DHA

Blood pressure 60/35 mmHg
Heart rate 140 /min
Respiratory rate 65 /min
Temperature 36.6 °C
Oxygen saturation 92 %

Which of the following is the most likely diagnosis?

A. Pneumonia

B. Meconium aspiration

C. Respiratory distress syndrome

**D. Transient tachypnea of the newborn

A 6-hour-old newborn delivered by cesarean section because of sever fetal deceleration and meconium stained fluid. He required intubation and ventilation with inotropic support. Few hours later, he started to have low saturation with increase oxygen requirement. The pre ductal saturation is 92 while the post ductal saturation is 81. Chest X-ray done and showed no pneumothorax.

Which of the following is the next step in the management?

A. Surfactant lavage

B. Diuretics infusion

**C. Inhaled Nitric Oxide

D. Chest tube insertion

A term infant delivered with antenatal diagnosis of diaphragmatic hernia. She required vigorous resuscitation in the delivery room.

Which of the following is the first step in managing this infant after stabilization?

A. Starting antibiotics

B. Chest tube insertion

C. Immediate surgical repair

**D. Large nasogastric tube insertion

In colonized mother with Group B Streptococcal infections, which of the following is risk factor for infection in the newborn?

**A. Preterm baby

B. Twin pregnancy

C. Gestational diabetes

D. Rupture of membranes for 6 hours

In managing infant of diabetic mother who required high level of glucose infusion concentration up to 20% to control the hypoglycemia.

Which of the following route is preferred to give the glucose infusion?

A. Orogastric tube

B. Nasogastric tube

**C. Central venous catheter

D. Peripheral venous catheter

The illnesses and problems children encounter are highly age dependent.

Which of the following represent an infant age group?

A. Less than 4 weeks

B. Less than 6 month

**C. Less than 1 year

D. Less than 2 years

Embryo: fertilization to 8 weeks

Fetus: 8 weeks to birth

Infant: birth to age 1 year

During normal newborn exam, an absent red reflex in the eye and cardiac mummer are discovered. After interviewing the mother, she gave a history of viral infection during the first trimester.

Which of the following infection can cause this?

**A. Rubella

B. Syphilis

C. Toxoplasmosis

D. Cytomegalovirus

A child who can jump on 2 feet, build a tower of 6 blocks, use 2 word phrases and compares 2 items.

What is the developmental age?

A. 1 year

**B. 2 years

C. 3 years

D. 4 years

A 4-year-old boy present to the clinic with a worried mother, for general assessment and evaluation of his development. He can hop on 1 foot but not able to balance for 10 seconds, draw square, tells a story but not able to use the future tens and has a preferred friend.

Which of the following is the most appropriate response to his mother?

**A. He is growing normally according to his age

B. He has delayed development in gross and fine motor aspect

C. He is growing normally but delayed in the speech and language

D. He is delayed in all aspect and required further investigation

Which of the following cerebral palsy type is associated with Kernicterus?

A. Spastic

B. Ataxic

C. Hypotonic

**D. Dyskinetic

Sudden infant death syndrome (SIDS) defined as unexpected death of an infant for which no adequate cause is found after postmortem examination. The incidence of SIDS has fallen during the last 20 years.

Which of the following contribute the most for fallen in the incidence?

**A. Infant to be put to sleep on their back

B. Parents avoid smoking near their infant

C. Infant to be placed in the feet to foot position

D. Avoid overheating by heavy rapping or high room temperature

A 4-year-old child presented to the clinic with delayed language and speech, and learning difficulties.

Which of the following is the most appropriate test?

A. ECG

B. EEG

C. CT brain

**D. Hearing test

A 5-year-old girl presented to Emergency Room with high-grade fever, vomiting and severe diarrhea for the last 2 days (see lab results).

Blood pressure 110/70 mmHg
Heart rate 130 /min
Respiratory rate 30 /min
Temperature 39.2 °C
Oxygen saturation 96 %

Test Result Normal Values
ABG HCO3- 18 13-22 mmol/L
ABG PCO2 25 27-40 mmHg
pH 7.32 7.36-7.45
Base access -4 -2 to 2 mmol/L

Which of the following describes her shock status?

**A. Early compensated shock

B. Late compensated shock

C. Late uncompensated shock

D. Early uncompensated shock

A 4-year-old boy presented to Emergency Room with fever, sever vomiting and diarrhea. On examination, she is tachypnic, tachycardic and has mottled skin with decrease skin turgor (see lab results).

Blood pressure 110/70 mmHg
Heart rate 125 /min
Respiratory rate 28 /min
Temperature 38.5 °C

Oxygen saturation 97 %

Test Result Normal Values
ABG HCO3- 19 13-22 mmol/L
ABG PCO2 25 27-40 mmHg
pH 7.30 7.36-7.45
Base access -3 -2 to 2 mmol/L

Which of the following clinical sign can be observed?

A. Blue peripheries

B. Kussmaul breathing

**C. Decrease urine output

D. Depressed cerebral state

A 6-year-old boy presented to Emergency Department with severe vomiting and diarrhea.

Maintainance Fluid

Blood pressure 110/70 mmHg
Heart rate 120 /min
Respiratory rate 22 /min
Temperature 38 °C
Oxygen saturation 98 %
Weight 18 kg

After stabilization and fluid resuscitation, how much the volume of maintenance fluid intake per hour she required?

A. 47

**B. 56

C. 65

D. 70

Children with septic shock need to be rapidly stabilized and resuscitated for their life saving.

Which of the following has lowest evidence of benefit in their management?

A. Antibiotics

**B. Steroids

C. Inotropic support

D. Fluid resuscitation

A 7-year-old boy presented to the Emergency Room with acute stridor, tachypnea, pallor and hypotension. In quick history, the mother mentioned he was attending a party in the school and that he has food allergy.

Which of the following is the first step in management?

A. Steroid

B. Antibiotics

**C. Adrenaline

D. Fluid bolus

A 3-month-old girl presented dead to the hospital by her parents. History revealed that the girl was preterm with low birth weight and chronic lung disease. She was sleeping with her parents on their bed and both parents are smoker.

Which of the following describes her death?

A. Acute lung failure syndrome

**B. Sudden infant death syndrome

C. Apparent life-threatening syndrome

D. Unexpected oxygen insufficiency syndrome

A 3-year-old boy presented with his family to the Emergency Room after ingestion unknown amount of paracetamol tablets. He is quite, with accepted vital sign and normal examination. According to his mother, the bottle was containing small amount of the syrup, and she found some of it spelled over his clothe. He is observed for 4 hours and clinically there is no change on his condition.

Which of the following is the proper disposition for him?

A. Performed gastric lavage

B. Monitor for another 4 hours

**C. Discharge home with instruction

D. Start intravenous acetylcysteine

Overdose Acetaminophen Toxicity

An 8-year-old girl presents to the Emergency Room by her mother after ingestion of large amount of acetaminophen tablets. According to the mother, she ingested full 2 packs, containing 20 tablets, 1 day ago after she had fight with her. On examination, she has right upper quadrant abdominal pain, with nausea and vomiting.

Blood pressure 95/50 mmHg
Heart rate 135 /min
Respiratory rate 25 /min
Temperature 36.6 °C
Oxygen saturation 95 %

Which phase of acetaminophen toxicity she is at?

A. Phase 1

**B. Phase 2

Stage	*Time after ingestion*	*Characteristics*
Stage 1	0 to 24 hours	Nausea, vomiting, diaphoresis, anorexia
Stage 2	24 to 48 hours	Clinically improved Serum AST (SGOT), serum ALT (SGPT), serum bilirubin and prothrombin time begin to rise
Stage 3	72 to 96 hours*	Peak hepatotoxicity Serum AST of 20,000 IU not unusual
Stage 4	4 to 14 days	Recovery

** —Patients who are treated late or remain untreated maintain high levels of enzymes beyond 72 to 96 hours.*
(Adapted from Linden CH, Rumack BH. Acetaminophen overdose. Emerg Med Clin North Am 1984;2:103-19.)

Stage	Time after Ingestion	Characteristics
I	0.5–24 hrs	Anorexia, nausea, vomiting, malaise, pallor
II	24–48 hrs	Right upper quadrant abdominal pain and tenderness; elevated bilirubin, prothrombin time, hepatic enzymes; oliguria
III	72–96 hrs	Peak liver-function abnormalities; anorexia, nausea, vomiting, malaise may reappear
IV	4 d–2 wks	Resolution of hepatic dysfunction or fulminant hepatic failure

Modified from Linden CH, Rumack BH. Acetaminophen overdose. *Emerg Med Clin North Am.* 1984;2:103.

C. Phase 3

D. Phase 4

An 8-year-old girl presents to the Emergency Room by her mother after ingestion of large amount of acetaminophen tablets. According to the mother, she ingested full 2 packs, containing 20 tablets, 1 day ago after she had fight with her. On examination, she has right upper quadrant abdominal pain, with nausea and vomiting.

Blood pressure 95/55 mmHg
Heart rate 130 /min
Respiratory rate 25 /min
Temperature 36.6 °C
Oxygen saturation 96 %

Which of the following is the most important antidote according to her stage of toxicity?

A. Desferrioxamine

B. Activated charcoal

**C. N Acetylcysteine

D. Antidote is not indicated at this stage

Overdose
Toxicity
Iron

A 6-year-old girl presents to the Emergency Room with her father after ingestion of large amount of iron tablets. She ingested full bottle containing >20 tablets, 3 hours ago. On examination, she has acute abdominal pain, with nausea, vomiting and diarrhea, and she passed 2 times melaena.

6th June DHA

Blood pressure 100/60 mmHg
Heart rate 120 /min
Respiratory rate 26 /min
Temperature 36.6 °C

Which of the following is the most appropriate treatment option at this stage?

A. Gastric lavage

B. N acetylcysteine

**C. Intravenous desferrioxamine

D. No antidote required at this stage

Which of the following carry a high risk to induce fabricated illness in the child?

A. Father

**B. Mother

C. House maid

D. Step mother

A 6-month-old girl presents to the Emergency Room by an ambulance with unexplained loss of conscious. Her mother appeared to have learning difficulties, and her father explained that suddenly the child went all floppy and asleep. CT brain showed subdural hemorrhage, chest x-ray showed old fractures, and eye exam showed retinal hemorrhage.

Which of the following is the most likely diagnosis?

**A. Child abuse

B. Bone disease

C. Blood disease

D. Metabolic disease

A 6-month-old girl presents to Emergency Room by ambulance with unexplained loss of conscious. Her mother appeared to have learning difficulties, and her father explained that suddenly the child went all floppy and asleep. CT brain showed subdural hemorrhage, chest x-ray showed old fractures, and eye exam showed retinal hemorrhage. After short time, the child start to cry and the parents want go home against the advice for admission.

Which of the following is the most appropriate action?

A. Discharge on parent responsibilities

B. Discharge with follow up after 2 weeks with neurosurgery

C. Convince the family to continue observing her 4 hours more

**D. Contact child protection agency and force the family to stay

Which of the following has the lower incidence to result in Down syndrome?

**A. Mosaicism

B. Translocation

C. Meiotic disjunction

D. Meiotic non disjunction

A newborn in nursery with multiple congenital anomalies in form of prominent occipit, overlapping fingers, rocker-bottom feet and cardiac malformation. Chromosomal analysis sent awaiting the result.

6th June DHA

Which of the following is the most likely diagnosis?

A. Down syndrome

**B. Edward syndrome

C. Patau syndrome

D. Turner syndrome

Edwards syndrome	Trisomy 18, which occurs due to meiotic nondisjunction	Presents with severe intellectual disabilities, rocker bottom feet, low-set ears, micrognathia, clenched hands (overlapping of the index finger over the third finger and the pinky over the fourth finger), and a prominent occiput	CHD (most often VSD, PDA) GI involvement common (Meckel diverticulum, malrotation) Renal involvement (eg, horseshoe kidneys, vesicoureteral reflux, and other anomalies)	Second most common autosomal trisomy Death usually occurs within 1 year of birth Associated with advanced maternal age 3:1 female-to-male ratio

A 10-year-old child presents to the clinic with cutaneous manifestations. She had 7 cafe-aulait

spots, 2 neurofibroma and axillary freckles. The mother mentioned a presence of nephew who had similar lesions.

What is mode of inheritance of this disease?

**A. Autosomal dominant inheritance

B. Autosomal recessive inheritance

C. X-linked dominant inheritance

D. X-linked recessive inheritance

NEUROFIBROMATOSIS

The most common neurocutaneous disorder. There are two major types: neurofibromatosis 1 (NF1, or von Recklinghausen syndrome) and neurofibromatosis 2 (NF2). Both are autosomal dominant diseases caused by mutations to tumor suppressor genes.

History/PE

Diagnostic criteria for NF1 include two or more of the following:

1. Six café au lait spots (flat, uniformly hyperpigmented macules).
2. Two neurofibromas (benign peripheral nerve sheath tumors) of any type (see Fig. 2.9-24).
3. Freckling in the axillary or inguinal area.
4. Optic glioma (mainly patients under age 6 years).
5. Two Lisch nodules (pigmented iris hamartomas). These are the most specific clinical features of NF1.
6. Bone abnormality (eg, kyphoscoliosis).
7. A first-degree relative with NF1.

Diagnostic criteria for NF2 are as follows:

- Bilateral vestibular schwannomas (also known as acoustic neuromas)
- First-degree relative with NF2 and either:
  - Unilateral acoustic neuromas, or
  - Two of any of the following tumor types: neurofibroma, meningioma, glioma, or schwannoma
- Other features, including seizures, skin nodules, and café au lait spots

A 10-years-old child presents to the clinic with cutaneous manifestations. She had 7 cafe-aulait spots, 2 neurofibroma and axillary freckles. The mother mentioned a presence of nephew who had similar lesions.

Which of the following is the most likely diagnosis?

A. Tuberous sclerosis

B. Angiofibromata type 2

C. Sturge-Weber syndrome

**D. Neurofibromatosis type 1

While reviewing expanded family pedigree for a child presented to the clinic for investigation and diagnosis. It found that there is a 25% risk for 2 carrier parents to have affected child and the risk increase with consanguinity.

Which of the following is the inheritance?

**A. Autosomal recessive

B. Autosomal dominant

C. X-linked recessive

D. X-linked dominant

An 11-year-old presents to the clinic with the following features, macrocephaly, macro-orchidism long face, large everted ears and ECHO revealed the presence of mitral valve prolapse. He has significant joint laxity and moderate learning difficulties.

Which of the following is the most likely diagnosis?

A. Hunter syndrome

B. Hurler syndrome

C. Friedreich ataxia

**D. Fragile X syndrome

DISEASE	FEATURES/PRESENTATION	MODE OF INHERITANCE/NOTES
Fragile X syndrome	Caused by a defect affecting the methylation and expression of the *FMR1* gene A triplet repeat disorder that may show genetic anticipation Presents in childhood; features include long and narrow face, prominent forehead and chin, large ears, testicular enlargement, and autistic behaviors	X-linked dominant The second most common genetic cause of intellectual disabilities

Which of the following phases contribute the most for the final height of the child?

A. Fetal phase

B. Infantile phase

**C. Childhood phase

D. Pubertal phase

Tanner

A child presents to the clinic for pubertal assessment. He had pubic hair filling out towards adult distribution, and darkening of scrotal skin.

Which stage of puberty he reached according to Tanner staging?

A. II

B. III

**C. IV

D. V

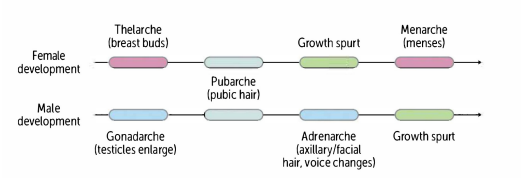

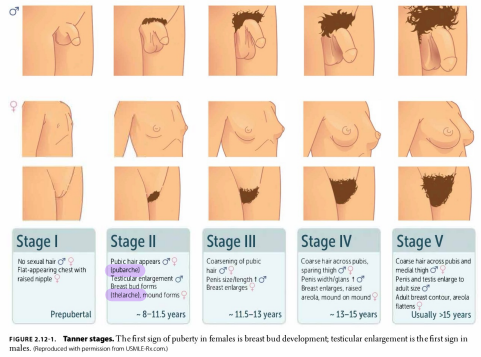

FIGURE 2.12-1. **Tanner stages.** The first sign of puberty in females is breast bud development; testicular enlargement is the first sign in males. (Reproduced with permission from USMLE-Rx.com.)

An 18-month-old girl presents with asymmetrical breast enlargement. There was no pubic hair growth or body odor and her height was in mid parental range. Her bone age was mildly advanced.

Which of the following is the best next step in management?

A. ACTH test

B. MRI brain

C. CT chest

**D. Pelvic ultrasound

A 2-year-old girl is brought by her mother with breast enlargement. There was no pubic hair growth or body odour and her height was in mid parental range.

Which of the following is the most likely diagnosis?

A. Precocious puberty

B. Premature pubarche

C. Central precocious puberty

**D. Premature breast development

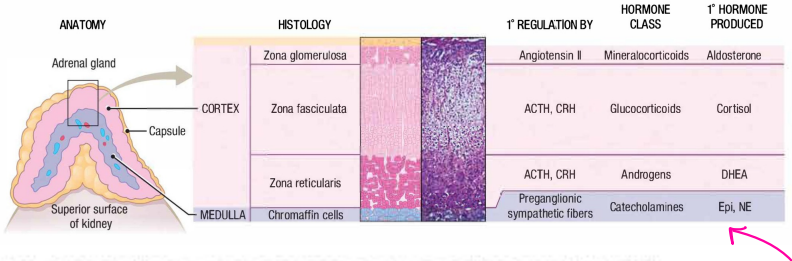

Ambiguous genitalia

A 24-hour-old neonate with ambiguous genitalia. 17-hydroxyprogesterone was abnormally high (see lab results).

Test Result Normal Values
Sodium 126 134-146 mmol/L
Potassium 7.1 3.5-5.1 mmol/L
Bicarbonate 15 21-28 mmol/L
Glucose 2.6 2.8-5 mmol/L (Newborn)
3.3 -5.5 mmol/L (Child)

21-Hydroxylase deficiency: ↑17-OH progesterone levels (a substrate for 21-hydroxylase). This is part of the newborn screen. Cosyntropin (ACTH) stimulation test—gold standard but not necessary if ↑↑ 17-OH.

11β-Hydroxylase deficiency: ↑ serum 11-deoxycortisol and 11-deoxycorticosterone.

TABLE 2.3-14. Overview of Congenital Adrenal Hyperplasia

ENZYME DEFICIENCY	MINERALOCORTICOIDS	CORTISOL	SEX HORMONES	BP	[K⁺]	LABORATORY TESTS	PRESENTATION
17α-hydroxylase[a]	↑	↓	↓	↑	↓	↓ androstenedione	XY: pseudohermaphroditism (ambiguous genitalia, undescended testes) XX: lack secondary sexual development
21-hydroxylase[a]	↓	↓	↑	↓	↑	↑ renin activity ↑ 17-hydroxyprogesterone ↓ sodium ↓ chloride	Most common Presents in infancy (salt wasting) or childhood (precocious puberty) XX: virilization
11β-hydroxylase[a]	↓ aldosterone ↑ 11-deoxycorticosterone (results in ↑ BP)	↓	↑	↑↓	↓	↓ renin activity	XX: virilization

[a]All congenital adrenal enzyme deficiencies are characterized by an enlargement of both adrenal glands caused by ↑ ACTH stimulation (caused by ↓ cortisol).

Which of the following is the correct management for this case?

A. Hydrocortisone and saline bolus

B. Saline bolus and glucose infusion

C. Antibiotics, hydrocortisone and glucose infusion

**D. Hydrocortisone, saline bolus and glucose infusion

MNEMONIC

For CAH, if the deficient enzyme begins with 1 (**1**1 and **1**7), mineralocorticoid activity is high. If it ends with 1 (1**1** and 2**1**), androgen activity is high.

A 24-hour-old neonate with ambiguous genitalia. 17-hydroxyprogesterone was abnormally high (see lab results).

Test Result Normal Values
Sodium 127 134-146 mmol/L
Potassium 6.8 3.5-5.1 mmol/L
Bicarbonate 15 21-28 mmol/L
Glucose 2.5 2.8-5 mmol/L (Newborn)
3.3 -5.5 mmol/L (Child)

Which of the following is the inheritance of this disease?

A. Multifactorial

B. X-linked dominant

C. Autosomal dominant

**D. Autosomal recessive

A 24-hour-old neonate with ambiguous genitalia. 17-hydroxyprogesterone was abnormally high (see lab results).

Test Result Normal Values
Sodium 128 134-146 mmol/L
Potassium 6.8 3.5-5.1 mmol/L
Bicarbonate 16 21-28 mmol/L
Glucose 2.5 2.8-5 mmol/L (Newborn)
3.3 -5.5 mmol/L (Child)

Which of the following is the most likely diagnosis?

**A. 21-hydroxylase deficiency

B. 17-hydroxylase deficiency

C. 11-beta hydroxylase deficiency

D. 3β-hydroxysteroid dehydrogenase deficiency

While counseling a new mother about the importance of the breastfeeding, she mentioned that currently she had a yellow-white substance coming from the breast and she is worried about feeding her baby.

Which of the following is correct regarding this yellow-white substance?

**A. It has high content of proteins

B. It will continue for 4 month normally

C. It should be discarded because the color

D. It has high content of lipid and glucose

A 3-year-old girl found during health campaign in poor area to have generalized edema, sever wasting, hyperkeratosis, distended abdomen and sparse hair (see lab results).

Blood pressure 85/45 mmHg
Heart rate 80 /min
Respiratory rate 25 /min
Temperature 36.0 °C

Test Result Normal Values
Sodium 132 134-146 mmol/L
Potassium 3.2 3.5-5.1 mmol/L
Magnesium 0.4 0.7-1.0 mmol/L
Glucose 3.1 2.8-5 mmol/L (Newborn)
3.3 -5.5 mmol/L (Child)
Albumin 20 36-52 g/L

Which of the following contributes to the finding?

A. Vitamin B12 deficiency

B. Vitamin D deficiency

**C. Sever protein malnutrition

D. Sever carbohydrate malnutrition

Kwashioror

A 3-year-old girl found during health campaign in poor area to have generalized edema, sever wasting, hyperkeratosis, distended abdomen and sparse hair (see lab results).

Blood pressure 85/45 mmHg
Heart rate 85 /min
Temperature 36.0 °C

Test Result Normal Values
Sodium 132 134-146 mmol/L
Potassium 3.0 3.5-5.1 mmol/L
Magnesium 0.4 0.7-1.0 mmol/L
Glucose 3.1 2.8-5 mmol/L (Newborn)
3.3 -5.5 mmol/L (Child)
Calcium total 2.1 2.2-2.7 mmol/L
Phosphate 1.2 1.3-2.3 mmol/L
Albumin 18 36-52 g/L

Which of the following is the most likely diagnosis?

A. Rickets

B. Marasmus

**C. Kwashiorkor ↓ protein diet ↑ carb diet

D. Coeliac disease

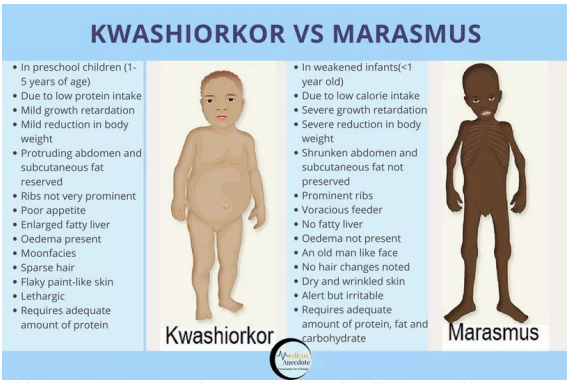
KWASHIORKOR VS MARASMUS
• In preschool children (1-5 years of age)
• Due to low protein intake
• Mild growth retardation
• Mild reduction in body weight
• Protruding abdomen and subcutaneous fat reserved
• Ribs not very prominent
• Poor appetite
• Enlarged fatty liver
• Oedema present
• Moonfacies
• Sparse hair
• Flaky paint-like skin
• Lethargic
• Requires adequate amount of protein
Kwashiorkor
• In weakened infants(<1 year old)
• Due to low calorie intake
• Severe growth retardation
• Severe reduction in body weight
• Shrunken abdomen and subcutaneous fat not preserved
• Prominent ribs
• Voracious feeder
• No fatty liver
• Oedema not present
• An old man like face
• No hair changes noted
• Dry and wrinkled skin
• Alert but irritable
• Requires adequate amount of protein, fat and carbohydrate
Marasmus

A 3-year-old boy known case of coeliac disease, presented to the clinic with frontal bossing, bowlegs and harrison sulcus. He missed the follow up in the clinic for the last 6 month.

Which of the following can help in confirming the diagnosis?

**A. X-ray of the wrist joint shows cupping

B. Flaky-paint skin rash with hyperkeratosis

C. Ultrasound abdomen shows enlarger liver

D. Low plasma albumin, potassium and magnesium

A 3-year-old boy with coeliac disease presents to the clinic with frontal bossing, bowlegs and harrison sulcus. He missed the follow up in the clinic for the last 6 month.

Which of the following is the best management?

**A. Daily administration of Vitamin D3

B. Daily administration of Vitamin A

C. Daily administration of Vitamin B12

D. Daily administration of Vitamin C

A 3-year-old boy presents to the clinic with marked obesity. The mother gave history of persistent hyperphagia, and that he does not control his hunger. On examination, he is found to have dysmorphic facial features, hypotonia and undescended testes.

Which of the following is most likely diagnosis?

A. Noonan syndrome

B. Williams syndrome

C. DiGeorge syndrome

**D. Prader-Willi Syndrome

Prader-Willi syndrome	Presents with hypotonia, hyperphagia, obesity, hypogonadism, almond-shaped eyes, ↓ cognition Causes sleep apnea, DM type 2, gastric distention and rupture, and obesity-related complications	Deletion of paternal 15q11-q13 (imprinting disorder) Paternal deletion → Prader-Willi Most common syndromic form of obesity

Which of the following considered a complication of obesity in childhood?

A. Primary enuresis

**B. Hypertension

C. Type 1 diabetes

D. Hyperventilation syndrome

LES
inappropriate relaxation
GERD

A 6-month-old infant presents to the Emergency Room with sudden apnea and color change. The mother gave history of recurrent vomiting and multiple chest infection. On examination, wasted and underweight infant, with failure to thrive and dystonic neck posturing while crying.

Which of the following contribute to the disease?

A. Hypertrophy of the pyloric muscles

B. Hypertrophy of the esophageal muscles

C. Inappropriate relaxation of the upper esophageal sphincter

**D. Inappropriate relaxation of the lower esophageal sphincter

A 6-month-old infant presents to the Emergency Room with sudden apnea and color change. The mother gave history of recurrent vomiting, and multiple chest infection. On examination, he looks failing to thrive with dystonic neck posturing while crying.

Which of the following considers as high-risk case for the above disease?

A. Obese baby

**B. Preterm infant

C. Post pertussis infection

D. Following inguinal hernia repair

GERD
LES

A 6-month-old infant presents to the Emergency Room with sudden apnea and color change. The mother gave history of recurrent vomiting, and multiple chest infection. On examination, he looks failing to thrive with dystonic neck posturing while crying.

Which of the following is the most likely diagnosis?

A. Pyloric stenosis

B. Cow's milk allergy

C. Whooping cough

**D. Gastroesophageal reflux

A 3-week-old neonate presents to the Emergency Room with persistent projectile vomiting. The mother mentioned that he is immediately show sign of hunger after vomiting, but he is not gaining weight as expected.

Which of the following finding associated with this presentation?

**A. Hypochloraemic metabolic alkalosis

B. Hyperchloraemic metabolic acidosis

C. Hypochloraemic metabolic acidosis

D. Hyperchloraemic metabolic alkalosis

A 4-week-old neonate presents to the Emergency Room with persistent projectile vomiting. The mother mentioned that he is immediately show sign of hunger after vomiting, but he is not gaining weight as expected (see lab results).

Test Result Normal Values
Sodium 130 134-146 mmol/L
Potassium 2.8 3.5-5.1 mmol/L
Chloride 88 97-108 mmol/L
Bicarbonate 26 21-28 mmol/L

Which of the following is the most likely diagnosis?

A. Intussusception

**B. Pyloric stenosis

C. Intestinal obstruction

D. Gastroesophageal reflux

Vomiting
Infants age
UTI

Which of the following common cause of vomiting in infants' age group?

A. Coeliac disease

B. Diabetic ketoacidosis

**C. Urinary tract infection

D. Cyclical vomiting syndrome

What is the most appropriate counseling should be given regarding infantile colic?

A. It occurs in 80% of babies

B. Usually resolve by 6 weeks of age

**C. Associated with excessive passage of flatus

D. Gripe water has proven evidence to control it

A 5-year-old girl presents to the Emergency Room with history of severe abdominal pain, which is central and colicky, and repeated vomiting. The pain is getting worse by movement. On examination, there is generalized guarding in the abdomen, with more tenderness toward the right iliac fossa (see lab results).

Blood pressure 110/70 mmHg
Heart rate 135 /min
Respiratory rate 22 /min
Temperature 38 °C
Oxygen saturation 95 %

Test Result Normal Values

RBC 5 4.8-7.1 x 1012/L (Newborn)
4.6-4.8 x 1012/L (Child)
Hb 132 165-195 g/L (Newborn)
112-165 g/L (Child)
Platelets count 320 150-400 x 109/L
ESR 12 2-10 mm/h
WBC 15.2 4.5-13.5 x 109/L (2-10 years)
4.5-11.1 x 109/L (11 years-older adult)

Which of the following is the most appropriate counseling regarding this condition?

A. Occurs in 2% of individual

**B. Its uncommon below 3 years old

C. A sausage shaped mass often palpable

D. Passage of redcurrant jelly stool confirmed the diagnosis

Which of the following is the most appropriate counseling for coeliac disease?

A. No diagnostic test is available for coeliac disease

**B. Intestinal biopsy is required to confirm the diagnosis

C. Diagnosis can be confirmed by positive serological test

D. Improvement after usage of gluten-free diet can work as diagnostic test

A 14-month-old child presents to the Emergency Room with history of paroxysmal, sever colicky abdominal pain, which comes and goes in bouts. He had vomiting and suddenly pass red currant jelly stool.

Which of the following is the most appropriate counseling for this presentation?

**A. Shock is a common complication

B. Recurrence is common after surgical correction

C. Treatment requires immediate surgical intervention

D. Reduction by therapeutic enemas is carried out in case of peritonitis

Which of the following is the most common congenital heart lesion?

A. Persistent ductus arteriosus

**B. Ventricular septal defect

C. Atrial septal defect

D. Tetralogy of fallot

A 24-hour-old neonate found to have abnormal heart rhythm during admission exam. ECG done showed complete heart block. ECHO showed small persistent ductus arteriosus (see lab results).

Test Result Normal Values
RBC 5 4.8-7.1 x 1012/L (Newborn)
4.6-4.8 x 1012/L (Child)
Hb 165 165-195 g/L (Newborn)
112-165 g/L (Child)
HCT 0.45 0.44-0.64 (Newborn)
0.32-0.42 (Child)
Platelets count 65 150-400 x 109/L
WBC 11 9.1-30.1 x 109/L (Birth)
6.1-17.5 x 109/L (1-23 months)

Which of the following maternal disorders contributes to the finding?

A. Hypothyrodism

B. Diabetes mellitus

C. Rubella infection

**D. Systemic lupus erythematosus

No Referral
Murmur

A 2-year-old child presents to the Emergency Department with high-grade fever, persistent vomiting, diarrhea and cough for 3 days. On examination, a murmur with decrease air entry over the right lung. For the last 4 visit to the pediatrician, the patient had a normal exam including cardiac (see lab results).

Blood pressure 110/70 mmHg
Heart rate 125 /min
Respiratory rate 22 /min
Temperature 38.5 °C
Oxygen saturation 97 %

Test Result Normal Values
RBC 4.5 4.8-7.1 x 1012/L (Newborn)
4.6-4.8 x 1012/L (Child)
Hb 95 165-195 g/L (Newborn)
112-165 g/L (Child)
MCH 20 28-33 pg/cell
MCV 65 80-95 fl
Platelets count 200 150-400 x 109/L
WBC 6 4.5-13.5 x 109/L (2-10 years)
4.5-11.1 x 109/L (11 years-older adult)

Which of the following is the best next step in management for the heart murmur?

A. Urgent referral to cardiology

B. Immediate ECHO and ECG

C. Admission in cardiac ICU for monitoring and intervention

**D. Re-examine the heart murmur after correction of the underlying illness

A 2-year-old child presents to the Emergency Department with high-grade fever, persistent vomiting, diarrhea and cough for 3 days. On examination, a murmur with decrease air entry over the right lung. For the last 4 visit to the pediatrician, the patient had a normal exam including cardiac (see lab results).

Blood pressure 110/70 mmHg
Heart rate 110 /min
Respiratory rate 22 /min
Temperature 38.5 °C
Oxygen saturation 97 %

Test Result Normal Values
RBC 4.2 4.8-7.1 x 1012/L (Newborn)
4.6-4.8 x 1012/L (Child)
Hb 92 165-195 g/L (Newborn)
112-165 g/L (Child)
MCH 20 28-33 pg/cell
MCV 65 80-95 fl
Platelets count 350 150-400 x 109/L

Which of the following is the most likely diagnosis for the heart murmur?

A. Aortic stenosis

**B. Innocent murmur

C. Pulmonary regurgitation

D. Ventricular septal defect

An 8-week-old infant presents to the clinic with wheezing, coughing, poor feeding and poor weight gain for the previous 2 weeks. Before this, she had been well. Her routine neonatal examination had been normal apart from pansystolic murmur at lower left sternal edge. On examination, the liver was enlarged below costal margin.

Blood pressure 110/50 mmHg
Heart rate 95 /min
Respiratory rate 32 /min
Temperature 36.6 °C
Oxygen saturation 92 %

Which of the following is the most likely diagnosis?

A. Cystic fibrosis

B. Bronchial asthma

C. Atrial septal defect

**D. Ventricular septal defect

No Referral
VSD

An 8-week-old infant presents to the clinic with fever, wheezing, coughing, poor feeding and poor weight gain for the previous 2 weeks. Before this, she had been well. Her routine neonatal examination had been normal apart from pansystolic murmur at lower left sternal edge. On

examination, the liver was enlarged below costal margin (see report).

Blood pressure 95/50 mmHg
Heart rate 85 /min
Respiratory rate 34 /min
Temperature 38 °C
Oxygen saturation 92 %

Chest X-Ray:
Showed cardiomegaly and increase pulmonary vascular marking with bilateral patches in the lung.

Which of the following is the most appropriate next step in management?

A. Referral for surgical intervention

**B. Medical treatment with diuretics

C. Admit to ICU for diagnostic catheterization

D. Full course of IV antibiotics then re-evaluate

Which of the following represent the best management approach for significant atrial septal defect (ASD)?

A. Secundum ASD require surgical correction

**B. Treatment usually undertaken at 3-5 years of age

C. Treatment usually undertaken within 8 weeks form birth

D. No need to treat significant ASD as it will close by age of 5 years

An 18-month-old child diagnosed with congenital heart disease, presented to Emergency Room with severe cyanosis and hypercyanotic spells. The mother mentioned that he was irritable and inconsolable crying for the last 1 hours and the cyanosis is getting worse. On examination, he looks cyanotice centrally, with loud harsh ejection systolic murmur heard at left sternal border (see report).

Blood pressure 100/60 mmHg
Heart rate 95 /min
Respiratory rate 28 /min
Temperature 37.8 °C
Oxygen saturation 85 %

Chest X-Ray:
Showed small heart with decrease pulmonary vascular marking.

Which of the following is to most appropriate management?

**A. Sedation and pain relief

B. Intravenous diuretics bolus

C. Immediate cardiac catheterization

D. IV antibiotics and total parenteral nutrition

A 2-day-old neonate presents to the Emergency Department with sudden sever cyanosis. On examination, he looks cyanotic, lethargic; with cardiac exam reveals no murmur and normal pulses (see report).

Chest X-Ray:
Showed egg on side appearance of the cardiac shadow and increased pulmonary vascular marking.

Which of the following is the most likely diagnosis?

A. Tetralogy of fallot

B. Coarctation of aorta

**C. Transposition of great arteries

D. Persistence ductus arteriosus

A 14-month-old presents to Primary Clinic with recurrent syncopal attack, associated with worsening heart failure manifestation and poor growth. On examination, he has crackles all over the chest with palpitation and abnormal cardiac rhythm (see report).

ECG:
Showed narrow complex tachycardia of 250-300 beats/min.

Which of the following is the most likely diagnosis?

A. Atrial flutter

B. Atrial fibrillation

C. Ventricular tachycardia

**D. Supraventricular tachycardia

Cow milk
Sickle cell
Iron deficiency

A 2-year-old girl brought to Primary Clinic because the mother noticed she is pale. She had history of drinking 3 glasses of cow's milk daily, very picky eater and refusing to eat meat. The mother gave history of similar presentation on 2 of her brother (see lab results).

Test Result Normal Values
RBC 3 4.8-7.1 x 1012/L (Newborn)
4.6-4.8 x 1012/L (Child)
Hb 4 165-195 g/L (Newborn)
112-165 g/L (Child)
MCH 18 28-33 pg/cell
MCV 62 80-95 fl
Reticulocyte 3 0.2-1.2 %
Platelets count 480 150-400 x 109/L
Ferritin 9 20-200 µg/L

Which of the following is the most likely diagnosis?

**A. Sickle cell disease

B. Alpha thalassemia trait

C. Iron deficiency anemia

D. Anemia of chronic disease

↑ risk of IRON DEF. ANEMIA
COW MILK → DO NOT GIVE BEFORE 1 yr of AGE.

A 2-year-old girl brought to Primary Clinic because the mother noticed she is pale. History of drinking 3 pints of cow's milk daily and is a very picky eater. The mother gave history of similar presentation on 2 of her brother (see lab results).

Test Result Normal Values
RBC 3 4.8-7.1 x 1012/L (Newborn)
4.6-4.8 x 1012/L (Child)
Hb 4 165-195 g/L (Newborn)
112-165 g/L (Child)
MCH 18 28-33 pg/cell
MCV 62 80-95 fl
Reticulocyte 3 0.2-1.2 %
Platelets count 480 150-400 x 109/L
Ferritin 9 20-200 µg/L

Which of the following is the most likely diagnosis?

A. Sickle cell disease

B. Alpha thalassemia trait

**C. Iron deficiency anemia

D. Anemia of chronic disease

A 2-years-old boy presents to the clinic with complain of sudden jaundice, fever for the last 3 days and passage of dark urine. Family history is positive for one brother who has severe neonatal jaundice required exchange transfusion, and they are originated from Mediterranean region (see lab results).

Blood pressure 110/70 mmHg
Heart rate 120 /min
Respiratory rate 22 /min
Temperature 38.5 °C

Test Result Normal Values
RBC 4 4.8-7.1 x 1012/L (Newborn)
4.6-4.8 x 1012/L (Child)
Hb 9 165-195 g/L (Newborn)
112-165 g/L (Child)
Reticulocyte 3 0.2-1.2 %
Platelets count 300 150-400 x 109/L
WBC 10 4.5-13.5 x 109/L (2-10 years)
4.5-11.1 x 109/L (11 years-older adult)

Which of the following medications should be avoided in the management?

**A. Aspirin

B. Amoxicillin

C. Ibuprofen

D. Acetaminophen

ALL

Which of the following leukemia is the most common in pediatric age group?

A. Acute myeloid

B. Chronic myeloid

**C. Acute lymphoblastic

D. Acute non-lymphoblastic

A 3-year-old boy is brought to the clinic by his mother because he was not eating well, and had distended abdomen. Recently he appeared reluctant to walk and lost weight. On examination, he looks pale, with hypertension and distended abdomen. MRI abdomen, confirmed the presence of large upper abdominal mass extending toward the midline.

Which of the following is the most likely diagnosis?

A. Wilms tumor

**B. Neuroblastoma

C. Hodgkin lymphoma

D. Non-Hodgkin lymphoma

A 4-year-old girl presents to the clinic with recurrent abdominal pain in addition to headaches. She has poor appetite and refuse feeding because the pain. The attacks of the abdominal pain are midline associated with vomiting and facial pallor. There is a family history of severe headache in 2 sisters.

Which of the following is the most likely diagnosis?

**A. Abdominal migraine

B. Chronic constipation

C. Irritable bowel syndrome

D. Inflammatory bowel disease

A 2-year-old girl presents to the Emergency Room with fever, vomiting and diarrhea for the last 4 days. On examination, she looks severely dehydrated, lethargic with altered conscious stat, with mild abdominal pain. The family mentioned that they tried to use oral rehydration solution at home but she is not drinking well. A rapid correction by intravenous normal saline fluid established to manage her case. After 30 minutes, she starts to have abnormal movement and went in coma, which required resuscitation intubation and admission to Pediatric Critical Care Unit (see lab results).

Blood pressure 75/35 mmHg

Heart rate 110 /min
Respiratory rate 28 /min
Temperature 39 °C
Oxygen saturation 95 %

Test Result Normal Values
Sodium 162 134-146 mmol/L
Potassium 3.8 3.5-5.1 mmol/L
Chloride 115 97-108 mmol/L
Bicarbonate 14 21-28 mmol/L

Which of the following is the most likely cause her deterioration?

A. The case complicated with meningitis

**B. Rapid correction lead to cerebral edema

C. Delayed in starting fluid and antibiotics

D. Sudden intraventricular hemorrhage because the high sodium

A 2-year-old child presents to the Emergency Room with fever, vomiting and diarrhea for the last 4 days. On examination, she looks severely dehydrated, lethargic with altered conscious stat, with mild abdominal pain. The family mentioned that they tried to use oral rehydration solution at home but she is not drinking well. A rapid correction by intravenous normal saline fluid established to manage her case. After 30 minutes, she starts to have abnormal movement and went in coma, which required resuscitation intubation and admission to Pediatric Critical Care Unit (see lab results).

Blood pressure 75/45 mmHg
Heart rate 120 /min
Respiratory rate 28 /min
Temperature 39 °C
Oxygen saturation 95 %

Adult dosages

- Asymptomatic. NaCl 3% 50 ml IV bolus over 5 minutes.
- Symptomatic. NaCl 3% 100 ml IV over 10 minutes. May repeat up to 3 doses over 30 minutes.

In patients with severe hyponatremia, serum sodium should undergo correction by 4 to 6 mEq/L per day, which can be achieved with 100 mL boluses of 3% HS at 10-minute intervals up to three total boluses.

Test Result Normal Values
Sodium 162 134-146 mmol/L
Potassium 3.6 3.5-5.1 mmol/L
Chloride 115 97-108 mmol/L
Bicarbonate 14 21-28 mmol/L

Central pontine myelinolysis (CPM), also known as osmotic demyelination syndrome, is a neurological disorder that most frequently occurs after too rapid medical correction of sodium deficiency (hyponatremia).

Which of the following is the most appropriate management?

**A. Fluid deficit should be replaced over 48 hours

B. Fluid deficit should be replaced over 24 hours

C. Fluid deficit should be replaced over 12 hours

D. Fluid deficit should be replaced over 6 hours

Which of the following describes the role of anti-diarrheal drugs in the management of gastroenteritis?

A. They are effective

**B. Can be associated with side effects

C. Can replace oral rehydration in severe cases

D. May shorten the excretion of bacteria in stool

A 12-month-old child presents to the clinic following an episode of gastroenteritis as diarrhea returns back after introduction of normal diet. The mother said that she used the oral rehydration solution as prescribed and followed the advices received from the pediatrician. On examination, the child looks mildly dehydrated with normal activity.

Which of the following is the most appropriate counseling should be given?

A. Change to gluten free formula

B. Change to cow's milk free formula

C. Use oral rehydration solution for 5 days followed by introduction of normal diet

**D. Use oral rehydration solution for 24 hours followed by introduction of normal diet

A 12-month-old child presents to the clinic following an episode of gastroenteritis as diarrhea returns back after introduction of normal diet. The mother said that she used the oral rehydration solution as prescribed and followed the advices received from the pediatrician. On examination, the child looks mildly dehydrated with normal activity.

Which of the following can explain the new presentation?

**A. Temporary lactose intolerance

B. Temporary lactase intolerance

C. Temporary glucose intolerance

D. Temporary sucrose intolerance

Vaccine

An 18-month-old child presents to the clinic with unilateral eye swilling for 2 days. On examination, there is clear proptosis, painful and limited ocular movement with reduce visual acuity. The mother said they missed 12 and 18 months vaccines.

Which of the following is the most appropriate next step in management?

A. Arrange for 18 month vaccines administration

B. Brain MRI to roll out intraventricular hemorrhage

**C. Urgent CT scan to assess the spread of the infection

D. Perform funduscopic exam to roll out inclusion body

An 18-month-old child presents to the clinic with unilateral eye swilling for 2 days. On examination, there is clear proptosis, painful and limited ocular movement with reduce visual acuity. The mother said they missed 12 and 18 months vaccines.

Which of the following is the most likely diagnosis?

A. Orbital myositis

**B. Orbital cellulitis

C. Periorbital cellulitis

D. Thyroid-associated orbitopathy

Impetigo

Local infection of the epidermis that primarily occurs in children and is caused by both group A streptococcal and staphylococcal organisms. It is highly contagious and transmitted by direct contact.

A 2-year-old child presents to the clinic with skin lesions on the face, neck and hands. The mother said it was started as erythematous macules, which became vesicular then ruptured. On examination, ruptured vesicles with exudation that look like honey colored crust lesions. The mother mentioned that her child complain of atopic eczema since infancy.

Which of the following is the most likely diagnosis?

A. Boils

**B. Impetigo

C. Atopic dermatitis

D. Scalded skin syndrome

FIGURE 2.2-21. **Impetigo.** Dried pustules with a superficial golden-brown crust are most commonly found around the nose and mouth. (Reproduced with permission from

IMPETIGO

A 2-year-old child presents to the clinic with skin lesions on the face, neck and hands. The mother said it was started as erythematous macules, which became vesicular then ruptured. On examination, ruptured vesicles with exudation that look like honey colored crust lesions. The mother mentioned that her child complain of atopic eczema since infancy. The mother is asking if she can allow her child to return to the nursery.

Which of the following is the most appropriate counseling should be given?

A. Lesions are not contagious and can go to nursery

B. Lesions are not contagious and can go to nursery after 5 days

C. Lesions are contagious and should not go to nursery for 3 days

**D. Lesions are contagious and should not go to nursery until it become dry

or 24 hour after initiation of ANTIBIOTICS

A 2-year-old child presents to the clinic with 3-day history of vesicular lesions on the lips, gums and anterior surface of the tongue and hard palate. On examination, child looks dehydrated with dry mucus membrane the lesions look extensive, painful with mild bleeding. According to the mother, she is not eating or drinking well because of the pain.

Which of the following is the most likely diagnosis?

A. Impetigo

**B. Gingivostomatitis

C. Herpetic whitlows

D. Eczema herpeticum

A 2-year-old child presents to the clinic with 3-day history of vesicular lesions on the lips, gums

and anterior surface of the tongue and hard palate. On examination, the lesions look extensive, painful with mild bleeding. According to the mother, she is not eating or drinking well because of the pain.

Which of the following is the most likely the causative organism?

**A. Herpes simplex virus

B. Varicella zoster virus

C. Staphylococcal aureus

D. Streptococcus pneumoniae

- **Recurrent oral herpes (HSV-1):** The common "cold sore," or herpes labialis, which presents as a cluster of crusted vesicles on an erythematous base (Fig. 2.2-16A). Often triggered by stress, sunlight, or infections.
- **Recurrent genital herpes (HSV-2):** Unilateral and characterized by a cluster of ulcers on an erythematous base, but with less pain and systemic involvement than the primary infection.

Trigeminal Ganglia
Sacral Ganglia

HHV-1 } Herpes Simplex V — Oral lesion / Genital lesion
HHV-2 }
HHV-3 → VZV → Chicken pox, Shingles (reactv.)
HHV-4 → EBV → Infectious Mononucleosis
HHV-5 → CMV

V2V → AIRBORNE Transmission

A 2-year-old child presents to the clinic with 3-day history of vesicular lesions on the lips, gums and anterior surface of the tongue and hard palate. On examination, child looks dehydrated and the lesions look extensive, painful with mild bleeding. According to the mother, she is not eating or drinking well because of the pain for the last 2 days.

Which of the following is the best management?

A. Acyclovir

**B. Intravenous fluid and acyclovir

C. Intravenous fluid and topical antibiotics

D. Narrow spectrum systemic antibiotics and topical antibiotics

A 2-year-old child presented to the clinic with high-fever of 5-day duration. Examination showed ill child with mild conjunctivitis, a rash, cervical lymphadenopathy, and cracked red lips (see lab results).

Blood pressure 110/70 mmHg
Heart rate 115 /min
Respiratory rate 22 /min
Temperature 39.5 °C

Test Result Normal Values
C-reactive peptide 135 0-0.5 mg/dl
RBC 4 4.8-7.1 x 1012/L (Newborn)
4.6-4.8 x 1012/L (Child)
Hb 115 165-195 g/L (Newborn)
112-165 g/L (Child)
Platelets count 550 150-400 x 109/L
ESR 125 2-10 mm/h
WBC 15 4.5-13.5 x 109/L (2-10 years)
4.5-11.1 x 109/L (11 years-older adult)

Which of the following is the best management?

**A. Aspirin

B. Ribavirin

C. Vitamin A

D. Acyclovir

Kawasaki Disease

A 2-year-old child presented to the clinic with high-fever of 5-day duration. Examination showed ill child, with mild conjunctivitis, a rash, cervical lymphadenopathy and cracked red lips (see lab results).

Blood pressure 110/70 mmHg
Heart rate 120 /min
Respiratory rate 24 /min
Temperature 39.2 °C

Test Result Normal Values
RBC 5 4.8-7.1 x 1012/L (Newborn)
4.6-4.8 x 1012/L (Child)
Hb 115 165-195 g/L (Newborn)
112-165 g/L (Child)
Platelets count 550 150-400 x 109/L
ESR 125 2-10 mm/h
WBC 18 4.5-13.5 x 109/L (2-10 years)
4.5-11.1 x 109/L (11 years-older adult)
C-reactive peptide 135 0-0.5 mg/dl

An acute multisystem medium-vessel vasculitis that primarily affects young children. Usually affects children age <5 years (↑ incidence in people of Japanese and Korean descent). Kawasaki disease is divided into acute, subacute, and convalescent phases.

History/PE

Five days of fever and at least four of the following five criteria:

1. Conjunctivitis: Bilateral, nonexudative, painless with limbal sparing (acute phase)
2. Oral mucosal changes: Erythematous mouth/pharynx, "strawberry tongue," and/or cracked lips (acute phase)
3. Rash: Primarily truncal, polymorphous, erythematous (acute phase)
4. Peripheral extremity changes: Edema of hands and feet, palmar erythema (acute phase), and desquamating palms and soles (convalescent phase)
5. Cervical lymphadenopathy (>1.5 cm): Generally painful and unilateral (acute phase)

Complications: Untreated children may develop coronary artery aneurysms (25%); all patients should be assessed by echocardiography at diagnosis.

Which of the following is the most likely diagnosis?

A. Mumps

B. Rubella

C. Measles

**D. Kawasaki disease

Treatment

- Best **initial treatment**: High-dose aspirin (acetylsalicylic acid [ASA]), for anti-inflammatory, antipyretic, and antithrombotic effects and IVIG to reduce the risk of coronary artery aneurysms from 25% to <5%.

A 5-year-old child presents to the Emergency Room with severe sore throat, high-fever and increasing difficulty breathing over 8 hours. On examination, ill toxic looking child with drooling of saliva and sitting immobile with open mouth.

6th June DHA

Blood pressure 110/70 mmHg
Heart rate 115 /min
Respiratory rate 32 /min
Temperature 38.8 °C
Oxygen saturation 95 %

EPIGLOTTITIS
3–7 years
Epiglottis Aryepiglottic folds
H influenzae type B, S pneumoniae
Rapid (4–12 hours)
High grade
Respiratory distress: Acute decompensation, toxic appearance, inspiratory stridor, muffled voice, drooling, tripoding
None
"Thumbprint sign" on lateral film

Which of the following is the most appropriate immediate action should be taken?

A. Urgent referral to ENT for tonsillectomy

B. Complete sepsis work up, followed by antibiotics for 7 days

C. Send home on oral antibiotics for 7 days and referral to ENT

**D. Urgent admission to ICU for intubation then sepsis work to follow

Epiglottitis
Antibiotic

A 5-year-old child presents with severe sore throat, high fever and increasing difficulty breathing over 8 hours. On examination, ill and toxic looking child with drooling of saliva and sitting immobile with open mouth.

Blood pressure 110/70 mmHg
Heart rate 120 /min
Respiratory rate 28 /min
Temperature 38.6 °C
Oxygen saturation 95 %

Which of the following is the most likely diagnosis?

A. Bronchitis

B. Pharyngitis

C. Acute Croup

**D. Acute epiglottitis

EPIGLOTTITIS

A serious and rapidly progressive infection of supraglottic structures (eg, the epiglottis and aryepiglottic folds). Before immunization, *H influenzae* type b was the primary pathogen. Common causes now include *Streptococcus* species, nontypeable *H influenzae*, and viral agents, but this is now a very rare infection in the postvaccine era.

History/PE

- Epiglottitis presents with acute-onset high fever (39–40°C [102–104°F]), dysphagia, drooling, a muffled voice, inspiratory retractions, cyanosis, and soft stridor.
- Patients sit with the neck hyperextended and the chin protruding ("sniffing dog" position) and lean forward in a "tripod" position to maximize air entry.
- Untreated infection can rapidly lead to life-threatening airway obstruction and respiratory arrest.

Diagnosis

- Epiglottitis is diagnosed by clinical impression. The differential diagnosis must include diffuse and localized causes of airway obstruction (see Table 2.12-21).
- The airway must be secured before a definitive diagnosis can be made. In light of potential laryngospasm and airway compromise, an examination of the throat should only be done in the presence of an anesthesiologist or otolaryngologist.
- Definitive diagnosis is made via direct fiberoptic visualization of cherry-red, swollen epiglottis and arytenoids.
- Lateral x-ray shows a swollen epiglottis obliterating the valleculae ("thumbprint sign"; see Fig. 2.12-20).

Treatment

Remember the ABCs. Secure the airway first with endotracheal intubation or tracheostomy and then give IV antibiotics (ceftriaxone or cefuroxime).

Jones

Which of the following considered as minor manifestation of Jones criteria for diagnosis of rheumatic fever?

A. Pancarditis

**B. Polyarthralgia

C. Sydenham chorea

D. Subcutaneous nodules

Major criteria	Minor criteria
• Migratory polyarthritis	• Fever
• Carditis (myocarditis, pericarditis)	• Arthralgias
• Erythema marginatum	• Elevated ESR/CRP
• Subcutaneous nodules	• Prolonged PR internal
• Chorea	• Heart block on EKG

A 3-year-old child presents to the clinic with history of passing red-brown urine. There is a positive history of flu-like prodrome 2 weeks ago.

Which of the following has the highest diagnostic value?

A. High complement C3

B. Low complement C4

C. High complement C4

**D. Low complement C3

A 4-month-old boy brought by his mother asking for circumcision. History revealed that he was diagnosed with mid-shaft hypospadias.

Which of the following is the most appropriate counseling should be given?

A. No link between hypospadias and circumcision

B. It is late for circumcision as correction is often undertaken before 4 month old

**C. Infant with hypospadias must not be circumcised as the skin will used in the surgery

D. Proceed with circumcision as there is no need for surgical correction for this type of

hypospadias

A 5-year-old child presented with bruising and skin rash that developed over 24 hours. She had had upper respiratory tract infection a week ago. On examination, she appeared well but had purpuric skin rash with some bruises on legs. No lymphadenopathy or hepatosplenomegaly (see lab results).

Test Result Normal Values
RBC 4.7 4.8-7.1 x 1012/L (Newborn)
4.6-4.8 x 1012/L (Child)
Hb 115 165-195 g/L (Newborn)
112-165 g/L (Child)
MCH 30 28-33 pg/cell
MCV 85 80-95 fl
Platelets count 17 150-400 x 109/L
ESR 3 2-10 mm/h
Clotting time 5 5-10 min
Bleeding time 3 up to 4 min
APTT 35 30-40 sec
INR 1.1 0.9-1.2
Prothrombin time 13 12-14 sec
WBC 6 4.5-13.5 x 109/L (2-10 years)
4.5-11.1 x 109/L (11 years-older adult)
Color clear clear or light yellow
Nitrite absent Absent
Hemoglobin absent Absent
Erythrocytes 0 0-2 per high power field

Which of the following is most likely the diagnosis?

A. Wiskott-aldrich syndrome

B. Bernard-soulier syndrome

**C. Immune thrombocytopenic purpura

D. Thrombotic thrombocytopenic purpura

A 2-month-old infant presents to Emergency Room with bronchiolitis required non-invasive mechanical ventilation as a respiratory support.

Which of the following is the most appropriate destination?

A. Admission to paediatric word

B. Admission to neonatal care unit

C. Observation in emergency department

**D. Admission to paediatrics critical care unit

An 8-month-old infant admitted to Paediatrics Critical Care for close observation.

Which of the following standers continuous monitoring in paediatrics critical care measured as trans-cutaneous?

A. Blood pressure

B. Fluid balance

C. Glasgow coma scale

**D. Arterial oxygen saturation

A 7-year-old presents to Emergency Department with vomiting and abdominal pain for 1 day. The child has had history of polydipsia, polyuria and weight loss for the last 3 weeks. Examination reveals dehydration and hypoactivity (see lab results).

Blood pressure 90/50 mmHg
Heart rate 110 /min
Respiratory rate 24 /min
Temperature 38.6 °C
Oxygen saturation 95 %
Weight 23 kg

Test Result Normal Values
ABG HCO3- 5 13-22 mmol/L
ABG PCO2 22 27-40 mmHg
pH 7.12 7.36-7.45
ABG PO2 100 8-24 mmHg (Newborn)
55-80 mmHg (Child)
Base access -17 -2 to 2 mmol/L
Color light yellow clear or light yellow
Appearance clear clear
pH 6 4.3-8
Specific gravity 1025 1001-1030
Protein +1 Absent
Glucose +4 Absent
Ketones +4 Absent
Nitrite absent Absent
Leukocytes 3 0-3 per high power field

Which of the following is the most likely diagnosis?

A. Gastritis

B. Food poisoning

**C. Diabetic ketoacidosis

D. Urinary tract infection

A 3-year-old child presents to Emergency Department with fever, poor feeding and vomiting for 3 days after a flu-like illness. On examination, she looks sick, lethargic and capillary refill is 4 seconds. Cardiopulmonary monitor attached and intravenous access attained.

Blood pressure 62/46 mmHg
Heart rate 156 /min
Respiratory rate 48 /min
Temperature 38.2 °C
Oxygen saturation 92 %

Which of the following is the most likely diagnosis?

A. Sepsis

B. Bronchiolitis

C. Encephilitis

**D. Septic shock

Steroid

A 4-year-old child presents with shortness of breath and cough following flu-like illness for 2 days. Examination reveals child in severe distress with increased effort of respiration with bilateral wheeze and prolonged expiatory phase. He had slimier attacks before that required hospitalization.

Blood pressure 100/65 mmHg
Heart rate 124 /min
Respiratory rate 33 /min
Temperature 36.6 °C
Oxygen saturation 82 %

Which of the following is the most appropriate management?

A. Antibiotic and systematic steroid

B. Ventolin nebulization and antibiotics

C. Intravenous fluid and ventolin nebulization

**D. Ventolin nebulization and systematic steroid

Seizure
Status Epilepticus
Lorazepam
Diazepam

A 9-month-old infant presents to Emergency Room with active generalized tonic-clonic seizure for 5 minutes ago. He has flu-like illness today and the review of system was unremarkable. The child was connected to cardiopulmonary monitor and intravenous access immediately attained.

Blood pressure 80/50 mmHg
Heart rate 132 /min
Respiratory rate 31 /min
Temperature 39.6 °C
Oxygen saturation 95 %

STATUS EPILEPTICUS

A **medical emergency** consisting of prolonged seizures (usually >5 minutes) or two or more seizures that occur without a return to baseline consciousness within 30 minutes or continuous clinical and/or electrographic seizure activity

- Common causes include anticonvulsant withdrawal/noncompliance, anoxic brain injury, EtOH/sedative withdrawal or other drug intoxication, and metabolic disturbances (eg, hyponatremia), head trauma, and infection.
- Mortality is 10% to 20%.

Which of the following is the most appropriate next step in management?

A. Oral lorazepam

B. Nasal diazepam

C. Rectal diazepam

**D. Intravenous lorazepam

- **Best initial therapy:** Benzodiazepines are given intravascularly: IV lorazepam or IV diazepam. These steps (from ABCs to IV benzodiazepines) are carried out between 5 and 20 minutes of resuscitation:
  - This is given if the seizure persists after 5 minutes (ie, the stabilization phase) or recurs when the patient is being treated.
  - Alternatives include phenobarbital, rectal diazepam for children, and intranasal midazolam.
- **Next step in management:** If seizure persists despite these treatments, the physician should consider IV fosphenytoin, IV valproic acid, or IV levetiracetam.
- Last-resort options include repetition of second-line drugs or induction of coma by use of general anesthetics (eg, propofol).

Which of the following is the most common cause of shock in children?

A. Septic

**B. Hypovolemic

C. Cardiogenic

D. Obstructive

An 18-month-old child with cerebral palsy admitted to Paediatrics Intensive Care Unit for respiratory support following event of vomiting and cyanosis. She is connected to mechanical ventilator with FIO2 of 100% (see image and lab results).

Blood pressure 100/70 mmHg
Heart rate 120 /min
Respiratory rate 18 /min
Temperature 36.6 °C
Oxygen saturation 95 %
etCO2 35 mmHg

Test Result Normal Values
ABG HCO3- 21 13-22 mmol/L
ABG PCO2 35 27-40 mmHg
pH 7.37 7.36-7.45
ABG PO2 43 8-24 mmHg (Newborn)
55-80 mmHg (Child)
Base access 2 -2 to 2 mmol/L

Which of the following is the most likely diagnosis?

**A. Hypoxic respiratory failure

B. Hypocapnic respiratory failure

C. Neurogenic respiratory failure

D. Hypercapnic respiratory failure

A 12-year-old child brought by an ambulance to Emergency Room after fall down from height. The primary survey reveals awake child, breathing with open wound in left thigh covered with blood-sucked gauze. The capillary refill is 4 seconds.

Blood pressure 70/50 mmHg
Heart rate 118 /min
Respiratory rate 22 /min
Temperature 36.6 °C
Oxygen saturation 95 %

Which of the following is the most appropriate next action?

A. Send for imaging

B. Give morphine bolus

C. Call surgeon on duty

**D. Give normal saline bolus

A 6-year-old boy presented with recurrent cough and wheeze. He is on ventolin and fluxotide inhaler, labelled as bronchial asthma sine age of 4. The mother is concerned about poor weight gain and worsening lung condition. His examination reveals thin child with weight less than 5th percentile and height at 25th percentile and has normal chest exam.

Blood pressure 110/70 mmHg
Heart rate 76 /min
Respiratory rate 18 /min
Temperature 36.6 °C
Oxygen saturation 95 %

Which of the following is the most appropriate counselling should be given?

A. Reassurance and dietitian referral

B. Need escalation in bronchial asthma control

C. Start antibiotics and follow up after one month

**D. Need further work out to roll out bronchial asthma mimicker

Respiratory distress syndrome is common disease encountered in newborn delivered prematurely.

Which of the following is the most basic lung part affected?

Neonatal ARDS
↓
Surfactant Deficiency

**A. Epithelial cell producing surfactant

B. Connective tissue protein

C. Alveolar space structure

D. Bronchial tissue enzyme

Which of the following is the most common chronic disease in children?

A. Renal failure

B. Cystic fibrosis

**C. Bronchial asthma

D. Diabetes mellitus

Which of the following is the most important elements in bronchial asthma management?

A. Control acute attacks

B. Annual influenza vaccination

C. Compliance with inhaled steroids

**D. Family education and awareness

A 3-year-old child with suspected bronchial asthma disease.

Which of the following has the highest diagnostic value at this age?

A. Brochoscopy and lung biopsy

B. Pulmonary function test and spirometry

C. Chest imaging and specific immunological blood test

**D. Detailed history and physical examination and response to brochodilation

A 10-year-old boy with recurrent wheeze and cough responded partially to asthma management. He has poor weight gain and strong family history of bronchial asthma.

Which of the following supports diagnosis of cystic fibrosis?

A. Partial response to brochodilation

B. Family history of bronchial asthma

C. Recurrent wheeze and cough

**D. Poor weight gain

An 18-month-old child presents with stridor and barking cough for 2 days after flu-like symptoms. Examination reveals active well looking child and stable vital signs.

Blood pressure 100/70 mmHg
Heart rate 102 /min
Respiratory rate 20 /min
Temperature 37.6 °C
Oxygen saturation 95 %

Which of the following is the most likely diagnosis?

**A. Viral croup

B. Epiglottis

C. Trachiaitis

D. Foreign body aspiration

A 2-month-old infant presents to Emergency Room with history of apnea. He is bottle fed with good weight gain. The mother gave history of breath cessation and cyanosis 10 minutes after each bottle feed that aborted spontaneously. He has normal examination and growth parameter.

Blood pressure 80/50 mmHg
Heart rate 110 /min
Respiratory rate 22 /min
Temperature 36.6 °C
Oxygen saturation 95 %

Which of the following is most likely admission diagnosis?

**A. Acute life threatening event

B. Apnea to roll out sepsis

C. Infant with seizure

D. Syncopal attack

A 4-year-old child with bronchial asthma on ventolin inhaler. The mother gave history of cough attack more than twice per week and she brought her child to the Emergency Room last month twice.

Which of the following is the most appropriate next step in management?

**A. Start inhaled steroids

B. Increase ventolin frequency

C. Continue same management

D. Admit to hospital for further workup

Which of the following is the most causative organism of bronchiolitis in infant?

A. Influenza

B. Adenovirus

C. Parainflunza

**D. Respiratory syncytial virus

Which of the following is the most common mode of inheritance in cystic fibrosis?

**A. Autosomal recessive

B. Autosomal dominant

C. X-linked recessive

D. Multifactorial

A 2-year-old child presents with cough and fever for 1 week duration following flu-like symptoms. On examination, well looking with decease air entry and crackles in right lower lung on auscultation and just below this finding there is stony dullness on percussion.

Blood pressure 98/65 mmHg
Heart rate 105 /min
Respiratory rate 22 /min
Temperature 38.6 °C
Oxygen saturation 95 %

Which of the following is the expected finding in chest X-ray match child's chest finding?

A. Bronchopneumonia

**B. Plural effusion

C. Pneumothorax

D. Lung collapse

A 3-month-old infant with noisy breath since birth change with positioning tends to disappears in prone position and become more obvious with supine position. Examination and growth parameter are normal.

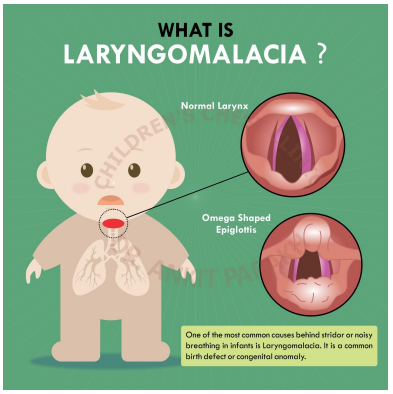
WHAT IS
LARYNGOMALACIA ?
Normal Larynx
Omega Shaped Epiglottis
One of the most common causes behind stridor or noisy breathing in infants is Laryngomalacia. It is a common birth defect or congenital anomaly.

Which of the following is the most likely diagnosis?

A. Nasal atresia

**B. Laryngomalacia

C. Subglottic stenosis

D. Vocal cord paralysis

A 3-month-old infant with noisy breath since birth change with positioning tends to disappears in prone position and become more obvious with supine position. Examination and growth parameter are normal. The mother concerned about this sound.

Which of the following is the most appropriate counselling should be given?

6th June DHA

A. Will worsen with time

B. Needs surgical correction

C. Normal developmental sounds

**D. Will improve by her first birthday

An 8-month-old infant with recurrent wheeze and distress resistance to asthma management and required multiple hospitalizations. After detailed history and examination, his paediatrician suspects tracheomalacia.



Which of the following has the highest diagnostic value?

A. Chest CT

B. Chest X-ray

C. Fluoroscopy

**D. Bronchoscopy

An 8-year-old boy being evaluated for short stature that includes detailed history and careful examination.

Which of the following is the most important bedside test of highest diagnostic value?

A. Dipstick urinalysis

B. Portable spirometry

C. Arm circumference

**D. Mid-parental target height

A 13-year-old girl screened for sport participation found to have delayed puberty and short stature. On examination, she was found to have webbed neck and wide shield-like chest.

Which of the following is the most likely diagnosis?

A. Noonan syndrome

**B. Turner syndrome

C. Growth hormone deficiency

D. Constitutional short stature

A 13-year-old girl screened for delayed puberty and short stature. On examination, she found to have webbed neck and wide shield-like chest.

Which of the following tests has the highest diagnostics value?

A. Pelvic ultrasound

B. Bone age imaging

C. Growth hormone level

**D. Chromosomal analysis

Cortisone

A 3-week-old boy infant presents to Emergency Room with history of vomiting and lethargy. He is hypoactive with mottled skin and no focus of infection. Perinatal history was unremarkable (see lab results).

- Blood pressure 50/30 mmHg
- Heart rate 180 /min
- Respiratory rate 56 /min

Temperature 36.6 °C
Oxygen saturation 95 %

Test Result Normal Values

- Sodium 122 134-146 mmol/L
- Potassium 6.2 3.5-5.1 mmol/L

Chloride 100 97-108 mmol/L
Bicarbonate 21 21-28 mmol/L
Calcium total 2.4 2.2-2.7 mmol/L
Calcium ionised 1.5 1.2-1.3 mmol/L

- Blood urea nitrogen 3 0.7-6.7 mmol/L (Newborn)
  1.8 to 6.4 mmol/L (Child)

Creatinine 44 27-88 µmol/L (Newborn)
27-62 µmol/L (Child)

- Glucose 1.2 2.8-5 mmol/L (Newborn)
  3.3 -5.5 mmol/L (Child)

Which of the following is the most likely definitive treatment?

A. Antibiotics

B. Fluid and dextose

C. Dextrose and intralipid

**D. Cortisone and hormonal therapy

A 9-year-old child presents to Emergency Department with hypovolemic shock. Parents gave history of recent brain surgery and the child has polyurea and increased thirst since then (see lab results). 6th June DHA

Blood pressure 70/40 mmHg
Heart rate 136 /min
Respiratory rate 18 /min
Temperature 36.6 °C
Oxygen saturation 95 %

Test Result Normal Values
ABG HCO3- 20 13-22 mmol/L
ABG PCO2 35 27-40 mmHg
pH 7.37 7.36-7.45
ABG PO2 88 8-24 mmHg (Newborn)
55-80 mmHg (Child)
Base access -6 -2 to 2 mmol/L
Sodium 177 134-146 mmol/L
Potassium 4 3.5-5.1 mmol/L
Chloride 140 97-108 mmol/L
Bicarbonate 20 21-28 mmol/L
Blood urea nitrogen 8 0.7-6.7 mmol/L (Newborn)
1.8 to 6.4 mmol/L (Child)
Creatinine 60 27-88 µmol/L (Newborn)
27-62 µmol/L (Child)
Glucose 4.5 2.8-5 mmol/L (Newborn)
3.3 -5.5 mmol/L (Child)
Color colorless clear or light yellow
Appearance Clear clear
Specific gravity 1003 1001-1030
Ketones absent Absent

Which of the following is the most likely diagnosis?

A. Diabetic ketoacidosis

**B. Diabetes insipidus

C. Renal tubelur acidosis

D. Syndrome of inappropriate antidiuretic hormone secretion

A 9-year-old child presents to Emergency Department with hypovolemic shock. Parents gave history of recent brain surgery and child has polyurea and increased thirst since then (see lab

results).

Blood pressure 70/50 mmHg
Heart rate 122 /min
Respiratory rate 18 /min
Temperature 36.6 °C
Oxygen saturation 95 %

Test Result Normal Values
ABG HCO3- 22 13-22 mmol/L
ABG PCO2 36 27-40 mmHg
pH 7.37 7.36-7.45
Sodium 167 134-146 mmol/L
Potassium 4.5 3.5-5.1 mmol/L
Chloride 122 97-108 mmol/L
Bicarbonate 22 21-28 mmol/L
Color colorless clear or light yellow
Appearance Clear clear
Specific gravity 1004 1001-1030
Ketones absent Absent

Which of the following is the most appropriate treatment?

**A. Desmopressin replacement

B. Insulin replacement regime

C. Free water replacement

D. Fluid and caloric control

What is the best time to start educating new mothers about breastfeeding?

A. After delivery

B. Last trimester

C. Second trimester

**D. Before planning for pregnancy

A full-term baby delivered normal vaginal delivery, received initial care and ready to be discharged home.

Which of the following vaccines should be given before discharge?

**A. BCG and HBV

B. HBV and MMR

C. BCG and DTaP

D. MMR and DTaP

An infant presents to Well Baby Clinic. She can keep her head up unsupported and need back

support to set. She can smile and can reach mouth.

What is the developmental age in months?

A. 3

**B. 5

C. 7

D. 9

A 2-month-old infant with no risk factor screened in Well Baby Clinic.

Which of the following measures need to be screened?

A. Autism

B. Lead level

C. Body mass index

**D. Head circumference

What is the recommended age (in months) to screen for haemoglobin level in infant with no risk factors?

A. 6

**B. 12

C. 18

D. 24

A newborn delivered normally and discharged with the mother next day.

What is the recommended sensory screening should be performed?

**A. Hearing

B. Vision

C. Hearing and vision

D. Depends on clinical exam

Reflexes
Rooting
Moro

A 2-week-old infant seen in the clinic. Rubbing side of the mouth with tip of the little finger is one of the primitive reflexes (see image).

Which of the following is the name of this reflex?

A. Moro

**B. Rooting

C. Sucking

ROOTING REFLEX

Reflex Disappears
2 months ← Moro reflex
4 months ← Rooting reflex
5 – 6 months ← Palmar grasp

TABLE 2.12-3. **Primitive Reflexes**

REFLEX	DESCRIPTION
Moro reflex	Startling causes extension and abduction of arms followed by flexion
Rooting reflex	Stroking the cheek causes head to turn toward ipsilateral side (nipple seeking)
Sucking reflex	Touching the roof of the mouth causes a sucking response
Galant reflex	Stroking infant along one side of spine in prone position causes flexion of lower body toward ipsilateral side
Palmar grasp	Stroking palm causes fingers to curl
Plantar reflex	Stroking the sole causes dorsiflexion of big toe and fanning out of the other toes; it is normal through age 12 months Babinski sign: Persistence after age 12 months or reappearance indicates an upper motor neuron (UMN) issue

D. Parachute

A 2-week-old infant seen in the clinic. Rubbing side of his mouth with tip of the little finger is one of the primitive reflexes (see image).

What is expected age (in months) for this reflex to disappear?

A. 2

**B. 4

C. 6

D. 8

A 1-week-old infant seen in screening clinic (see image).

Which of the following is the name of this primitive reflex?

STEP REFLEX

A. Rooting

**B. Stepping

C. Parachute

D. Lateral neck

A 2-week-old infant seen in screening clinic (see image).

What is expected age (in months) for this reflex to disappear?

Disappears at 2 MONTHS

**A. 2

B. 4

C. 6

D. 8

A 5-year-old boy is brought to the clinic by his mother. She is concerned of bed-wetting overnight despite toilet training, compared to his sister when she was in his age she controls herself.

Until what age this is considered as a normal behaviour?

A. 5

**B. 6 years

C. 7

D. 8

An 8-year-old boy is brought to the clinic by his mother. She is concerned of bed-wetting overnight despite toilet training and compered to his sister when she was in his age with good control.

Which of the following pelvic muscle is affected and possible target therapy?

A. Rectus

**B. Detrusal

C. Perianal

D. Pelvic floor

An 11-year-old boy is brought to the clinic by his mother. She is concerned of bed-wetting overnight despite toilet training and several sessions of discussion. He feels a shamed and asked help from his family and physician.

Which of the following is the best management?

A. Avoid punishment

B. Desmopressin intra-nasal

C. Alarm beds with positive reinforcement

**D. Family centred approach and techniques

A 9-year-old boy brought to the clinic by his mother. She is concerned of bed-wetting overnight for one month. He was dry since age of 6 years and the mother gave history of fever and foul smell of his urine recently. Urine dipstick done (see lab result).

Blood pressure 90/60 mmHg
Heart rate 76 /min
Respiratory rate 18 /min
Temperature 37.6 °C

Test Result Normal Values
Color dark yellw clear or light yellow
Appearance cloudy clear
Specific gravity 1030 1001-1030
Nitrite present Absent
Leukocytes 7 0-3 per high power field

Which of the following is the most likely diagnosis?

A. Nocturnal enuresis

**B. Urinary tract infection

C. Improper personal hygiene

D. Normal pattern at this age

A 2-month-old infant is brought to Well Baby Clinic by her mother, who is concerns about her being not sleeping overnight and keeps crying intensely recently. These crying episodes are 2 to 3 times per week, last for 1 to 2 hours since the age of 1 month.

Which of the following is the typical age of this condition?

A. First 6 weeks of life

B. First 2 months of life

**C. First 3 months of life

D. First 6 months of life

A 2-month-old infant is brought to Well Baby Clinic by her mother, who is concerns about her being not sleeping overnight and keeps crying intensely recently. These crying episodes are 2 to 3 times per week, last for 1 to 2 hours since the age of 1 month.

Which of the following is the most likely diagnosis?

A. Child abuse

B. Temper tantrum

C. Seizure attack

**D. Infantile colic

A 2-month-old infant is brought to Well Baby Clinic by her mother because she is crying intensely recently and is not sleeping well overnight. The mother gave history of normal feeding, no fever or vomiting. These crying episodes are 2 to 3 times per week, last for 1 to 2 hours since the age of 1 month.

Which of the following is the recommended revealing measure?

A. Changing formula

B. Oral colic drops

C. Getting a baby sitter

**D. Behavioural adaptation

A 3-year-old girl is seen in the clinic. The mother gives history of yelling, hitting and saying "no" with other oppositional behaviours. 6th June DHA

Which of the following is the most likely diagnosis?

A. Depression

B. Anxiety disorder

**C. Temper tantrums

D. Mental retardation

A 2.5-year-old girl seen in the screening clinic. The mother gave history of yelling, hitting and saying "no" with other oppositional behaviours. 6th June DHA

Which of the following is the most appropriate counselling should be given?

A. Ignorance behaviour

B. Antidepressant agent

C. Strict and firmness behaviour

**D. Reinforcing positive behaviours

A 3-hour-old newborn seen in the Nursery for assessment. The mother gave a family history of early infancy death secondary to primary immunodeficiency.

Which of the following is the recommended first vaccination (Saudi program)?

**A. Do not give BCG vaccine

B. Give BCG and follow up in clinic

C. Give vaccines as per national program

D. Start intravenous immunoglobulin

A 6-month-old infant presents to Vaccination Clinic. The mother gave history of flu-like symptoms and she is hesitant to give the vaccines as her child has a fever. On examination, the child looks healthy with normal exam.

Heart rate 107 /min
Respiratory rate 18 /min
Temperature 38 °C
Oxygen saturation 95 %

Which of the following is the best next action?

A. Start antibiotic course

B. Re-schedule after 2 weeks

**C. Proceed with vaccination

D. Give antipyretics and discharge

A 2-month-old infant presents to Vaccination Clinic.

What are the recommended vaccines according to national program?

A. IPV,HBV,DTP,HiB,MMR

B. IPV,HBV,DTP,HAV,PCV

**C. IPV,HBV,DTP,HiB,PCV

D. IPV,HBV,DTP,HiB

A 1-year-old infant presents to Vaccination Clinic with normal exam and growth.

What are the recommended vaccines according to national program?

A. OPV,MMR,HAV,PCV

B. Varecilla,PCV,HiB

**C. OPV,MMR,varecilla,PCV

D. OPV,MMR,varecilla,DTP

According to national Saudi program of vaccination for children up to primary school admission, which of the following disease is effectively prevented?

A. Q-fever

B. Japanese encephalitis

C. Herpes simplex encephalitis

**D. Haemophilus influenza meningitis

A 6-year-old child seen in pre-school screening clinic with normal growth and general health status.

What are the recommended vaccines at this stage according to national program in Saudi Arabia?

A. MMR,DTP,OPV

B. MMR,HBV,DTP,HAV

**C. MMR,varicella,DTP,OPV

D. MMR,varicella,OPV,PCV

A 36-month-old girl seen in the clinic. Her growth parameters as plotted (see image).

Which of the following is the most likely diagnosis?

A. Indeterminate

**B. Failure to thrive

C. Constitutional delay

D. Normal growth pattern

An 18-month-old boy is seen in screening clinic. The mother concerns about his growth.

Which of the following findings need referral for further management?

A. Persistence weight curve on 15% percentile

B. Persistence weight curve on 10 % percentile

C. Weight curve moves from 5% to 15% percentile

**D. Weight curve drops one percentile but still within normal ranges

A 2-year-old girl is seen in the clinic for pallor and tiredness. On examination, she looks healthy with normal vital signs; growth parameter and physical exam apart from conjunctival pallor (see lab results).

Blood pressure 90/70 mmHg
Heart rate 97 /min
Respiratory rate 18 /min
Temperature 36.6 °C
Oxygen saturation 95 %

Test Result Normal Values
RBC 4.5 4.8-7.1 x 1012/L (Newborn)
4.6-4.8 x 1012/L (Child)
Hb 87 165-195 g/L (Newborn)
112-165 g/L (Child)
HCT 0.32 0.44-0.64 (Newborn)
0.32-0.42 (Child)
MCH 25 28-33 pg/cell
MCV 74 80-95 fl
Reticulocyte 1.1 0.2-1.2 %
Platelets count 350 150-400 x 109/L
Iron 7 7.2-17.9 µmol/L (Infant)
9-21.5 µmol/L (Child)
Total iron binding capacity 94 17.9-71.6 µmol/L
Ferritin 12 20-200 µg/L

Which of the following is the most likely diagnosis?

A. Macrocytic anemia

B. Thalassemia trait

C. Sickle cell disease

**D. Iron deficiency anemia

A 9-month-old infant is suspected to have iron deficiency anemia. CBC and iron profile ordered pending the results.

Which of the following indexes is expected to be high?

A. MCV

B. Ferritin

C. Hemoglobin

**D. Iron binding capacity

RDW, TIBC, Transferrin ↑

Iron, Ferritin ↓

A 4-month-old infant seen in the clinic with CBC result. The mother concerns about the findings (see lab results).

Test Result Normal Values
Hb 9 165-195 g/L (Newborn)
112-165 g/L (Child)

MCH 25 28-33 pg/cell
MCV 77 80-95 fl
Reticulocyte 1.1 0.2-1.2 %
Platelets count 330 150-400 x 109/L
WBC 10 9.1-30.1 x 109/L (Birth)
6.1-17.5 x 109/L (1-23 months)

Which of the following is the most likely diagnosis?

**A. Physiologic anemia

B. Thalassemia trait

C. Sickle cell anemia

D. Lead poisoning

A 5-year-old child with bronchial asthma seen in the clinic because of uncontrolled course of disease despite using ventolin regularly. Mother has asthma and using similar inhaler but she expresses poor technique of ventolin delivery to her child.

Which of the following is the most likely reason for her child's problem?

A. Child neglect

B. Poor compliance

**C. Improper technique

D. Need further evaluation

A 5-year-old child with bronchial asthma under control with inhalers. Mother concerned about the future of her child's asthma during adulthood.

Which of the following is the most likely prognosis?

A. Chronic lung disease

**B. Most of the children grow out of it

C. Asthmatic during adulthood

D. No correlation between childhood and adulthood asthma

A 3-year-old child with bronchial asthma on ventolin nebulizer at home as per needs. The mother expresses concern that the family cannot go out of the home most of the time because the nebulizer machine need electricity power source.

Which of the following is the most appropriate counselling should be given?

A. Agree and support their decision as the priority is asthma control

B. Find someone to take care of asthmatic child if family goes out of the home

**C. Educate with clear instructions inhaler usage and advice to stop nebulizer

D. Find out nebulizer machine with portability feature

What is the most effective treatment for moderate bronchial asthma severity?

A. Beta agonist agents

B. Beta agonist agents and steroids

**C. Long acting beta agonist agents with steroids

D. Long acting beta agonist agents with anticholenergics

A 6-year-old boy presents to Emergency Room with acute asthma attack responding to initial management with improved respiratory distress. His vitals after stabilization are recorded. The decision made for hospitalization.

Blood pressure 110/70 mmHg
Heart rate 97 /min
Respiratory rate 20 /min
Temperature 36.6 °C
Oxygen saturation 88 %

Which of the following is the most likely reason for admission?

**A. Hypoxia

B. Patient age

C. Hypotension

D. Asthma attack

A 2-year-old child diagnosed in the Emergency Room with pneumonia. The mother gave history of poor oral intake and vomiting for whatever orally introduced. Clinically, the child looks well with no distress. 6th June DHA

Blood pressure 88/56 mmHg
Heart rate 110 /min
Respiratory rate 23 /min
Temperature 36.6 °C
Oxygen saturation 95 %

Which of the following reasons justifies the child hospitalization?

A. Age of the child

B. Vital signs findings

**C. Inability to take orally

D. Primary diagnosis of pneumonia

Antibiotics
Amoxicillin

A 3-year-old child seen in the clinic with fever and cough for 5 days following flu-like prodrome. On examination, he had decrease air entry and crackles over right lung middle zone. Chest X-ray is done (see image and lab results).

Blood pressure 90/64 mmHg
Heart rate 110 /min
Respiratory rate 20 /min
Temperature 36.6 °C
Oxygen saturation 97 %

Test Result Normal Values
Hb 12 165-195 g/L (Newborn)
112-165 g/L (Child)
Platelets count 328 150-400 x 109/L
Neutrophils 80 40-60%
WBC 22 4.5-13.5 x 109/L (2-10 years)
4.5-11.1 x 109/L
(11 years-older adult)
Neutrophils 84% (2.4-7.3 x 109/L) 30%-77%
(2-10 years)
(2.7-6.5 x 109/L) 40%-75%
(11 years-older adult)
Lymphocytes 15% (2.8-9.3 x 109/L) 26%-56% (Birth)
(3.7-10.7 x 109/L) 20%-64%
(1-23 months)

Which of the following is the most appropriate management?

A. Reassurance

B. Bronchodilator and steroids

C. Admit for intravenous antibiotics

**D. Discharge on amoxicillin for 7 days

Bronchiolitis

A 2-month-old infant present to Emergency Room with cough, sneezing, circumoral cyanosis occasional with frothy secretion from mouth for the 3 days. On examination, she looks well with moderate tachypnea and intercostal retraction. Chest reveals scatted rhonchi and crackles all over but good air entry.

Blood pressure 80/50 mmHg
Heart rate 138 /min
Respiratory rate 48 /min
Temperature 36.6 °C
Oxygen saturation 91 %

Which of the following is the most likely diagnosis?

**A. Bronchiolitis

B. Heart failure

C. Bronchial asthma

D. Gastroesophageal reflux

A 6-month-old infant with cough and fever diagnosed as bronchiolitis. On examination, she had mild distress with intercostal retraction and chest auscultation reveals diffuse crackles.

Blood pressure 92/67 mmHg
Heart rate 145 /min
Respiratory rate 56 /min
Temperature 36.6 °C
Oxygen saturation 89 %

Which of the following is the best management?

**A. Admit for oxygen and hydration therapy

B. Send home with instruction when to come back

C. Admit for antibiotics and oxygen administration

D. Admit for bronchodilation and steroid management

A 3-year-old child presents to the screening clinic (see image).

Which of the following is the most likely diagnosis?

**A. Trisomy 21 syndrome

B. Trisomy 18 syndrome

C. Trisomy 13 syndrome

D. Normal ethnic features

Which of the following is the most common congenital heart defect in Down syndrome?

**A. Cushion defect

B. Atrial septal defect

C. Coarctation of aorta

D. Ventricular septal defect

A 4-month-old boy with Down syndrome seen in the screening clinic.

Which growth chart should be used?

A. No special charts

B. Individualized chart

**C. Down syndrome charts

D. Standard growth chart

A 4-day-old boy with Down syndrome seen in the screening clinic.

Which of the following is the most striking feature?

DISEASE	GENETIC ABNORMALITY	PRESENTATION/FEATURES	ASSOCIATED DISEASES	OTHER FACTS
Down syndrome	Trisomy 21, which occurs due to meiotic nondisjunction (95%), Robertsonian translocation (4%), or mosaicism (1%)	Presents with intellectual disabilities, a flat facial profile, upward slanted eyes with epicanthal folds, single palmar crease, general hypotonia, and extra neck folds (nuchal folds are sometimes seen on prenatal ultrasound)	Atlantoaxial instability (can lead to spinal cord compression), duodenal atresia, Hirschsprung disease, CHD Most common cardiac malformation: Complete AV canal defect (both systolic ejection murmur and holosystolic murmur present) (60%); ASDs, VSDs, PDA, and complex CHD make up the remainder GI anomalies (duodenal atresia or stenosis, imperforate anus, and esophageal atresia) Ophthalmologic disorders (refractive errors, strabismus, nystagmus, cataracts, and keratoconus) Endocrine disorders (type 1 DM, hypothyroidism) Risk for ALL, hypothyroidism, and early-onset Alzheimer disease	The most common chromosomal disorder and cause of intellectual disabilities Associated with advanced maternal age

**A. Hypotonia

B. Doughy skin

C. Simian creases

D. Curved fifth little finger

What are the most common endocrine diseases associated with Down syndrome?

**A. Hypothyroidism

B. Hyperthyroidism

C. Hypoparathyroidism

D. Panhypopituitarism

A 1-year-old diagnosed with Down syndrome, seen in the screening clinic. The mother who is 27-year-old is asking about risk of recurrence in future pregnancy.

What is the most appropriate counselling should be given?

A. Carry no further risk

B. Depends on mother age

**C. Depends on parents and child genetics profile

D. Father genetics has no role in recurrence rate

A 2.5-year-old boy seen in the clinic with skin rash. There is history of mild abdominal pain but the child looks healthy otherwise (see image).

Which of the following is the most likely diagnosis?

A. Measles

B. Chickenpox

C. Meningococcemia

**D. Henoch-schnlein purpura

A 6-year-old child seen in the clinic with fever and sore throat. She has had contact with child developed flu-like symptoms. Throat exam showed mild hyperaemia. Rapid throat test was negative for streptococcal infection and throat swab sent for culture.

Blood pressure 110/70 mmHg
Heart rate 76 /min
Respiratory rate 18 /min
Temperature 36.6 °C
Oxygen saturation 95 %

Which of the following is the best management at this stage?

**A. Supportive treatment

B. Start antibiotics pending culture result

C. Administer 1 shot of ceftriaxone intramuscular

D. Start amoxicillin for 10 days regardless of culture result

A 3-year-old child presents with history of increasing eye puffiness for 1 week especially in the morning. He has had flu-like illness 2 week ago. On examination, he looks well, not in distress and no lower limb edema. Eye, chest and abdomen exams are normal (see lab results).

Blood pressure 110/70 mmHg
Heart rate 76 /min
Respiratory rate 18 /min
Temperature 36.6 °C
Oxygen saturation 95 %

Test Result Normal Values
Color Clear clear or light yellow
Protein +4 Absent
Glucose Absent Absent
Leukocytes 0 0-3 per high power field
Erythrocytes 0 0-2 per high power field

Which of the following has highest diagnostic value?

**A. Serum albumin

B. Renal ultrasound

C. Serum electrolytes

D. Urine total protein

A 5-year-old child presents with history of increasing eye puffiness for 1 week especially in the morning. He has had flu-like illness 2 week ago. On examination, he looks well, not in distress and no lower limb edema. Eye, chest and abdomen exams are normal (see lab results).

Blood pressure 100/70 mmHg
Heart rate 88 /min
Respiratory rate 18 /min
Temperature 36.6 °C
Oxygen saturation 95 %

Test Result Normal Values
Total Proteins 35 56-80 g/L
Albumin 16 36-52 g/L
Protein +4 Absent

Which of the following is the most likely diagnosis?

A. Nephritic syndrome

**B. Nephrotic syndrome

C. Hereditary angioedema

D. Protein losing enteropathy

A 6-year-old child presents with history of increasing eye puffiness for 1 week especially in the morning. He has had flu-like illness 2 week ago. On examination, he looks well, not in distress and no lower limb edema. Eye, chest and abdomen exams are normal (see lab result).

Test Result Normal Values
Total Cholesterol 3 <5.2 mmol/L
Triglycerides 10 <1.7 mmol/L
Protein +4 Absent
Leukocytes 0 0-3 per high power field
Erythrocytes 0 0-2 per high power field

Which of the following is the most appropriate management?

A. Antihistamine

B. Renal biopsy

**C. Systematic steroids

D. Albumin replacement

Which of the following is the most common cause of dehydration in children?

A. Heat stroke

B. Food poisoning

**C. Gastroenteritis

D. Drugs side effects

A 5-year-old child presents to Emergency Room with vomiting and diarrhea for 4 days. On examination, he looks dehydrated, hypoactive with sunken eyes, doughy skin and dry mucous membrane. The capillary refill is 4 seconds.

Blood pressure 90/70 mmHg
Heart rate 130 /min
Respiratory rate 22 /min
Temperature 36.6 °C
Oxygen saturation 95 %

Which of the following is the expected serum sodium level based on clinical finding?

A. Low

**B. High

C. Normal

D. No correlation

A 5-year-old child presents to Emergency Room with vomiting and diarrhea for 4 days. On examination, he looks dehydrated, hypoactive with sunken eyes and delayed skin turger with dry mucous membrane and capillary refill is 4 seconds. The child connected to cardiopulmonary monitor and IV access attained, blood sample sent for electrolytes.

Blood pressure 60/40 mmHg
Heart rate 134 /min
Respiratory rate 23 /min
Temperature 36.6 °C
Oxygen saturation 95 %

Which of the following is the most appropriate next action?

A. Start inotropes

B. Give 5% albumin bolus

**C. 20 ml per kg normal saline bolus

D. Start maintenance fluid waiting for serum electrolytes

A 9-month-old infant presents with history of fever, irritability and right ear rubbing. Ear exam showed air-fluid levels and bulging tympanic membrane.

Blood pressure 70/50 mmHg
Heart rate 110 /min
Respiratory rate 18 /min
Temperature 38.8 °C
Oxygen saturation 95 %

Which of the following is the most likely diagnosis?

**A. Acute otitis media

B. Acute otitis externa

C. Chronic otitis media

D. Chronic otitis externa

Which of the following organism is the most causative agent in paediatrics acute otitis media?

A. Viral

B. Fungal

**C. Bacterial

D. Mycoplasma

Impetigo

A 3-year-old child present to the clinic with skin lesion that is not itchy. No history of fever and

no previous illness (see image).

Which of the following is the most likely diagnosis?

A. Cellulitis

B. Folliculitis

**C. Impetigo

D. Toxic shock syndrome

Which of the following interval (in days) defines fever of unknown origin in paediatrics?

A. 7

**B. 14

C. 21

D. 28

A 7-year-old girl presents with fever, abdominal pain and vomiting. On examination, she looks unwell with suprapubic tenderness, but no rebound tenderness nor guarding. Bed side dipstick done (see lab results).

Blood pressure 110/70 mmHg
Heart rate 76 /min
Respiratory rate 18 /min
Temperature 39 °C
Oxygen saturation 95 %

Test Result Normal Values
Color turbid clear or light yellow
Appearance cludy clear
Nitrite pesent Absent
Leukocytes 22 0-3 per high power field
Erythrocytes 3 0-2 per high power field

Which of the following is the most appropriate management?

A. Admit for surgery

**B. Admit for iv antibiotics

C. Discharge with oral antibiotics

D. Call gynaecologist on duties

A 9-year-old boy seen in pre-sport screening clinic found to have fixed widely split second heart sound with grade 2 ejection systolic murmur at upper left sternal border. ECG was normal.

Blood pressure 110/70 mmHg
Heart rate 76 /min
Respiratory rate 18 /min

Temperature 36.6 °C
Oxygen saturation 95 %

Which of the following is the most appropriate next action?

**A. Treadmill exercise test

B. Start diuretics and captopril

C. Reassurance and discharge from clinic

D. Cardiology referral for catheterization

A 3-year-old girl presents to the screening clinic found to have central obesity and short stature. On examination, she has moon face with hump on her back.

Blood pressure 130/70 mmHg
Heart rate 76 /min
Respiratory rate 18 /min
Temperature 36.6 °C

Which of the following has highest diagnostic value?

A. Renal ultrasound

B. Height-weight chart

C. Thyroid function test

**D. ACTH stimulation test

A 5-year-old child managed in Paediatrics Intensive Care Unite for diabetic ketoacidosis with insulin infusion and fluid correction (see lab result).

Test Result Normal Values
Sodium 138 134-146 mmol/L
Potassium 2.8 3.5-5.1 mmol/L
Chloride 101 97-108 mmol/L
Bicarbonate 22 21-28 mmol/L

Which of the following is the most likely explanation of low potassium?

A. Vomiting

**B. Insulin therapy

C. Diuretics therapy

D. Bicarbonate therapy

Red eye reflex

A 2-month-old infant seen in the screening clinic and the red reflex eye exam shown (see image).

Which of the following is the most appropriate next step in management?

A. Send for brain imaging

B. Next available appointment

C. Reassurance as its normal finding

**D. Immediate referral to ophthalmology

A 4-year-old boy previously healthy came to the clinic with history of limping for the last 2 days. On physical examination, he is keeping his left leg flexed and refusing to move it or allowing anyone to touch it. Imaging is showing effusion of the left hip.

Blood pressure 90/61 mmHg
Heart rate 126 /min
Respiratory rate 29 /min
Temperature 38.8 °C
Oxygen saturation 98 %

Which of the following is the most likely causative organism?

A. Enterobacter

B. H. Influenzae

C. Group B streptococcus

**D. Staphylococcus aureus

Neurofibromatosis NF 1

A 4-year-old boy brought to the clinic. During the physical exam, a 7 cafe-au-lait macule over his trunk. The mother stated she and many of her family members have the same "birth-marks".

Which of the following is the best next step?

A. Order MRI brain

B. Family Counselling about neurofibromatosis type 1

**C. Referral to medical geneticist for further evaluation and genetic testing

D. Referral to genetic counsellor for further education about neurofibromatosis type 1

A 3-year-old boy is diagnosed of tuberous sclerosis. There is no previous history of same disease in the family.

Which of the following is the best option of genetic testing?

A. Exome sequencing

**B. Single-gene testing

C. Chromosomal microarray

D. Genetic testing panel of multiple genes

A 3-year-old boy is diagnosed of tuberous sclerosis. His mother has the same disease and was

tested positive for a pathogenic mutation in TSC1 gene.

Which of the following is the most appropriate genetic testing to be performed?

A. Exome sequencing

B. Single-gene testing

C. Genetic testing panel of multiple gene

**D. Targeted testing for the familial variant

Reassurance

A 4-month-old girl brought to well-baby visit. Her mother has complained of frequent episodes of spitting up after each feeding. These episodes have gotten worse over the past few weeks. There is no history of fever, cough or diarrhea. The girl has been exclusively breastfed for good time every 3-4 hours. On physical examination, her growth parameters are at 90th percentile for age. The rest of her exams are normal.

Which of the following is the next step in the management?

A. Ph probe

**B. Reassurance

C. Upper endoscopy

D. Ultrasound abdomen

A 1-month-old boy presented to the Emergency Room with history of forceful, nonbilious vomiting. The mother is very concerned as he is her first baby and was delivered by caesarean section. She stated that he is always hungry no matters how much he feeds. Physical examination showed a palpable "olive" in the abdominal right upper quadrant.

Which if the following is the likely finding in his initial laboratory evaluation?

A. Hyperkalemia

B. Hyponatremia

**C. Hypochloremia

D. Metabolic acidosis

A 1-month-old boy presented to the Emergency Room with history of forceful, nonbilious vomiting. The mother is very concerned as he is her first baby and was delivered by caesarean section. She stated that he is always hungry no matters how much he feeds. Physical examination showed a palpable "olive" in the abdominal right upper quadrant.

Which of the following is the most appropriate initial imaging study?

A. CT abdomen

B. MRI abdomen

C. Upper GI series

**D. Ultrasound abdomen

A 12-year old girl is complaining of nausea and vomiting when going on flight longer than 1 hour.

Which of the following vomiting treatments is the best choice in her condition?

A. Ginger

B. Ondansetron

C. Granisetron

**D. Diphenhydramine

A 1-month-old boy presented to the Emergency Room with history of forceful, nonbilious vomiting. The mother is very concerned as he is her first baby and was delivered by caesarean section. He has no fever or diarrhea but seems hungry all the time despite her best efforts feeding him. On examination, he looks dehydrated and his weight did not change in comparison to his birthweight. His abdominal palpation revealed an olive on the right upper quadrant.

Which of the following is the most appropriate immediate next step in the management?

A. Upper GI series

B. Prescribe promethazine

C. Abdominal ultrasonography

**D. Correction of dehydration and electrolyte imbalance

A 2-year-old boy with Down syndrome is brought to the clinic after his mother noticed that his eyes are turning in.

Which of the following is the most appropriate method to screen for strabismus?

A. Red Reflex

B. Cover test

C. Visual Acuity

**D. Corneal light reflex

Which of the following is the most appropriate age to do Red reflex test?

**A. All ages

B. 3-4 years

C. Pre-school at age 6

D. 6 months until cooperative for vision testing

A 3-month-old girl is hospitalized for confirmed pertussis infection. She is started on macrolide therapy. She has 2 other siblings at home, 3 and 5 years old who are both up to date for their vaccinations.

Which of the following is the most appropriate recommendation for her asymptomatic sibling?

A. Immediate booster vaccine with DTaP

**B. Start chemoprophylactic therapy with macrolide

C. Close observation for signs and symptoms of pertussis

D. Booster vaccine with DTaP if they are from high risk group

A 6-month-old boy presents to the Well Baby Clinic for the 6-month vaccination. The mother states that he has developed febrile seizure with his last DTaP vaccine.

Which of the following is the best answer to the mother concerns?

A. Delay the vaccination until he is 18 month old

B. Febrile seizure is true contraindication to DTaP vaccination

C. He has to have the vaccine regardless of the adverse reactions

**D. Febrile seizure does not have long-term sequelae and is not contraindication for subsequent vaccines

A 6-month-old boy presents to the Well Baby Clinic for the 6-month vaccination. The mother states that he has developed fever of 41 °C with his last DTaP vaccine.

Which of the following is the best answer for the mother concern?

A. Delay the vaccinations until he become 18 month old

B. This is a very high fever and he should not have subsequent DTaP vaccines

C. Fever is not contraindication for subsequent vaccines as long as it is not associated with seizure

**D. High fever does not have any long term sequelae and is not contraindication for subsequent vaccines

Which of the following is an absolute contraindication to DTaP vaccination?

A. Seizure

B. Hypotonic-hyporesponsive episodes

C. Prolonged sever crying for 3 hours or more

**D. Encephalopathy occurring within 7 days of previous dose not attributed to another cause

A 3-month-old girl presented to the Emergency Room with symptoms of paroxysmal episodes of cough followed by whooping sound at the end. It is occasionally associated with perioral cyanosis and post-tussive vomiting. These symptoms have gotten worse when started to have fever of 39.5° C. History revealed she did not receive her 2-month vaccine.

Which of the following is the most common expected complication?

**A. Pneumonia

B. Dehydration

C. Otitis media

D. Pneumothorax

A 3-month-old girl presented to the Emergency Room with symptoms of paroxysmal episodes of cough followed by whooping sound at the end. It is occasionally associated with perioral cyanosis and post-tussive vomiting. History revealed that she did not receive her 2-month vaccine. Her mother has already given her 2 doses of antimicrobial treatment.

What is the gold standard method to diagnose this condition?

A. Blood culture

B. Serologic testing

C. Respiratory culture

**D. Nasopharyngeal polymerase chain reaction

A 3-month-old boy presented to the Emergency Room with history paroxysmal episodes of cough followed by whoopi sounds at the end of each episode. It is associated with perioral cyanosis and post-tussive vomiting. There is no history of diarrhea. This illness has been preceded by runny nose a few days ago. History revealed he did not receive his 2-month vaccine yet. On examination, the child looks unwell and tachypneic.

Which of the following is the most likely diagnosis?

**A. Pertussis

B. Adenovirus pneumonia

C. Mycoplasma pneumonia

D. Chlamydia trachomatis pneumonia

A 3-month-old boy presented to the Emergency Room with history paroxysmal episodes of staccato cough, inspiration between each cough. It is associated with perioral cyanosis and post-tussive vomiting. There is no history of diarrhea. This illness has been preceded by conjunctivitis few days ago. On examination, the child looks unwell and tachypneic with auscultatory crackles. He has normal white blood cell count with elevated eosinophils on laboratory evaluation. 6th June DHA

Which of the following is the most likely diagnosis?

A. Pertussis

B. Adenovirus pneumonia

C. Mycoplasma pneumonia

**D. Chlamydia trachomatis pneumonia

A 3-month-old boy presented to the Emergency Room with history paroxysmal episodes of cough associated with an inspiratory whoop and possessive emesis. It is associated with fever,

conjunctival redness and diarrhea. His immunization is up to date.

Which of the following is the most likely diagnosis?

A. Pertussis

**B. Adenovirus infection

C. Mycoplasma pneumonia

D. Chlamydia trachomatis pneumonia

A 9-month-old boy presents to the clinic with skin rash noticed by his parent over the past few weeks. His parents are known to have eczema before.

Which of the following is the typical site of eczematous plaques at this age?

A. Upper back

B. Diaper area

C. Dorsum of the feet

**D. Scalp, cheeks, and forehead

An 8-year-old boy presents to the clinic with skin rash noticed by his parent over the past few weeks. His parents are known to have eczema before.

Which of the following is the typical site of eczematous plaques at this age?

A. Upper back

B. Dorsal feet

**C. Flexural surface

D. Scalp, cheeks and forehead

A 14-year-old boy presents to the clinic with skin rash noticed by his parent over the past few weeks. His parents are known to have eczema before.

Which of the following is the typical site of eczematous plaques at this age?

A. Popliteal fossa

**B. Perioral region

C. Antecubital fossa

D. Scalp and forehead

Honey colored crusted lesion

A 6-years-old boy who has been treated since infancy for eczema is coming now to be evaluated for honey-colored crusted lesion in antecubital skin area bilaterally. He has no fever but skin infection is suspected.

Which of the following is the most likely cause of the skin infection? Δ Impetigo

A. Coxsackie virus

B. Herpes simplex virus

**C. Staphylococcus aureus ✓ (MC)

D. Group A streptococcus ✓

Herpes

A 6-year-old boy who has been treated since infancy for eczema is coming now to be evaluated for severely itching umbilicated vesico pustular skin rash that is grouped in "clusters of grapes" appearance overlying diffuse eczematous plaques. A superimposed skin infection is suspected.

Which of the following is the most likely etiology?

A. Coxsackie virus

**B. Herpes simplex virus

C. Staphylococcus aureus

D. Group A streptococcus

A 5-year-old boy who has been treated for eczema with increasing strength of topical steroid is presenting with worsening eczematous plaques on flexural surfaces of his elbows and knees.

Which of the following is the best next step in the management?

A. Consider another diagnosis

B. Switch to topical calcineurin inhibitors

C. Referral to dermatologist to start narrow-band UV-B phototherapy

**D. Inquire about parent compliance with the treatment and answer their concerns

A 10-year-old girl presented to the clinic with pruritic, eczematous plaques over her flexural region and xerosis. Good bathing practice and adequate hydration are recommended to the patient.

Which of the following is considered a good bathing practice recommendation?

A. Emollients are not important after good prolonged bathing

B. Olive oil is superior to coconut oil in decreasing severity

C. Using strong soap cleansers is more effective than non-soap cleansers

**D. Emollient choice is highly dependent on provider and patient predilection

A 5-year-old boy presents to the clinic with pruritic, eczematous plaques over his flexural region and xerosis. Good bathing practice and adequate hydration are recommended to the patient.

Which of the following is considered a good bathing practice recommendation?

**A. Using non-soap cleansers is preferred to avoid irritation

B. Emollients are not important after good prolonged bathing

C. Lotions have been proven to be more effective than creams

D. Olive oil is superior to coconut oil in decreasing severity

A 9-year-old boy presented to the Emergency Room with severe abdominal pain for 8 hours.

Which of the following is the most common surgical emergency in such patient?

**A. Appendicitis

B. Cholecystitis

C. Intussusception

D. Perforated ulcer

An 8-year-old girl presented to the Emergency Room with severe abdominal pain for the last 6 hours. The pain is constant and not relieved by acetaminophen. She cannot stand up straight because of the pain. Physical Examination reveals a mild grade fever with severe abdominal tenderness over the right lower quadrant and rebound tenderness

Which of the following imaging study is the most appropriate to confirm the diagnosis?

**A. CT abdomen

B. US abdomen

C. MRI abdomen

D. Magnetic resonance cholangiopancreatography

A 2-year-old girl presented to the Emergency Room with intermittent, severe abdominal pain and unusual appearance of her stool "currant jelly". On examination, she looks well and alert with sausage-shaped abdominal mass.

Which of the following is the diagnostic method of choice in this condition?

A. CT abdomen

B. MRI abdomen

C. Contrast enema

**D. Ultrasound abdomen

A 2-year-old girl presented to the Emergency Room with intermittent, severe abdominal pain and unusual appearance of her stool "currant jelly". On examination, she looks well and alert with sausage-shaped abdominal mass. Ultrasound abdomen revealed "target-shaped" finding.

Which of the following is the best option in treatment?

A. Emergency surgical correction

B. Keep her NPO and start total parental nutrition

**C. Warmed saline enemas under ultrasound visualization

D. Insert nasogastric tube to gravity drain and keep her NPO

A 3-year-old boy presents to the Emergency Room for the second time with non-resolving high-grade fever (39.5 °C). Fever has started 6 days ago and was prescribed antipyretic, which did not help much in relieving the fever. Instead, He has developed bilateral non-exudative conjunctivitis. His immunizations are up-to-date. On examination, he has diffusely erythematous oropharynx, red cracked lips, and a strawberry tongue. He has non-exudative congested throat with cervical lymph node that measure around 1.5 cm.

Which of the following is the most likely diagnosis?

A. Mumps

B. Measles

C. Enterovirus

**D. Kawasaki disease

A 3-year-old boy presents to the Emergency Room for the second time with non-resolving high-grade fever (39.5 °C). Fever has started 6 days ago and was prescribed antipyretic when he was evaluated initially 3 days ago. However, Antipyretic did not help much in relieving the fever. Instead, He has developed develop bilateral non-exudative conjunctivitis. His immunizations are up-to-date. On examination, he has diffusely erythematous oropharynx, red cracked lips, and a strawberry tongue. He has non-exudative congested throat with cervical lymph node that measured around 1.5 cm. IVIG is ordered.

Which of the following may indicate a poor response to IVIG in such patient?

A. Anemia

B. Neutropenia

**C. Elevated CRP

D. Hypernatremia

Kawasaki

A 4-year-old boy is diagnosed with Kawasaki Disease on day 8 of illness. He is admitted to the hospital for further management.

Which of the following is the most appropriate initial treatment regimen?

**A. Aspirin and IVIG

B. Aspirin and IV corticosteroid

C. IVIG and cyclosporine

D. Aspirin and infliximab

A 4-year-old boy is diagnosed with Kawasaki Disease on day 6 of illness. He is admitted to the hospital for further management. He has received aspirin and IVIG without any complications. His fever has subsided and his conjunctivitis has significantly improved.

Which of the following modalities is the best to evaluate his coronary arteries?

**A. Echocardiography

B. Cardiac catheterization

C. Magnetic resonance angiography

D. Computed tomographic angiography

A 4-year-old boy presented to the clinic with history of decreased appetite and activity over the past month. He lost significant weight since his last outpatient visit.

Which of the following is the most common cause of cancer in such patient?

**A. Leukemia

B. Lymphoma

C. Neuroblastoma

D. Retinoblastoma

A 4-year-old girl is brought to the clinic because her mother had felt a mass in the abdomen last night when she was bathing her. She has been otherwise well with no weight loss, fever, or bone pain. Her blood pressure is 130/80 mmHg. Physical examination shows a well-thriving kid with a palpable firm mass in the right flank (see lab results).

Test Result Normal Values
Color Clear clear or light yellow
Appearance Clear clear
pH 6.5 4.3-8
Specific gravity 1020 1001-1030
Protein trace Absent
Glucose absent Absent
Ketones absent Absent
Urobilinogen absent No more than 6 mg/day
Nitrite absent Absent
Erythrocytes 40 0-2 per high power field
Hemoglobin +3 Absent

Which of the following is the most likely diagnosis?

A. Leukemia

B. Lymphoma

**C. Wilms tumour

D. Neuroblastoma

A 4-year-old girl is brought to the clinic because her mother had felt a mass in the abdomen last night when she was bathing her. She has been otherwise well with no weight loss, fever, or bone pain. Her blood pressure is 130/80 mmHg. Physical examination shows a well-thriving kid with a palpable firm mass in the right flank (see lab results).

Test Result Normal Values
Color Clear clear or light yellow

pH 7.0 4.3-8
Specific gravity 1010 1001-1030
Protein Absent Absent
Glucose Absent Absent
Ketones Absent Absent
Nitrite Absent Absent
Hemoglobin +++ Absent
Leukocytes Absent 0-3 per high power field
Erythrocytes 50 0-2 per high power field

Which of the following is the most appropriate next step in her diagnostic work-up?

Δ WILMS

Most Accurate → CT Scan ē contrast

→ BIOPSY

Initial → Abdominal U/S

A. Plain abdominal radiography

B. Abdominal computed tomography

C. Abdominal magnetic resonance imaging

**D. Plain abdominal radiography and abdominal ultrasonography

A 2-month-old girl brought to the Well Baby Clinic. On examination, she has absent red reflex in her left eye. She is otherwise healthy and growing well with no concerns from her parents.

Which of the following is the most appropriate next step evaluation?

A. CT of the brain and orbits

B. MRI of the brain and orbits

C. Reassurance of the parent as this is a normal variation

**D. Dilated eye examination under sedation by an ophthalmologist

LEUKOCHORIA
REFERRAL TO OPHTHALMOLOGIST

A 2-month-old girl brought to the Well Baby Clinic. On examination, she has absent red reflex in her left eye. She is otherwise healthy and growing well with no concerns from her parents.

Which of the following is the most likely tumour in such patient?

A. Fibrosarcoma

**B. Retinoblastoma

C. Teratoma

D. Soft tissue sarcoma

LEUKOCORIA

Loss (whitening) of the red reflex (Fig. 2.9-41). Important causes in children include retinoblastoma and congenital cataract.

A healthy 8-month-old circumcised boy brought to the clinic by his parents with history of fever since morning. He has not had nasal congestion, cough, or diarrhea. He had 1 episode of emesis when he was given acetaminophen. He has continued to breastfeed and has had a normal number of wet diapers. He is mildly ill appearing. There is no clear focus of infection on examination.

Temperature 39.4 °C

Which of the following factors is most strongly associated with an increased probability of having

a urinary tract infection?

A. Being male

B. Episode of vomiting

**C. Temperature of 39.4°C

D. Duration of the fever

A healthy 3-month-old uncircumcised boy brought to the clinic by his parents with history of fever since morning. He has not had nasal congestion, cough, or diarrhea. He had 1 episode of emesis when he was given acetaminophen. He has continued to breastfeed and has had a normal number of wet diapers. He is mildly ill appearing. There is no discernible focus of infection on examination.

Temperature 38.4 °C

Which of the following factors is most strongly associated with an increased probability of having a urinary tract infection?

A. Being male

B. Duration of fever

**C. Being uncircumcised

D. Temperature of 38.4°C

A 4-month-old uncircumcised boy brought to the Emergency Department with a 2-day history of fever. He has not had vomiting, diarrhea, cough, or nasal congestion. There has been no known contact with ill persons. He has continued to breastfeed and has not had a decrease in the number wet diapers. He is mildly ill appearing but alert and interactive. Examination shows no focus of infection. A bag urine sample is collected and sent for urinalysis (see lab results).

Temperature 39.1 °C

Test Result Normal Values
Color light yellow clear or light yellow
pH 8 4.3-8
Specific gravity 1030 1001-1030
Protein Absent Absent
Glucose Absent Absent
Ketones Absent Absent
Nitrite Positive Absent
Leukocytes 11 0-3 per high power field

Which of the following results of urinalysis would increase the probability of having a urinary tract infection?

**A. Nitrite

B. Urine pH

C. Leukocytes

D. Specific gravity

A 3-month-old boy presented history of fever for the last 2 days. On examination, he is circumcised and has no focus of infection. Urine sample obtained by bladder catheterization is performed. He was started on oral trimethoprim-sulfamethoxazole. After being at home, his mother is called and states that he is back to his normal activity with no more fevers. The mother is advised to have him complete the 10-day course of trimethoprim-sulfamethoxazole (see report)

Urine culture:
Grows 80,000 colony-forming units (CFU) per milliliter of Escherichia coli that is susceptible to trimethoprim-sulfamethoxazole.

Which of the following is the most appropriate next step in management?

**A. Renal ultrasonography

B. Voiding cystourethrogram

C. No further imaging or treatment is indicated

D. Antibiotic prophylaxis with trimethoprim-sulfamethaxole until 2 years of age

Antibiotic
UTI
Cephalexin

A previously healthy 4-month-old uncircumcised boy is brought to the Emergency Department with a 2-day history of fever. He has not had vomiting, diarrhea, cough, or nasal congestion. There has been no known contact with ill persons. He has continued to breastfeed and has not had a decrease in the number wet diapers. He is mildly ill appearing but alert and interactive. Examination shows no focus of infection. Urinary catheterization is performed (see lab results).

Temperature 39.1 °C

Test Result Normal Values
pH 7.5 4.3-8
Specific gravity 1010 1001-1030
Protein Absent Absent
Glucose Absent Absent
Ketones Absent Absent
Nitrite Positive Absent
Leukocytes 30-40 0-3 per high power field
Erythrocytes 5-10 0-2 per high power field

Which of the following is the most appropriate empirical therapy?

**A. Oral cephalexin

B. Oral azithromycin

C. Intravenous cefepime

D. Intravenous ceftriaxone

Hyperbilirubinemia
Conjugated

Which of the following is the most suggestive of hemolysis as a cause for neonatal hyperbilirubinemia?

6th June DHA

A. Low reticulocyte count

B. Negative direct Coombs test result

**C. Increased conjugated bilirubin level

D. Increased unconjugated bilirubin level

A 3-week-old boy is brought to the Emergency Department because of fever, poor feeding, watery stools, and abdominal distention. He was a product of a full-term pregnancy with normal spontaneous vaginal delivery. He has history of intrauterine growth restriction. He has full sepsis and meningitis workup which came back to be negative.

Which of the following features is associated with a lower risk for developing necrotizing enterocolitis?

A. Being male gender

**B. Being full-term baby

C. Age less than 4 weeks

D. Negative sepsis and meningitis work up

A male neonate born by cesarean section at 31 weeks' gestation with birth weight 1300g. He has developed apnoea, high gastric residual levels, and bloody stools. Necrotizing enterocolitis is suspected.

Which of the following features is associated with a higher risk for developing necrotizing enterocolitis?

A. Male gender

B. Bloody stool

C. Cesarean section delivery

**D. Birth weight of less than 1500g

Antibiotic
Amoxicillin
Otitis

6th June DHA

A 4-month-old girl with unilateral purulent effusion, decreased tympanic membrane mobility with pneumatic otoscopy, no fever, and no other symptoms. She is breastfeeding very well and does not use pacifier. She has no recent history of infections.

Which of the following is the best next step in management?

**A. Start amoxicillin treatment

B. Start amoxicillin-clavulanate

C. Observe with follow-up in 48hr

D. ENT referral for evaluation of tympanostomy tubes

A 19-month-old boy presented to the clinic with right lower eyelid swelling, erythema, and tenderness for 1 day. He has fever reaching up to 38.5° C with decreased appetite and activity. He was given diphenhydramine without any improvement of the eyelid swelling. His parent

denied any visual disturbances, diplopia or any other swelling.

Which of the following is the most likely diagnosis?

**A. Cellulitis

B. Hypoproteinemia

C. Allergic reactions

D. Subperiosteal hematomas

Streptococcus pneumonic Pneumonia

A previously healthy 13-month-old girl has 2-day history of fever and increasing cough. She continued to be breastfed with no vomiting. Her immunizations are up to date. She is alert and mildly ill appearing. On examination, there is no grunting or chest retractions. There are crackles heard over the right lung base. The remainder of the examination findings are normal. She has no known allergies.

Blood pressure 110/70 mmHg
Heart rate 146 /min
Respiratory rate 45 /min
Temperature 38.6 °C
Oxygen saturation 95 %

Which of the following is the most likely pathogen?

A. Moraxella catarrhalis

B. Mycoplasma pneumoniae

**C. Streptococcus pneumoniae

D. Haemophilus influenza type B

A 7-year-old girl is complaining of sore throat for the last 2 days. Today, she has developed fever of 38.7 °C when measured at home, which has been relieved by acetaminophen. On examination, she was found to have tender anterior cervical adenopathy and pharyngeal and tonsillar exudate. The rest of her physical exam is unremarkable.

Which of the following is best next step toward diagnosis?

A. Throat culture

B. Echocardiography

**C. Rapid antigen detection test

D. Fine needle aspiration for cervical adenopathy

A 13-year-old boy who has palpable lymph node in his neck. One of his close relatives has been diagnosed recently with lymphoma and his family are very worry about it.

Which of the following is most suggestive of a malignant rather than an infectious cause of lymphadenopathy?

A. Age of less than 5 years

B. Cervical Lymphadenopathy

C. Duration of less than 4 weeks

**D. Supraclavicular lymphadenopathy

An 11-year-old girl brought to the clinic for physical exam because one of her cousins has been diagnosed with lymphoma recently. She is worried about palpable lymph node in her neck.

Which of the following lymph nodes locations would be most concerning for malignancy?

A. Cervical lymphadenopathy

B. Inguinal lymphadenopathy

C. Submandibular lymphadenopathy

**D. Supraclavicular lymphadenopathy

A 4-year-old girl presented to the clinic with history of fever for last 3 days associated with sore throat and decrease oral intake. She also has difficulty in swallowing solid food. On examination, she has palpable cervical lymph node that is about 2 cm in size.

Which of the following is the most important step in evaluation?

A. Chest radiograph

**B. Lateral neck radiograph

C. Contrast-enhanced CT neck

D. Fine needle aspiration of the lymph node

Streptococcus Pyogene

A 4-year-old girl presented to the clinic with history of fever for last 3 days associated with sore throat and decrease oral intake. She also has difficulty in swallowing solid food. Her vaccination is up-to-date. On examination, she has palpable cervical lymph node that is about 2 cm in size, tender and fluctuates.

Which of the following is the most likely causative organism?

A. Pneumococcus

**B. Streptococcus pyogenes

C. Staphylococcus epidermidis

D. Haemophilus influenzae type B

A 13-year-old boy who has palpable lymph node in his neck. One of his close relatives has been diagnosed recently with lymphoma and his family is very worry about it.

Which of the following may influence the physician to consider lymph node biopsy?

**A. Associated with hepatosplenomegaly

B. Size more than 1 cm

C. Tender on palpation

D. Absence of fever

A previously healthy 13-month-old girl comes to the clinic with 2-day history of fever and increasing cough. She continued to be breastfed with no vomiting. Her immunizations are up to date. She is alert and mildly ill appearing. On examination, there is no grunting or chest retraction. She has crackles heard over the right lung base. The remainder of the examination findings is normal. She has no known allergies. Bacterial community-acquired pneumonia is suspected.

Respiratory rate 36 /min
Temperature 38.6 °C
Oxygen saturation 96 %

Which of the following would indicate a need for hospitalization?

A. Age of 13 month

B. Crackles on auscultation

C. Respiratory rate of 36 breath per min

**D. Inability to maintain hydration or oral intake

A 7-year-old girl presents to the clinic with fever and skin rash for 1 day. She has also pain and swelling in her both knees and wrists. The family gave a history of fever and sore throat two weeks ago which has been recovered completely. On examination, she has pain, swelling and limited movement in both knees and wrists. She has erythema marginatum rash. The remaining exam is unremarkable. She is started on antibiotic and anti-inflammatory medications.

Which of the following is the best next step in management?

**A. Echocardiography

B. Musculoskeletal MRI

C. Pulse methylprednisolone

D. Intravenous immunoglobulin

A 5-year-old boy is diagnosed with group A streptococcus tonsillitis and started on antibiotic treatment. He has a 2-year-old brother who is well and asymptomatic.

Which of the following is the best approach for his brother?

**A. Observation

B. Throat culture

C. Start antibiotic treatment

D. Throat swab for rapid antigen detection test.

Spitting up
GERD

A 2-month-old boy is being evaluated in Well Baby Clinic. He is the first child for a young mother

who is concerned about his fussiness and spitting up after feeds and in between feeds. He is otherwise healthy. His growth parameters are normal.

Which of the following is the most likely cause of his condition?

A. Gastroenteritis

B. Eosinophilic esophagitis

C. Gastroesophageal reflux disease

**D. Physiologic gastroesophageal reflux

Reassurance

A 2-month-old boy is being evaluated in Well Baby Clinic. He is the first child for a young mother who is concerned about his fussiness and spitting up after feeds and in between feeds. He is taking cow-milk based formula and otherwise healthy. His growth parameters are normal. His physical examination is normal.

What would be your next step in his management?

A. Observation

B. Pyloric ultrasonography

C. 24-hour impedance pH study test

**D. Reflux precautions and reassurance

A 2-month-old boy is being evaluated in Well Baby Clinic. He is the first child for a young mother who is concerned about his fussiness and spitting up after feeds and in between feeds. He is taking cow-milk based formula and otherwise healthy. His growth parameters are normal. His physical examination is normal.

Which of the following is an indication for further evaluation?

A. Male gender

**B. Failure to thrive

C. Spitting up while asleep

D. Spitting up between feeds

A 6-year-boy diagnosed previously with gastroesophageal disease. He is on proton pump inhibitor for long time is complaining of dysphagia and epigastria discomfort.

Which of the following is important history clue for Eosinophilic Esophagitis?

A. Overweight

B. History of snoring

**C. Chewing food excessively

D. Worsening of epigastric pain at night

Which of the following statements is normal weight gain in infants?

A. Double their birth weight at 10 months

B. Mean weight gain by 10 g/day in the first 3 month

C. Mean weight gain by 15 g/day in the first 3 month

**D. Mean weight gain by 30 g/day in the first 3 month

Which of the following is the most appropriate advice to a mother about breastfeeding schedule for her full term newborn in the first year?

A. On demand for first 4 month

**B. On demand every 2-4 hr for first 2 month

C. On demand 6 times per day for first 2 month

D. On demand 6-8 times per day at age 8-12 month

A newborn baby boy is born to unbooked 25-year-old mother. The mother has developed febrile illness immediately after birth but she is otherwise stable. She does not have record for any of the transmissible infections. She asked if she can breastfed her baby.

In which of the following conditions breastfeeding or expressed breast milk in the immediate postpartum period is acceptable?

A. Breastfeeding of HIV mother

B. Expressed breast milk of HIV mother

C. Breastfeeding in untreated active tuberculosis

**D. Expressed breast milk of untreated active tuberculosis

An 8-year-old boy has been complaining of recurrent abdominal pain for the past several months.

Which of the following would prompt an immediate search for an organic explanation?

A. Pain is around his umbilicus

**B. It last for more than 10 minutes

C. Occurs primarily around awakening

D. Occurs primarily around sleep time

Separation anxiety

A 7-year-old boy has had frequent periumbilical pain and nausea in the morning. He occasionally vomits. The symptoms started just after he started going to school. School phobia and separation anxiety are suspected.

Which of the following is the most appropriate in management?

A. Start domperidone

B. Start amitriptyline

C. Keeping the child out of school for at least 3 months

**D. Increasing the child's participation in age-appropriate activities

A 13-year-old boy is complaining of recurrent abdominal pain for the last year. The pain takes about 5 to 7 days to improve and it is usually associated increased frequency of stooling. In these occasions, his stool is watery and explosive. No history of vomiting, constipation or blood passage. Irritable bowel syndrome is suspected.

Which of the following is the most appropriate in management?

A. Avoid peppermint oil

**B. Avoid lentil ingestion

C. Increase Fruit Ingestion

D. Increase Honey ingestion

ANA

A 4-year-old girl presents with morning limp and swelling of her right knee that has been worsening for the last 2 months. On physical examination, she clearly has decreased range of motion as well as swelling and warmth of right knee. She has negative antinuclear antibody (ANA).

When should she be screened for uveitis by an ophthalmologist?

A. Every 3 months (ANA +ve)

**B. Every 6 months (ANA -ve)

C. Every 12 months

D. Not recommended if her ANA is negative

A 4-year-old girl presents with morning limp and swelling of her both knees that has been worsening for the last 2 months. She has no other symptoms. On physical examination, she clearly has decreased range of motion as well as swelling and warmth of both knees. She has normal laboratory investigation except a positive antinuclear antibody (ANA). Juvenile idiopathic arthritis (JIA) suspected.

Which of the following is the best classification of her disease?

A. Polyarticular JIA

**B. Oligoarthritis JIA

C. Systemic-onset JIA

D. Undifferentiated JIA

A 2-year-old boy brought to the Emergency Room for the second time with non-resolving high grade fever 39.5 °C. Fever started 6 days ago and was prescribed antipyretic when he was evaluated initially 3 days ago. However, antipyretic did not help much in relieving the fever. Kawasaki disease suspected.

Which of the following is one of the five principal clinical features of Kawasaki disease?

A. Arthritis

B. Myocarditis

C. Anterior uveitis by slit lamp examination

**D. Bilateral bulbar conjunctival injection without exudate

SLE
RHEUMATOLOGY
Hemolytic anemia

A 6-year-old girl presents to the clinic complaining of morning neck stiffness and pain in her fingers joints to the degree that she needs help in buttoning herself. She has flat erythema over the malar eminences that are sparing the nasolabial folds. One examination, she had painless mouth ulcer. On her finger's joints, there is clear swelling and tenderness.

Which of the following will make her fulfil 4 of the 11 American College of Rheumatology criteria for the classification of Systemic Lupus Erythematosus?

A. Weight loss

B. Erythema marginatum

C. Positive rheumatoid factor

**D. Hemolytic anemia with reticulocytosis

Vaccine

A 12-year-old girl diagnosed with systemic lupus erythematosus 10 months ago. She is currently on high doses of immunosuppressive treatment. Her immunization status is not known.

Which of the following vaccines should be recommended?

A. MMR

B. BCG

C. Varicella

**D. Annual influenza vaccine

SLE FLARE

A 12-year-old girl who is known to have systemic lupus erythematosus (SLE). Her disease is controlled on immunosuppressive medication. She is complaining of mild grade fever and dysuria. Her examination is unremarkable. The urinalysis is suggestive of urinary tract infection.

Which of the following should be avoided in her condition as it may cause SLE flare?

A. Cephalexin

B. Amoxicillin

C. Nitrofurontoin

**D. Sulfamethoxazole

Which of the following is not necessary to diagnose Nephrotic Syndrome?

A. Edema

B. Proteinuria

**C. Hypertension

D. Low serum albumin

A 5-year-old boy presented with eye puffiness and lower limb edema. He has no fever, vomiting or abdominal pain. His physical examination revealed well perfused extremities and lower limb pitting edema. The rest of his exam is unremarkable (see lab results).

Test Result Normal Values
Color Clear clear or light yellow
pH 6 4.3-8
Specific gravity 1010 1001-1030
Protein ++++ Absent
Glucose Absent Absent
Ketones Absent Absent
Nitrite Absent Absent
Hemoglobin Absent Absent
Leukocytes 0 0-3 per high power field
Erythrocytes 0 0-2 per high power field

Which of the following is the most common cause of nephrotic syndrome in such patient?

A. Finish type

**B. Minimal change disease

C. Membranous nephropathy

D. Focal segmental glomerulosclerosis

A 5-year-old boy who is known to have nephrotic syndrome presents to the clinic with severe abdominal pain and distention. He has omitted once a clear stomach content of his last meal. No diarrhea or constipation.

Which of the following this patient is at higher risk to have?

A. Hepatitis

B. Gastritis

**C. Peritonitis

D. Appendicitis

Nephrotic Remission

A 5-year-old boy presented with eye puffiness and lower limb edema. He has no fever, vomiting or abdominal pain. His physical examination revealed well-perfused extremities and lower limb pitting edema. The rest of his exam is unremarkable. His laboratory testing confirmed the diagnosis of nephrotic syndrome.

After starting him on treatment, which of the following defines complete remission?

A. Normal serum albumin

B. Complete resolution of his edema

**C. Urine dipstick negative or trace reading for 3 consecutive days

D. Urine dipstick negative or trace reading for 5 consecutive days

Remission Nephrotic

A 5-year-old boy presented with eye puffiness and lower limb edema. He has no fever, vomiting or abdominal pain. His physical examination revealed well-perfused extremities and lower limb pitting edema. The rest of his exam is unremarkable. His laboratory testing confirmed the diagnosis of nephrotic syndrome. He is started on steroid treatment.

Which of the following used to define steroid resistant nephrotic syndrome?

**A. Inability to induce a remission within 4 weeks of daily steroid therapy

B. Inability to induce a remission within 4 month of daily steroid therapy

C. Inability to induce a remission within 12 days of daily steroid therapy

D. Inability to induce a remission within 12 weeks of daily steroid therapy

A 5-year-old boy presented with eye puffiness and lower limb edema. He has no fever, vomiting or abdominal pain. His physical examination revealed well-perfused extremities and lower limb pitting edema. The rest of his exam is unremarkable. His laboratory testing confirmed the diagnosis of nephrotic syndrome.

Which of the following is the first line of treatment in this patient?

A. Rituximab

**B. Prednisone

C. Cyclosporine

D. Cyclophosphamide

A 2-week-old neonate is brought by his mother with complains of poor oral intake for the last 2 days. On examination, he has oral thrush and diaper dermatitis.

Which of the following is the most applicable management?

A. Oral anti-fungal for 7 days

**B. Topical anti-fungal for 5 days

C. Systemic anti-fungal for 5 days

D. Oral and topical anti-fungal for 5 days

Reassurance

A 3-day-old neonate start to develop skin lesions look like erythematous macules on an erythematous base, over the upper chest and the back (see lab results).

Blood pressure 85/55 mmHg
Heart rate 110 /min
Respiratory rate 18 /min
Temperature 36.6 °C
Oxygen saturation 99 %

Test Result Normal Values
RBC 5 4.8-7.1 x 1012/L (Newborn)
4.6-4.8 x 1012/L (Child)
Hb 145 165-195 g/L (Newborn)
112-165 g/L (Child)
Platelets count 250 150-400 x 109/L
WBC 9 9.1-30.1 x 109/L (Birth)
6.1-17.5 x 109/L (1-23 months)

Which of the following is the best management approach?

A. Topical antibiotics for 5 days

B. Consult dermatology for skin biopsy

**C. Reassurance as it is a benign condition

D. Full sepsis work up and oral antibiotics for 7 days

Which of the following is the most causative factor for retinopathy of prematurity?

A. Acidosis

**B. Hyperoxemia

C. Apnea of prematurity

D. Gram negative sepsis

A 4-month-old infant is brought to Emergency Room with complain of excessive sweating, pallor and altered level of conscious. The mother said he is not eating normally for the last 2 days and has recurrent vomiting (see lab results).

Test Result Normal Values
Blood urea nitrogen 2 0.7-6.7 mmol/L (Newborn)
1.8 to 6.4 mmol/L (Child)
Creatinine 34 27-88 µmol/L (Newborn)
27-62 µmol/L (Child)
Glucose 1.8 2.8-5 mmol/L (Newborn)
3.3 -5.5 mmol/L (Child)

Which of the following is the best initial management?

**A. Intravenous infusion of glucose 2 ml/kg of 10% dextrose

B. Intravenous infusion of glucose 2 ml/kg of 12.5% dextrose

C. Intravenous infusion of glucose 4 ml/kg of 12.5% dextrose

D. Intravenous infusion of glucose 10 ml/kg of 10% dextrose

A 2-month-old infant presented to the clinic with history of prolonged jaundice, constipation, large tongue and mottled dry skin. There is a positive family history of autoimmune disease (see lab results).

Test Result Normal Values
ACTH 10 2-11 pmol/L
Insulin fasting 15 10-104 pmol/L
Thyroid stimulating hormone 22 1-25m IU/L (1-4 days)
1.7-9 mIU/L (2-20 weeks)
0.7-6.4 mIU/L (21 weeks-14 years)
Thyroxine T4 (serum) 55 125-215 nmol/L (1-3 days)
100-200 nmol/L (1-12 months)
94-193 nmol/L (1-5 years)
80-150 nmol/L (5-15 years)
Triodothyronine T3 0.6 1.54-11.4 nmol/L (1-3 days)
1.6-4 nmol/L (1-12 months)
1.2-3.2 nmol/L (1-5 years)
1.2-3.2 nmol/L (5-15 years)

Which of the following is the most appropriate step in management?

A. Oral thyroxine for 1 month

**B. Life-long thyroxine replacement

C. Repeat the blood test after 1 month

D. Prednisolone replacement for 6 weeks

A 9-year-old boy presented with history of recurrent vomiting, lethargy, brown pigmentation of gum and skin crease with growth failure (see lab results).

Test Result Normal Values
Sodium 130 134-146 mmol/L
Potassium 6 3.5-5.1 mmol/L
Calcium total 3 2.2-2.7 mmol/L
Blood urea nitrogen 11 0.7-6.7 mmol/L (Newborn)
1.8 to 6.4 mmol/L (Child)
Creatinine 80 27-88 µmol/L (Newborn)
27-62 µmol/L (Child)
Prolactin 800 < 652 pmol/L (Male)
< 870 pmol/L (Female)
Cortisol 8 a.m. 66 138-635 nmol/L

Which of the following is the best management option?

**A. Daily hydrocotrisone

B. Daily thyroxine

C. Daily vitamin D

D. Daily vitamin B6

An 8-year-old child presented to Emergency Room with constipation, anorexia, lethargy and behavioural abnormality. Bony erosion of the phalanges was seen on wrist radiography (see lab results).

Test Result Normal Values

Blood urea nitrogen 3.2 0.7-6.7 mmol/L (Newborn)
1.8 to 6.4 mmol/L (Child)
Creatinine 45 27-88 µmol/L (Newborn)
27-62 µmol/L (Child)
Glucose 4 2.8-5 mmol/L (Newborn)
3.3 -5.5 mmol/L (Child)
Alkaline phosphatase 200 150-420 U/L (Infant)
100-320 U/L (Child)
Parathyroid hormone
(Intact PTH levels) 6.2 1.1-5.3 pmol/L
Parathyroid hormone
(N-terminal fraction) 3.1 0.8-2.5 pmol/L
Parathyroid hormone
(C-terminal fraction) 11 0-35.8 pmol/L
↑ Calcium total 5.3 2.2-2.7 mmol/L
↓ Phosphate 1.2 1.3-2.3 mmol/L
Magnesium 0.9 0.7-1.0 mmol/L

Which of the following is the best management approach?

A. Rehydration and statins

B. Diuretics and rehydration

C. Bisphosphonates, diuretics and statins

**D. Rehydration, diuretics and bisphosphonates

Which of the following is the most appropriate approach to manage nutritional rickets?

A. Daily administration of vitamin D1

B. Daily administration of vitamin D2

**C. Daily administration of vitamin D3

D. Daily administration of vitamin D4

A 3-year-old child presented with fever, headache, difficulty swallowing and throat pain. On examination, there is intense inflammation of the tonsils with purulent exudate that is more membranous in appearance.

Blood pressure 110/70 mmHg
Heart rate 150 /min
Respiratory rate 28 /min
Temperature 38.8 °C
Oxygen saturation 96 %

Which of the following is the most likely causative organism?

A. Corona virus

B. Influenza virus

**C. Epstein barr virus

D. Respiratory syncytial virus

A 7-month-old baby presented to the clinic with history of fever, irritability and disturb sleeping for 2 days. Ear examination showed perforation of the eardrum with pus visible in the external canal.

Blood pressure 110/70 mmHg
Heart rate 115 /min
Respiratory rate 22 /min
Temperature 38.8 °C
Oxygen saturation 97 %

Which of the following is the most likely diagnosis?

**A. Acute otitis media

B. Serious otitis media

C. Chronic otitis media

D. Otitis media with effusion

A 7-month-old baby presented to the clinic with history of fever, irritability and disturb sleeping for 2 days. Ear examination showed perforation of the eardrum with pus visible in the external canal.

Blood pressure 110/70 mmHg
Heart rate 115 /min
Respiratory rate 24 /min
Temperature 39 °C
Oxygen saturation 97 %

Which of the following is the most common causative organism?

Acute Otitis Media
↓
perforation
↓
RHINOV.

A. Rotavirus

**B. Rhinovirus

C. Adenovirus

D. Coronavirus

Which of the following asthmatic patients require hospital admission?

A. Heart rate more than 120 PPM

B. Whenever presented in acute attack

C. After 3 presentation to emergency room

**D. Oxygen saturation below 92% after high dose therapy

A 4-year-old child presented with recurrent chest infection and poor growth. On examination, chest auscultation revealed inspiratory crepitation with expiratory wheeze and finger clubbing.

Further exploration in the history revealed the presence of very offensive and greasy stools.

Which of the following is expected to be further identified in the physical examination?

**A. Nasal polyp

B. Gynecomastia

C. Inguinal hernia

D. Small joint swelling

A 3-year-old child presented to Emergency Room with complains of fever, headache and lethargy. On examination, clear purpuric rash, sign of shock and positive Kernig sign present. Eye exam revealed the presence of papilledema. The parents are bedside and worried about child condition and prognosis.

Which of the following complication is important for the parents?

A. Vision loss

**B. Hearing loss

C. Renal failure

D. Retinal haemorrhage

A 4-year-old child presented with itchy and scratching skin lesions that started on head and trunk then progress to peripheries. On examination, he was febrile with skin lesions appear as crops of papules, vesicles with surrounding erythema. The mother gave history of similar incident happen last week in his school. The parents are worried since there is an immunodeficient child at home.

What would be the best action plan to protect the immunodeficient kid?

A. Avoid skin contact

B. It is a self-limiting disease with no risk

C. Oral antiviral therapy for the immunodeficient child

**D. Specific immunoglobulin for the immunodeficient child

Which of the following represent a fetal complication from maternal infection with Parvovirus B19?

A. Usually asymptomatic

**B. May lead to fetal hydrops and death

C. Fetal arrhythmia and limp anomalies

D. Sever fetal skin disease with eye involvement

Newborn with normal physical examination. Upon reviewing the history with the mother, she mentioned that she had a daughter died with suspicion of immunodeficiency disease. The newborn is to be sent home and the parents ask about birth vaccines.

Which of the following is the most appropriate management plan?

**A. Receive Hepatitis B vaccine only

B. Receive routine birth vaccines

C. Order the birth vaccines and follow-up with Immunology team

D. Defer vaccines until full assessment by immunology team

During counselling an HIV positive mother who is pregnant and had several concerns regarding the outcome of her pregnancy. Her viral load is detectable although she is on treatment.

What would be the best advice during counselling the mother?

A. The neonate should not receive any therapy after delivery

B. She can breastfeed normally if she continued on the therapy

**C. She should deliver by cesarean section to decrease the chance of transmission

D. Therapy during pregnancy will not prevent the transmission of the virus to the baby

A 3-year-old child presented to Emergency Room with difficulty breathing, lip swelling and spreading skin rash. On examination, marked airway swelling observed with rash cover all the body. The mother said he was attending a party at his friend's house and she was not with him.

Which o of the followings will likely reveals the diagnosis?

A. Family history

B. Social history

**C. Allergy history

D. Nutritional history

A 4-year-old child presented to Emergency Room with difficulty breathing, lip swelling and spreading skin rash. On examination, marked airway swelling observed with rash cover all the body. The mother said he was attending a party at his friend house and she was not with him.

Which of the following is the most likely diagnosis?

A. Trauma

B. Insect bites

**C. Food allergy

D. Drug reaction

A 2-month-old infant found dead at his bed. According to the mother, he was feeding normally with usual activity. No history of fever or other abnormality. On examination, no sign of trauma or bruises on the skin. Baby gram was negative for fracture.

Which of the following history's part is important to make the diagnosis?

**A. Social history

B. Allergic history

C. Blood transfusion history

D. Maternal Medication history during pregnancy

A 2-month-old infant found dead at his bed. According to the mother, he was feeding normally with usual activity. No history of fever or other abnormality. On examination, no sign of trauma or bruises on the skin. Baby gram was negative for fracture. Mother is divorced and known smoker.

Which of the following is the most likely diagnosis?

A. Child abuse syndrome

B. Maternal smoking syndrome

**C. Sudden infant death syndrome

GYNAE

D. Apparent life threatening events

What is the most common risk factor for abruptio placentae?

A. Folate deficiency

B. Short Umbilical cord

**C. Maternal hypertension

D. Premature rupture of membranes

What is the most common cause of disseminated intravascular coagulopathy in pregnancy?

A. Uterine rupture

B. Placenta previa

**C. Placental abruption

D. Congenital bleeding disorder

A 36-year-old asymptomatic woman diagnosed with a 5 cm subserous uterine fibroid.

Which of the following is the most appropriate management?

A. Myomectomy

B. Hysterectomy

C. Endometrial biopsy

**D. Clinical surveillance

A 32-year-old obese woman with history of irregular menstruation and chronic anovulation,

found to have atypical complex hyperplasia on endometrial biopsy.

Which of the following is the most definitive treatment?

A. Letrazole

B. Tamoxifen

C. Spironolactone

**D. Oral progesterone

A 24-year-old primigravida who is a heavy smoker presented at 34 weeks of gestation to the Emergency Department with sudden heavy painful vaginal bleeding associated with uterine tenderness.

Which of the following is the most likely diagnosis?

A. Placenta previa

B. Uterine rupture

**C. Abruptio placentae

D. Fetal vessel rupture

What is the most common cause of postpartum hemorrhage?

**A. Uterine atony

B. Uterine inversion

6th June Exam DHA

C. Genital tract trauma

D. Amniotic fluid embolism

After spontaneous vaginal delivery of P2 woman, she had primary postpartum hemorrhage due to uterine atony.

Which of the following is considered the standard of care?

**A. Oxytocin

B. Ergonovine

C. Carboprost

D. Misoprostol

A 58-year-old woman presented with postmenopausal bleeding. Pelvic examination revealed a fungating irregular mass from the cervix.

Which of the following has the highest diagnostic value?

A. Pap smear

B. Pelvic MRI

C. Colposcopy

**D. Cervical biopsy

A 22-year-old woman who is 6 weeks of amenorrhoea presented with vaginal bleeding, severe lower abdominal pain and shoulder pain. On examination, she had tachycardia with low blood pressure, and her abdomen was distended with guarding and rebound tenderness. Pelvic examination revealed cervical motion tenderness. Pregnancy test is positive and an ultrasound showed no intrauterine pregnancy. What is the most appropriate next step in management?

**A. Laparoscopy

B. Methotrexate

C. Prostaglandins

D. Expectant management

What is the most common type of vulvar neoplasms?

A. Melanoma

B. Adenocarcinoma

C. Basal cell carcinoma

**D. Squamous cell carcinoma

A 45-year-old woman presented with itching of the vulva. On careful inspection in a bright light, an elevated localised watery red lesion measuring 0.5 cm was seen. She is diagnosed is vulvar intraepithelial neoplasia with carcinoma in situ.

Which of the following is the best management?

A. Vulvectomy

6th June Exam DHA

B. Laser therapy

C. Chemoradiation

**D. Local superficial excision

A 22-year-old woman seen in the clinic with sexual function disorders. She feels uncomfortable and fearful about potentially embarrassing discoveries during examination of the breasts and genitals. She refused to be seen by a male doctor and she requested a female doctor.

Which of the following is the most appropriate action?

A. Reject

**B. Respect

C. Convince

D. Discharge

A 42-year-old P6036 complaining of vaginal fullness, heaviness and discomfort that progress over the day and becomes noticeable after prolonged standing. She used to apply manual pressure to empty her urinary bladder completely. She also had stress urinary incontinence.

Which of the following is the most likely diagnosis?

**A. Cystocele

B. Rectocele

C. Enterocele

D. Procedentia

A 30-year-old woman is undergoing a laparotomy for ovarian cystectomy. She is a known smoker and she is on oral combined contraceptive pills for the last 6 years. During surgery, she developed tachycardia, hypoxemia and hypotension.

Which of the following is the most likely diagnosis?

A. Hemorrhage

B. Septic shock

C. Myocardial infarction

**D. Pulmonary embolism

A 30-year-old primigravid woman presented at 24 weeks of gestation with fatigue, face rashes oral ulcers and joints pain of both her wrists. On examination, painful metatarsal joints with swelling were detected (see lab result).

Blood pressure 130/80 mmHg

Test Result Normal Values
Protein + absent

Which of the following is the most likely diagnosis?

A. Osteoarhritis

B. Rheumatoid arthritis

C. Carpal tunnel syndrome

**D. Systemic lupus erythematosus

Which of following estrogen is the most abundant in human pregnancy?

**A. Estriol

B. Estrone

C. Cortisol

D. Estradiol

A 12-year-old girl presented to the Emergency Department complaining of cramping over the lower abdomen and radiates to the back and inner thighs. She declared that the pain was recurrent, associated with nausea and often after menstruation since her menarche.

Which of the following is the best treatment?

**A. NSAIDs

B. Tocolytics

C. Progestins

D. Oral contraceptives

A 34-year-old woman presented with profuse milky vaginal discharge. Office diagnosis demonstrates fishy odor (positive Whiff test). A wet-mount preparation of the discharge (see image).

Which of the following is the most likely diagnosis?

A. Mycoplasmas

B. Trichomoniasis

**C. Bacterial vaginosis

D. Vulvovaginal candidiasis

A 65-year-old postmenopausal woman presented with vague abdominal pain and bloating for the last 6 months. Pelvic ultrasound showed a complex ovarian mass 7 cm in diameter.

Which of the following tumour marker is essential during the work up?

**A. CA 125

B. Inhibin

C. B-hCG

D. Alpha -fetoprotein

A 62-year-old woman presented with abdominal pain, constipation and anorexia for 8 months. On examination, a solid irregular fixed pelvic mass was appreciated. Pelvic transvaginal ultrasonography showed a multilocular ovarian mass. Based on staging and histological classification, she was diagnosed with an advanced epithelial ovarian cancer.

Which of the following is the most appropriate management?

A. Surgery

B. Chemotherapy

C. Surgery followed by radiotherapy

**D. Surgery followed by chemotherapy

Which of the following is the most common degenerative changes of leiomyoma during pregnancy?

**A. Red

B. Fatty

C. Cystic

D. Hayaline

Which of the following is the first female physical signs of puberty?

A. Pubarche

B. Menarche

**C. Thelarche

D. Adrenarche

Which of the following is the predominant immunoglobulin secreted by breast milk?

**A. IgA

B. IgM

C. IgG

D. IgE

Which of the following is the most common cause of morbidity in multiple gestation?

**A. Prematurity

B. Birth trauma

C. Cerebral palsy

D. Congenital anomalies

A 25-year-old presents at 29 weeks of gestation with backache, fever and rigors (see lab results).

Blood pressure 100/55 mmHg
Temperature 39.7 °C

Test Result Normal Values
Protein ++ absent
Leukocytes 8 0-3 per high power field

Which of the following is the most appropriate immediate action?

A. Start oral antibiotics

**B. Admit for intravenous antibiotics

C. Arrange for ultrasound of renal tract

D. Give dexamethasone for fetal lung maturity

A previously healthy 20-year-old primigravida presented at 37 weeks gestation feeling unwell and tired. Her chest X-ray showed an enlarged heart. During the process of admission, she developed shortness of breath and died despite intensive measures had been anticipated.

Which of the following is the most likely diagnosis?

A. Myocardial infarction

B. Valvular heart disease

C. Ischemic heart disease

**D. Peripartum cardiomyopathy

A 23-year-old primigravida presents at 38 weeks of gestation in active labor. She complains of headache. Her laboratory studies show normal complete blood count, normal liver function tests and elevated protein/creatinine ratio. blood pressure 150/100 mmHg

Which of the following is the most likely diagnosis?

**A. Preeclampsia

B. HELLP syndrome

C. Chronic hypertension

D. Gestational hypertension

A 39-year-old primigravida presents at 30 weeks of gestation with sudden loss of fetal movements. An immediate ultrasound is performed and confirming the diagnosis of intrauterine fetal death.

Which of the following is the most appropriate immediate action?

A. Inform patient

B. Inform relatives

**C. Advance preparation

D. Perform further tests

Which of the following is the most appropriate action when examining a patient of different gender?

A. Be professional

**B. Ask for a nurse

C. Build a therapeutic relationship

D. Expose necessary body parts only

A 58-year-old menopausal woman presents with sexual dysfunction, dyspareunia. On examination, vaginal atrophy is noticed.

Which of the following is the most appropriate management?

A. Viagra

**B. Estrogen

C. Testosterone

D. Progesterone

A 26-year-old at her 8 weeks gestation presented with excessive nausea and vaginal bleeding. Abdominal examination revealed an enlarged uterus with absence of fetal heart sound. An ultrasonographic examination showed as in the image along with high B-hCG (see image).

Which of the following is the most likely diagnosis?

A. Ectopic pregnancy

**B. Hydatidiform mole

C. Threatened abortion

D. Incomplete abortion

A 23-year-old Rh-negative primigravida presents at 28 weeks of gestation for a follow-up visit. She is not sensitized to D antigen. Her husband is a Rh-positive.

Which of the following is the most appropriate management?

A. Amniocentesis

**B. Give Rh immunoglobulin

C. Repeat antibody titer every 2 weeks

D. Fetal assessment by ultrasonography

A 40-year-old P5005 woman presented to the Clinic. She has a strong family history of cancer where both her mother and sister died of cancer. BMI 31 kg/m2

Which of the following is the most appropriate counselling?

A. Be physically active

**B. Maintain a healthy weight

C. Limit consumption of fast food

D. Meet nutritional needs through diet alone

A recently married woman continued taking oral contraceptive pills prescribed before her marriage for irregular menstruation. Her husband wanted his wife to discontinue the pills as he wish to have a baby, but the wife refused.

Which of the following is most appropriate action?

A. Be empathic

B. Show support to wife

C. Show support to husband

**D. Mutual consent required for contraception

A 23-year-old nulliparous woman with history of infertility 2 years. Her menstrual cycle is regular coming every 29 days.

Which of the following is best used to confirm ovulation?

A. LH

B. FSH

C. Estrogen

**D. Progesterone

A 30-year-old G3 P1010 woman presented at 24 weeks of gestation with preterm labor. She gave a history of preterm delivery at 34 weeks in her first pregnancy.

Which of the following is the best method to evaluate her risk of preterm labor?

A. Fetal fibronectin

B. Uterine contractions

C. Serial pelvic examination

**D. Cervical length measurement

A 40-year-old pregnant woman at 32 weeks gestation with a history of 2 previous cesarean sections presents with mild painless vaginal bleeding few hours ago. Ultrasound shows partial placenta previa. Cardiotocogram is reactive.

Which of the following is the most appropriate management?

**A. Expectant management

B. Fetal biophysical profile

C. Immediate cesarean section

D. Amniocentesis for fetal lung maturity

A 26-year-old presents with mild vaginal bleeding after 7 weeks history of amenorrhea. Pelvic examination reveals a closed cervix and the uterus size is compatible with the duration of amenorrhea.

Which of the following is the most likely type abortion?

A. Complete

B. Inevitable

**C. Threatened

D. Incomplete

A 33-year-old woman delivered vaginally with right mediolateral episiotomy. An hour later, she was found to have an expanding 7 x 5 cm bluish, tense, and painful swelling of the perineum.

Which of the following is the best management?

A. Packing

B. Aspiration

C. Observation

**D. Surgical evacuation

A 40-year-old woman at 37 weeks of gestation with polyhydramnios presented in active labor following spontaneous rupture of membranes. Cardiotocogram shows persistent fetal bradycardia.

Which of the following is the most likely diagnosis?

6th June Exam DHA

**A. Cord prolapse

B. Rapid fetal descent

C. Placental insufficiency

D. Congenital heat abnormalities

A 30-year-old primigravida with 10 weeks of amenorrhea presents with abdominal pain and vaginal bleeding. Pelvic examination reveals partially dilated cervix, and the product of conception felt at the cervix.

Which of the following is the most likely type of abortion?

A. Missed

**B. Inevitable

C. Incomplete

D. Threatened

A 45-year-old P5005 woman is complaining of severe secondary dysmenorrhea and menorrhagia. Pelvic examination reveals the uterus is symmetrically enlarged and tender. Endometrial biopsy is normal.

Which of the following is the most likely diagnosis?

A. Leiomyomas

**B. Adenomyosis

C. Endometriosis

D. Uterine sarcoma

A 30-year-old woman with 6 weeks of amenorrhea presents with lower abdominal pain and mild vaginal bleeding. Examination reveals; she is hemodynamically stable and abdominal examination is soft and non-tender. Pregnancy test is positive (see lab result and report).

Test Result Normal Values
Human chorionic gonadotropin 4945 < 5 mIU/mL

Pelvic Ultrasound:
Shows a small mass <3.5 cm in right Fallopian tube, intact with no embryonic cardiac activity detected.

Which of the following is the best management?

A. Serial hCG testing

B. Surgical salpingectomy

C. Expectant management

**D. Medical treatment with methotrexate

A 33-year-old presented with preterm rupture of membranes at 34 weeks of gestation.

Which of the following is the most appropriate next step in management?

A. Tocolytics

**B. Antibiotics

C. Surfactant

D. Corticosteroids

A 40-year-old came in active labor at 38 weeks of gestation. It was found that she is having an intrauterine fetal death. The bad news were delivered to her in steps. After delivery she insisted that the baby should be taken to Intensive Care Unit on a ventilator as she believes that he is not really dead.

Which of the following best describes her condition?

**A. Denial

B. Escape

C. Acting out

D. Avoidance

A 30-year-old woman who is 38 weeks of gestation refuses to have cesarean section for fetal distress. The doctor explained to her that there is a risk of fetal death, but failed to convince her

to have the surgery.

Which of the following is the most appropriate action?

A. Refer to another doctor

**B. Deliver the child vaginally

C. Get permission from her husband

D. Get permission from hospital director

A 32-year-old woman at 10 weeks of amenorrhea presents with heavy vaginal bleeding. She is diagnosed to have an incomplete abortion. Her husband wants to sign the consent form in place of his wife for surgery, but she refuses. Who has the right to sign the informed consent form?

A. Father

B. Doctor

**C. Patient

D. Husband

A 13-year-old girl presents 8 months after menarche with irregular menstrual bleeding and intermenstrual bleeding.

Which of the following is the most likely diagnosis?

A. Bleeding disorders

B. Endocrine disorders

**C. Ovulatory dysfunction

D. Androgen secreting tumor

A 34-year-old delivered 5 months ago presents with failure to breastfeed her baby, dizziness and fatigue. Her obstetrics history revealed that she had a vaginal delivery complicated with retained placenta and severe postpartum hemorrhage.

Which of the following is the most likely diagnosis?

A. Pituitary adenomas

**B. Sheehans syndrome

C. Lymphocytic hypophysitis

D. Subarachnoid hemorrhage

A 12-year-old obese girl brought by her mother, 5-month after her menarche with irregular menstrual bleeding and increased weight. She has mild acne. The patient was uncomfortable, agitated and unable to cooperate to physical examination. BMI 26 kg/m2 What is the most likely disorder to be considered in communicating with this patient?

A. Mood

**B. Anxiety

C. Behavior

D. Substance use

A 36-year-old woman presents with complain of headache and nausea for 3 weeks. History revealed that she is a G3 P2002 and LMP was 15 weeks back. Blood pressure 180/120 mmHg Heart rate 76 /min Weight 51 kg Height 160 cm

Which of the following is the most likely diagnosis?

A. Pre-eclampsia

B. White coat syndrome

**C. Essential hypertension

D. Pregnancy induced hypertension

A 24-year-old woman P2 at 38 weeks' gestation developed atonic post-partum hemorrhage after delivering a healthy baby girl, APGAR 9 and 9, weighing 3.8 Kg. She is known to have bronchial asthma and it is controlled on regular medications. The obstetrician has started the uterine massage, infused adequate amounts of fluids and is going to initiate uterotonic medications.

Which of the following is contraindicated to use to manage the case?

A. Oxytocin

B. Misoprostol

C. Methylergonovine

**D. carboprost F2 alfa

A 24-year-old newly married woman presents to the Emergency Room complaining of sudden sharp lower abdominal pain, she does not have regular menstrual cycles and does not remember when the her last menstrual cycle began, she is not known to have any previous medical illness and had no prior surgeries (see lab result).

Blood pressure 100/70 mmHg
Heart rate 76 /min

Test Result Normal Values
Hb 11 130-170 g/L (Male)
120-160 g/L (Female)

Which of the following is the best advice?

**A. Further tests including BhCG and ultrasound

B. Admission and direct observation

C. Further tests including CT scan

D. Reassure and discharge home

A 30-year-old woman is in the second stage of labour for 3 hours by now. She is not on epidural analgesia. Abdominal examination shows an average size fetus of about 3 kg, in cephalic presentation with only 1/5 palpable head abdominally. Pelvic examination confirms that her cervix is fully dilated, fully effaced at +2 station.

Which of the following is the most appropriate action at this point?

**A. Perform a ventose delivery

B. Perform fetal scalp analysis

C. Review the patient in 2 hours

D. Preform an emergency cesarean section

A 24-year-old primigravida is known to have regular menstrual cycles at 13 weeks of gestation, presents to the Emergency Room complaining of mild brownish vaginal discharge, the patient denies passing any tissue. The pelvic examination shows a closed cervical Os and the bedside ultrasound is performed (see image).

Which of the following is the most likely diagnosis?

**A. Anembryonic pregnancy

B. Inevitable miscarriage

C. Missed miscarriage

D. Septic abortion

A 24-year-old primigravida is known to have regular menstrual cycles at 13 weeks of gestation, presents to the Emergency Room complaining of mild brownish vaginal discharge, the patient denies passing any tissue. The pelvic examination reveals a closed cervical os and the bedside ultrasound is performed (see image and lab result).

Blood pressure 110/70 mmHg
Heart rate 76 /min
Temperature 36.6 °C

Test Result Normal Values
Hb 12 130-170 g/L (Male)
120-160 g/L (Female)

Which of the following is the most appropriate advice?

A. Follow up in 4 weeks

B. Admit for observation

C. Perform a diagnostic laparoscopy

**D. Plan for termination of pregnancy

A 21-year-old primigravida at 34 weeks gestation was subjected to domestic violence by her

husband, she was punched on the face, pushed in her abdomen and hit the floor. Fetal heart tracing is reassuring. No uterine contractions are present, and there is no vaginal bleeding. Ultrasound shown an intact placenta.

Blood pressure 110/70 mmHg
Heart rate 76 /min
Respiratory rate 18 /min
Temperature 36.6 °C
Oxygen saturation 95 %

Which of the following is the most appropriate next step?

**A. Admit for observation and call the social worker

B. Confirm what has happened with her husband

C. Discharge and advice for bed rest

D. Immediate cesarean section

A 22-year-old woman G2 P1001 at 37 weeks gestation presents after fainting and has severe abdominal pain. She is cold and diaphoretic. Fundal height is 39 cm; the cervical os is closed and there is no vaginal bleeding.

Blood pressure 90/56 mmHg
Heart rate 130 /min

Which of the following is the most likely diagnosis?

A. Amniotic fluid embolism

**B. Abruptio Placenta

C. Placenta Previa

D. Septic Shock

A 22-year-old primigravida woman at 38 weeks gestation is in active labor for 4 hours. Cervical dilatation is 5 cm, +1 station. Examination 5 hours later demonstrates no change compared to the previous findings. Contractions occur every 3 minutes and lasts 60 seconds. Fetal hear rate is of category 1 cardiotocograph.

Which of the following is the most appropriate next step?

A. IV oxytocin

**B. Cesarean section

C. Review in 2 hours

D. Instrumental delivery

A 24-year-old woman G2 P0010 at 29 weeks has not felt fetal movement for 1 day. Fetal heart tones are heard by Doppler. Non-stress test is reactive. Biophysical profile demonstrates a score of 8.

Which of the following is the most appropriate next step?

A. Urgent delivery

B. Contraction stress test

**C. Biophysical profile in 1 week

D. Give steroid and repeat biophysical profile within 24 hours

A 19-year-old woman 23-week pregnant primigravida presents with a complaint of irregular brownish patches of varying sizes on face and neck (see image).

Which of the following is the most likely diagnosis?

A. Melasma

**B. Chloasma

C. Tinea nigra

D. Lichen planus

A 60-year-old woman presented to the Emergency Room with 1-week history of abdominal pain, the ultrasound finding showed a multiloculated, solid, right adnexal mass (see image and lab result).

Test Result Normal Values
CA-125 900 < 35 U/ml

What would be the recommended is the most suitable option?

A. Direct surgical cystectomy

B. Ultrasound guided aspiration

C. Follow up within 2 to 3 weeks

**D. Work up and consultation of a gynecologic oncologist

A 30-year-old primigravida presents to the Emergency Room complaining of vaginal spotting for the last few days, her history reveals irregularity of the menstrual cycles and that she has been trying to conceive for the last 3 years. Abdominal examination reveals tenderness in the lower abdomen and the pelvic examination reveals a closed cervical Os with cervical motion tenderness (see lab results).

Blood pressure 110/70 mmHg
Heart rate 105 /min
Temperature 36.6 °C
Weight 60 kg
Height 160 cm

Test Result Normal Values
Hb 130 130-170 g/L (Male)
120-160 g/L (Female)

HCT 038 0.42-0.52 (Male)
0.37-0.48 (Female)
MCH 19 28-33 pg/cell
MCHC 330 320-360 g/L
MCV 85 80-95 fl
Platelets count 155 150-400 x 109/L
WBC 4.6 4.5-10.5 x 109/L

Which of the following is the most appropriate next step?

A. Perform an abdominal ultrasound of the pelvis

**B. Confirm the patients pregnancy status

C. Know about the reason of infertility

D. Administer strong analgesia

A 24-year-old primigravida presents with the diagnosis of right ectopic pregnancy. The ultrasound revealed a 3 cm right tubal gestational sac with 5-week crown rump length, negative fetal heart activity and minimal amount of fluid in the pouch of Douglas. Her social history reveals that she lives in a village 80 km away from the city center (see lab result).

Blood pressure 90/50 mmHg
Heart rate 110 /min
Temperature 35.6 °C
BMI 36 kg/m2

Test Result Normal Values
Human chorionic gonadotropin 3500 < 5 mIU/mL

Which of the following would be the absolute contraindication to the use of methotrexate for this patient?

A. The B-hCG level and ultrasound findings

B. The far distance from medical services

C. The high body mass index

**D. The vital signs

A 32-year-old woman presents to the clinic with a 9-month history of amenorrhea concerning about her condition (see lab results).

Test Result Normal Values
Thyroid-Stimulating Hormone 3 0.4 - 5.0 µU/mL
Follicle-stimulating hormone 60 5-20 IU/L (Follicular phase)
15-35 IU/L (Mid cycle peak)
5-15 IU/L (Luteal phase)
50-100 IU/L (Postmenopausal women)
5-20 IU/L (men)
Testosterone 1 10.4-41.6 nmol/L (Male)
0.7-2.8 nmol/L (Female)
Luteinizing hormone 60 3-15 U/L (Male)

5-22 U/L (Follicular phase)
5-22 U/L (Luteal phase)
30-250 U/L (ovulatory phase)
> 30 U/L (Postmenopausal)
Prolactin 500 < 652 pmol/L (Male)
< 870 pmol/L (Female)
Human chorionic gonadotropin 4 < 5 mIU/mL

Which of the following is the most likely complication for this patient?

A. She is at significant risk of endometrial cancer

B. She is at increased risk for multiple gestation

C. She is at increased risk of ovarian cancer

**D. She is at significant risk of osteoporosis

A 26-years-old woman presents with vaginal discharge that is characterized by a thin milky appearance with a fish-like odor. On examination, the vaginal pH of 4.5 was found.

Which of the following is the most likely diagnosis?

A. Trichomonas vaginalis infection

B. Group B strep colonization

**C. Bacterial vaginosis

D. Gonorrhea

A 30-years-old hospitalized woman post cesarean section was treated for 6 days with clindamycin and cefuroxime for post-partum endometritis when she developed profuse, watery diarrhea, cramping abdominal pain and fever. An enzyme immunoassay of the stool revealed the presence of a bacterial enterotoxin.

Which of the following is the most appropriate treatment?

A. Ciprofloxacin

**B. Metronidazole

C. Amoxicillin plus clavulanate

D. Continue the same medication

Which of the following positions of a patient in labour would most likely result in the development of a third or fourth-degree laceration?

A. Unrestrained legs and semi-sitting

B. Unrestrained legs and squatting

C. Unrestrained legs and in chair

**D. Restrained legs and stirrups

A 30-year-old woman G4 P3003 at 34 weeks of pregnancy with breech presentation is asking about the possibility of external cephalic version, after reviewing the patient's information. Her first delivery was a caesarean section and was followed by a spontaneous vaginal delivery 4 years ago; she has no other significant medical or surgical history. The ultrasound is showing a single viable fetus of 3.2 kg with an anterior low-lying placenta and an amniotic fluid index of 4 cm. On examination, the patient is found to be in early labor and the pelvic assessment reveals a 3 cm dilated cervix with an intact membrane. Cardiotocography is done (see image).

Which of the following indicates the absolute contraindication for external cephalic version?

A. Cardiotocogrphy findings and gestational age

B. Previous history of cesarean section

C. Pelvic examination findings

**D. Ultrasound findings

There are many characteristics that may differentiate a malignant from benign adnexal masses by ultrasound images.

Which of the following ultrasound characteristics of a mass is suggestive of a benign ovarian cyst?

A. Bilateral

B. Fixed mass

**C. Hypoechoic

D. Multilocular with thick septation

A 42-year-old P3 is seeking an advice for the possibility of insertion of an intrauterine contraceptive device for family planning. The patient's history reveals that she became pregnant while using an intrauterine contraceptive device 4 years ago and in her second pregnancy; she underwent a cesarean section, which was complicated by post-partum ednometritis. Her menstrual cycles are irregular for the last 4 months with heavier flow than usual.

Which of the following is an absolute contraindication to the insertion of an intrauterine contraceptive device?

A. History of postpartum endometritis

B. Previous pregnancy with an IUCD

C. History of cesarean section

**D. Abnormal genital bleeding

A woman presents to the Emergency Department 15 days after giving birth by cesarean section. She complains of persistent vaginal bleeding. Blood pressure 110/70 mmHg Heart rate 85 /min Temperature 38.1 °C

Which of the following is the most likely diagnosis?

A. Mastitis

**B. Endometritis

C. Wound infection

D. Retained products of conception

A 29-year-old woman is planning to become pregnant. She has a normal menstrual period every 30 days.

Which of the following is the most appropriate to prescribe?

**A. Folic acid

B. Multivitamin

C. Ferrous fumirate

D. Calcium supplimentation

A 30-year-old pregnant un-booked patient is presenting to the Emergency Room with vaginal bleeding, the patient denies any abdominal pain and did not feel the fetal movements for the last few hours, and she was finally able to attend to the Emergency Room, as she had no form of transport to the hospital. Abdominal examination reveals a 34 cm fundal height.

Blood pressure 110/70 mmHg
Heart rate 101 /min
Temperature 36.6 °C

Which of the following is the most appropriate next step in management?

**A. Perform an ultrasound

B. Perform laboratory tests

C. Admit the patient to the ward

D. Perform a pelvic digital assessment

A 32-year-old pregnant woman at 36 weeks attends to the clinic complaining of abdominal pain that has been increasing in nature and is noted to be continuous, the patient denies any bleeding. Abdominal examination reveals a 38 cm fundal height, and the uterus was found to be tender and tense. Pelvic examination reveals a closed and un-effaced cervical os. The cardiogram shows category 1

Which of the following is the most likely diagnosis?

A. False labor

B. Active labor

**C. Abru ptio placenta

D. Fibroid red degeneration

A 22-year-old G3 P0020 with a history of 2 miscarriages presents to the Emergency Room with

mild vaginal bleeding, she denies history of passage of tissue. The last menstruation started 6 weeks ago, she complains of cough associated with hemoptysis for the last few days. On examination, the uterus is 12 weeks in size and is slightly tender. Pelvic examination reveals aggressive looking, irregular mass that bleeds on touch arising from the cervix (see lab results).

Blood pressure 110/70 mmHg
Heart rate 100 /min
Temperature 36.6 °C

Test Result Normal Values
Human chorionic gonadotropin 1005023 < 5 mIU/mL
Hb 7 130-170 g/L (Male)
120-160 g/L (Female)
HCT 0.21 0.42-0.52 (Male)
0.37-0.48 (Female)
MCH 25 28-33 pg/cell
MCV 70 80-95 fl

Which of the following is the most likely diagnosis?

A. Partial mole

B. Fibroid uterus

**C. Choriocarcinoma

D. Ectopic pregnancy

A 22-year-old G3 P0020 with a history of 2 miscarriages presents to the Emergency Room with mild per vaginal bleeding, she denies history of passage of tissue, The last menstruation started 6 weeks ago, she complains of cough associated with hemoptysis for the last few days. On examination, the uterus is 12 weeks in size and is slightly tender. Pelvic examination reveals aggressive looking, irregular mass that bleeds on touch arising from the cervix (see lab results).

Test Result Normal Values
Hb 70 130-170 g/L (Male)
120-160 g/L (Female)
HCT 0.21 0.42-0.52 (Male)
0.37-0.48 (Female)
MCH 25 28-33 pg/cell
MCV 75 80-95 fl
Human chorionic gonadotropin 1005023 < 5 mIU/mL

Which of the following is the most appropriate next step?

A. Biopsy the mass

B. Admit for suction evacuation

**C. Admit for staging and chemotherapy

D. Admit for preoperative workup for hysterectomy

A 30-year-old G3 P2002 at 8 weeks of gestation presents to the Emergency Room complaining of mild per vaginal bleeding, she denies history of passage of tissue and on examination the

abdomen is soft and non-tender. Pelvic examination reveals a healthy normally looking, closed cervical os with evidence of brownish discharge and no active bleeding seen (see report).

Bedside Ultrasound:
Reveals an intrauterine pregnancy with a crown-rump length of 7 weeks.

Which of the following is the most likely diagnosis?

A. Anembryonic pregnancy

B. Incomplete miscarriage

C. Inevitable miscarriage

**D. Threatened miscarriage

A 30-year-old G3 P2002 at 8 weeks of gestation presents to the Emergency Room complaining of mild per vaginal bleeding, she denies history of passage of tissue and on examination the abdomen is soft and non-tender. Pelvic examination reveals a healthy normally looking, closed cervical os with evidence of brownish discharge and no active bleeding noted (see report).

Blood pressure 110/70 mmHg
Heart rate 76 /min
Respiratory rate 18 /min
Temperature 36.6 °C

6th June Exam DHA

Bedside Ultrasound:
Reveals an intrauterine pregnancy with a crown-rump length of 7 weeks.

Which of the following is the most appropriate management?

**A. Reassurance

B. Administer aspirin

C. Admit for evacuation

D. Admit for observation

A 30-year-old G3 P2002 at 8 weeks of gestation presents to the Emergency Room complaining of mild per vaginal bleeding, she denies history of passage of tissue and on examination the abdomen is soft and non-tender. Pelvic examination reveals a healthy normally looking, closed cervical os with evidence of brownish discharge and no active bleeding detected (see report).

Blood pressure 110/70 mmHg
Heart rate 76 /min
Respiratory rate 18 /min
Temperature 36.6 °C

Bedside Ultrasound:
Reveals an intrauterine pregnancy with a crown-rump length of 7 weeks.

Which of the following is the most appropriate next step?

A. Complete bed rest

B. Surgical intervention

C. Termination of pregnancy

**D. Resume safely to daily activities

A 30-year-old primigravida at 6 weeks of gestation presenting to the Emergency Room with mild abdominal pains. The trans-vaginal ultrasound reveals a normal sized uterus with no clear gestational sac and a 3 cm right adnexal mass with no fetal pole, no free fluid is noted. On examination, the abdomen is soft, non-tender. The pelvic examination reveals a normal cervix with mild cervical motion tenderness (see lab results).

Blood pressure 110/70 mmHg
Heart rate 76 /min
Respiratory rate 18 /min
Temperature 36.6 °C

Test Result Normal Values
Hb 130 130-170 g/L (Male)
120-160 g/L (Female)
Human chorionic gonadotropin 2500 < 5 mIU/mL

Which of the following is the most likely diagnosis?

A. Cervical pregnancy

B. Threatened miscarriage

**C. Stable tubal ectopic pregnancy

D. Ruptured tubal ectopic pregnancy

A 30-year-old primigravida at 6 weeks of gestation presenting to the Emergency Room with mild abdominal pains. The trans-vaginal ultrasound reveals a normal sized uterus with no clear gestational sac and a 3 cm right adnexal mass with no fetal pole. On examination, the abdomen is soft, non-tender. The pelvic examination reveals a normal cervix with mild cervical motion tenderness (see lab results).

Blood pressure 110/70 mmHg
Heart rate 76 /min
Respiratory rate 18 /min
Temperature 36.6 °C

Test Result Normal Values
Hb 130 130-170 g/L (Male)
120-160 g/L (Female)
Human chorionic gonadotropin 2500 < 5 mIU/mL

Which of the following is the most appropriate management plans?

A. Conservative management

B. Medical management is suitable

C. Surgical management is suitable

**D. Both surgical and medical management

A 30-year-old primigravida at 6 weeks of gestation presenting to the Emergency Room with mild abdominal pains. On examination, the abdomen is soft, non-tender. The pelvic examination reveals a normal cervix with mild cervical motion tenderness. The patient lives 80 km away from the hospital and her husband is participating in a mission in a different city. She was brought to the Emergency Room by her neighbour (see lab results and report).

Blood pressure 110/70 mmHg
Heart rate 76 /min
Respiratory rate 18 /min
Temperature 36.6 °C

Test Result Normal Values
Hb 110 130-170 g/L (Male)
120-160 g/L (Female)
Human chorionic gonadotropin 5000 < 5 mIU/mL

Trans-vaginal Ultrasound:
Reveals a normal sized uterus with no clear gestational sac and a 4 cm right adnexal mass with no fetal pole.

Which of the patient characteristics favour surgical management?

A. Vital signs

B. B-hCG level

**C. Social history

D. Ultrasound findings

A 30-year-old primigravida at 6 weeks of gestation presenting to the Emergency Room with mild abdominal pains. On examination, the abdomen is soft, non-tender. The pelvic examination reveals a normal cervix with mild cervical motion tenderness (see lab results and report).

Test Result Normal Values
Hb 130 130-170 g/L (Male)
120-160 g/L (Female)
Human chorionic gonadotropin 3500 < 5 mIU/mL

Trans-vaginal Ultrasound:
Reveals a normal sized uterus with no clear gestational sac and a 3 cm right adnexal mass with no fetal pole.

What would be a prerequisite before counselling this patient for medical management?

A. The consent of the patients husband

**B. Accessibility of the patient to the hospital

C. The previous surgical history of the patient

D. They type of contraceptive previously used

A 45-year-old P5+3 presented to the clinic complaining of abnormal uterine bleeding for the last 3 months, the menstrual period is regular every 30 days and lasts for 5 days, associated with blood clots and pain that is not relieved by simple analgesia. The patient had previously undergone myomectomy 12 years back and 3 surgical evacuation for incomplete miscarriage. On examination, the uterus was not palpable but on pelvic examination, the uterus was found to be bulky and tender with no adnexal mass.

BMI 40 kg/m2

Which of the following is the most likely explanation for this patient's presentation?

**A. Adenomyosis

B. Endometriosis

C. Uterine fibroid

D. Endometrial cancer

A 50-year-old P2+3 patient known to be diabetic and hypertensive, presented to the clinic complaining of abnormal uterine bleeding for the last 8 months, the menstrual period is regular every 30 days and lasts for 5 days, associated with blood clots and pain that is not relieved by simple analgesia. The patient had previously undergone myomectomy 12 years back and was known to have all her pregnancies induced as she had poly-cystic ovarian syndrome. On examination, the uterus was not palpable but on pelvic examination revealed a normal sized uterus and a healthy looking cervix with no adnexal mass.

BMI 40 kg/m2

Which of the following is the most likely explanation for this patient's presentation?

**A. Endometrial hyperplasia

B. Uterine fibroid

C. Endometriosis

D. Adenomyosis

A 60-year-old P5+3 patient is known to be diabetic and hypertensive presented to the clinic complaining of post-menopausal bleeding for the last 8 months. The patient had previously undergone myomectomy 12 years back and 3 surgical evacuation for incomplete miscarriage. On examination, the uterus was not palpable but on pelvic examination the uterus was found to be bulky and tender with no adnexal mass (see image).

BMI 42 kg/m2

Which of the following is the most likely explanation for this patient's presentation?

A. Endometriosis

B. Uterine fibroid

**C. Endometrial cancer

D. Atrophic endometrium

A 60-year-old patient presents with postmenopausal bleeding for the last 8 months. The ultrasound is ordered (see image).

Which of the following is the most appropriate next step in assessing this patient?

A. CA 125

B. Cervical biopsy

C. MRI of the pelvis

**D. Endometrial biopsy

A 20-year-old G3 P2002 is in Labor and Delivery Ward in active labor at 6 cm dilatation. The patient is pregnant at 34 weeks and is known to have twin pregnancy.

What would be the characteristic that puts this patient at risk of postpartum hemorrhage?

A. Patients age

B. Patients parity

C. Gestational age

**D. Multiple gestations

A 30-year-old primigravida at 6 weeks of gestation is presenting to the Emergency Room with mild abdominal pains. An ultrasound reveals a 3 cm right adnexal mass with no fetal pole. On examination, the abdomen is soft, non-tender. The pelvic examination reveals a normal cervix with mild cervical motion tenderness (see lab result).

Blood pressure 110/70 mmHg
Heart rate 76 /min
Temperature 36.6 °C

Test Result Normal Values
Human chorionic gonadotropin 15000 < 5 mIU/mL

Which of the patient's characteristics would be causing failure of medical treatment?

A. Mass size

**B. B-hCG level

C. Gestational age

D. Clinical findings

In regards to the placental delivery during a cesarean section.

Which is the most accurate recommendation to reduce the incidence of postpartum

hemorrhage?

A. Manually extract the placenta

**B. Wait for spontaneous expulsion

C. Fundal pressure and massage is advised to help separate the placenta

D. Check for complete placental delivery by using a sponge inside the endometrial cavity

A 32-year-old pregnant patient at 36 weeks is in active labor and complaining of abdominal pain that has been increasing in intensity and continuous. She denies any bleeding. Abdominal examination reveals a 38 cm fundal height, and the uterus is found to be tender and tense. Pelvic examination reveals a 6 cm dilated cervix.

Which of the following is the most appropriate next step in management?

A. Perform an ultrasound

6th June Exam DHA

B. Repeat the vaginal examination

C. Perform a complete blood count

**D. Review the cardiotocogram trace

A 30-year-old G3 P2002 patient at 38 weeks of gestation in the Labor Room is in active labor, the patient is free of pain after initiation of epidural analgesia. She was diagnosed with pre-eclampsia with severe features and was started on MgSO4. On examination, the abdomen is showing a cephalic term pregnancy with 2/5 palpable head. On pelvic examination, the cervix is 6 cm dilated and fully effaced at -1 station. The patient is on oxytocin infusion and is contracting regularly. The cardiotocogram is done (see image).

Which of the following is most possible cause of cardiotogram findings?

**A. MgSO4 infusion

B. Epidural analgesia

C. Oxycontin infusion

D. Position of the head

A 30-year-old G3 P2002 patient at 38 weeks of gestation is in active labor, she is free of pain after initiation of epidural analgesia. She was diagnosed with severe features of pre-eclampsia and was started on MgSO4. On examination, the abdomen is showing a cephalic term pregnancy with 2/5 palpable head. On pelvic examination, the cervix is 6 cm dilated and fully effaced. The patient is on oxytocin infusion and is contracting regularly. The cardiotocogram is done (see image).

Blood pressure 90/50 mmHg
Heart rate 76 /min
Temperature 36.6 °C

Which of the following is most possible cause of cardiotogram findings?

A. MgSO4 infusion

B. Oxytocin infusion

**C. Epidural analgesia

D. Fetal head position

A 30-year-old woman G3 P2002 at 38 weeks of gestation is in the Labor Room. Changes on the cardiotocogram is noted while she is on oxytocin infusion with regular contractions. The diagnosis of pre-eclampsia with severe features was entertained earlier on and started her on MgSO4 accordingly. The labor pain is well-controlled after initiation of epidural analgesia. On examination, the abdomen is showing a cephalic term pregnancy with 0/5 palpable head. Pelvic examination shows cervix is 6 cm dilated and fully effaced and presenting part is at +1 station (see image).

Which of the following would explain the cause of the cardiotocogram findings?

A. MgSO4 infusion

B. Oxytocin infusion

C. Epidural analgesia

**D. Fetal head position

A 40-year-old P6 patient attends to the clinic complaining of dribbling of a small amount of urine with associated dyspareunia and dysuria. She denies any history of previous surgeries or the development of fever.

Which of the following is the most likely cause of the symptoms?

A. Urge incontinence

**B. Urethral diverticulum

C. Overflow incontinence

D. Stress urinary incontinence

A 40-year-old patient who is known to have COPD comes to the clinic complaining of small amounts of urine leaking every time she coughs; the patient denies having to wake up at night to pass urine and does not have dysuria or dyspareunia.

BMI 40 kg/m2

Which of the following is the most probable cause?

**A. Stress urinary incontinence

B. Overflow incontinence

C. Urinary tract fistula

D. Urge incontinence

A 60-year-old woman presents to the clinic complaining of urinary urgency, and frequent visits

to the bathroom to urinate with painful urination and urinary incontinence.

Which of the following is the most appropriate next step?

**A. Urinalysis

B. Urodynamics

C. Botox injection

D. Ultrasound pelvis

A 50-year-old patient presents to the clinic complaining of urinary leaking on coughing and straining. She is not known to have any medical or previous surgical history. On examination, the abdomen is soft and is non-tender. Pelvic examination reveals a normal sized anteverted, non-tender uterus. There was mild amounts of urine leakage when the patient was asked to cough.

Which of the following is the most appropriate management?

A. Sacral colpo-suspension

**B. Pelvic floor exercise

C. Colporrhaphy

D. Hysterectomy

A 25-year-old patient came to the clinic concerned about her sexual relationship after discovering that her husband was diagnosed with hepatitis B and was just started treatment. She was tested and all her serology came negative.

What would be the best advice for her sexual relationship with her husband?

A. Advice for abstinence

B. Advice to start oral contraceptives

C. Advice to resume normal sexual activity

**D. Advice to use of condoms during intercourse

Which of the following is the common cause of first trimester miscarriage?

A. Obesity

B. Low folate level

C. Cervical incompetence

**D. Chromosomal abnormalities

A 35-year-old woman who is pregnant calls the clinic for an advice. She has just found out that her hCG level is elevated.

Elevated hCG level indicates which of the following?

A. A high level of hCG is indicative of an ectopic pregnancy

B. A high level of hCG in the second trimester is indicative of molar pregnancy

C. A high level of hCG can stimulate production of TRH, causing hyperthyroidism

**D. A high level of hCG in the second trimester is the most sensitive marker for Down syndrome

A 24-year-old pregnant woman primigravida at 30 weeks' gestation complaining of lumps in her breasts. On inspection, these lumps are multiple in number and all within the areola. By palpation, they seem to be small, superficial, uniform in size, non-tender and soft.

Which of the following is the most likely diagnosis?

A. Lactiferous duct

B. Mondor's disease

**C. Montgomery's follicles

D. Fibrocystic breast changes

A 21-year-old primigravida is currently at 20 weeks gestation. Her past medical history is significant for mitral stenosis secondary to rheumatic heart disease as a child.

What physiologic change places her at risk for the development of heart failure during pregnancy?

A. Increase in red cell mass

**B. Increase in stroke volume

C. Increase in minute ventilation

D. Increase in renal plasma flow

A couple with history of infertility presents for hormone tests results. While reviewing, there is a discussion of the menstrual cycle using the diagram; in ovulation, there would be changes in concentration of different hormones in the blood (see image).

When does ovulation in the human usually occur?

A. Within the time of LH peak

**B. Within 36 hours after LH peak

C. Within 36 hours before LH peak

D. Within 36 hours after estradiol peak

A 36-year-old woman Para 1 comes to the clinic for genetic counseling. Her first child was born with sickle cell disease. She has since remarried, and is requesting prenatal testing according to the premarital requirements in the country.

Which of the following is appropriate to offer first?

A. Multiple markers screening

B. Paternal chromosome analysis

**C. Paternal hemoglobin electrophoresis

D. Maternal hemoglobin electrophoresis

A 25-year-old woman G2 P1001 at 36+4 weeks gestation with a history of prior cesarean section presents with abdominal pain and vaginal bleeding. Fetal heart baseline 160 bpm with minimal variability and repetitive late deceleration (see lab results).

Blood pressure 170/100 mmHg
Heart rate 120 /min
Temperature 37.7 °C

Test Result Normal Values
Hb 75 130-170 g/L (Male)
120-160 g/L (Female)
Platelets count 110 150-400 x 109/L
Fibrinogen 2.5 2-4 g/L

Which of the following is the most likely diagnosis?

**A. Placental abruption

B. Uterine rupture

C. Placenta previa

D. Vesa previa

A 35-year-old woman G5 P2113 presents to antenatal booking appointment and her last menstrual period of May 17, 2019.

What is estimated date of confinement using the Ngele rule?

A. February 17, 2020

B. February 20, 2020

C. February 21, 2020

**D. February 24, 2020

Which of the following best describes the uterus in a normal pregnancy?

A. Palpable midway between the symphysis pubis and the umbilicus

**B. Palpable just over the symphysis pubis

C. Palpable at the level of the umbilicus

D. Palpable just over the umbilicus

A 23-year-old G4 P1112 with a history of abortion in her last pregnancy presents to the

Emergency Room with vaginal spotting. Her LMP 7 weeks earlier. No abdominal pain or cramping reported and denies any vaginal discharge. On examination, abdominal tenderness detected, uterus not palpable. Cervical os closed.

Which of the following is the most likely diagnosis?

A. Missed abortion

B. Normal pregnancy

C. Inevitable abortion

**D. Threatened abortion

A 33-year-old woman presents with amenorrhea of 8-week duration. Pregnancy test is positive (see report).

Ultrasound:
Shows an empty uterus and right adenexal mass noted.

Which abnormality of the following processes is most likely cause of the above case?

A. Cleavage

B. Fertilization

**C. Implantation

D. Zygote formation

A 19-year-old woman presents to Labor and Delivery Ward in labor. She has not had any prenatal care. On examination, cervix is 4 cm dilated; the obstetrician palpate a bulging membrane but no fetal parts. Ultrasound demonstrates that the fetal head is in the fundus, the fetal spine is parallel to the mother's spine and the knees and hips are flexed. Both arms are flexed at the elbows.

Which of the following is the best description of lie of this fetus?

**A. Longitudinal

B. Frank breech

C. Complete breech

D. Incomplete breech

A 36-year-old G3 P1011 woman is seen in preconception clinic for considering a pregnancy. She concerned of getting pregnant given the outcome of her first pregnancy. At 32 years of age, she delivered a term infant with Down syndrome. During that gestation, she had a second-trimester multiple marker screen been performed.

Which of the following results would have been helpful?

A. Low hCG, low MSAFP, high estriol, high inhibin A

**B. High hCG, low MSAFP, low estriol, high inhibin A

C. Low hCG, high MSAFP, high estriol, low inhibin A

D. Low hCG, high MSAFP, low estriol, low inhibin A

A 29-year-old woman presents to the clinic with a history of irregular menstrual cycles for the last 2 years. Her last delivery 5 years ago. Currently, she is not on any contraception. Examination shows all within normal limits except breast examination revealed frank galactorrhea.

Which of the following is most helpful investigation?

A. Beta-human chorionic gonadotropin

B. Ultrasound of the breast

**C. Serum prolactin

D. Thyroid function

A 34-year-old woman G2 P0010 presents at 32 weeks gestation for a routine antenatal appointment. She reports mild headache, but no right upper quadrant pain or visual disturbance. Physical examination is otherwise unremarkable (see lab result).

Blood pressure 150/100 mmHg

Urine dipstick Test Result Normal Value
Protein +3 absent

Which of the following is the best next step of management?

**A. Admission for observation

B. Admission for induction of labor

C. Outpatient appointment in 1 week time

D. Admission for immediate cesarean section

A 36-year-old primigravida woman just delivered spontaneously baby girl weighing 4.4 kg. After 5 minutes placenta is delivered complete and intact. Massaging of the uterine is performed along with 20 units of oxytocin in 1000 mL of lactated Ringers fast drip. After careful inspection of the genital tract, a second-degree laceration was identified and a 2-cm left lateral vaginal wall laceration, suturing is difficult because of brisk bleeding from above the site of laceration. Physical examination reveals a soft, boggy uterine fundus.

Blood pressure 164/92 mmHg
Heart rate 130 /min
Respiratory rate 18 /min
Temperature 37 °C

Which of the following is the next best step in management?

**A. Prostaglandin F2

B. Methylergonovine

C. Manual exploration

D. Oxytocin 10 units IV infusion

A 20 year-old woman primigravida at 29 weeks' gestation presents with continuous vaginal bleeding and back pain. She denies sexual intercourse within the last 48 hours or trauma to the abdomen. Vaginal Examination reveals about 100 mL of blood in the vaginal vault and cervix is closed (see image and report).

Blood pressure 110/60 mmHg
Heart rate 90 /min
Respiratory rate 16 /min
Temperature 36.0 °C

Pelvic Ultrasound:
Cephalic fetal presentation, amniotic fluid index of 10, and anterior-fundal placenta.

Which of the following is the most appropriate medication?

**A. Dexamethasone

B. Indomethacin

C. Terbutaline

D. Oxytocin

A 30-year-old woman G2 P1001 at 34+2 weeks' gestation presents to Emergency Room reporting painless vaginal bleeding. Immediately transvaginal ultrasound shows placenta completely overlying the internal os, a fetus in cephalic presentation, and an amniotic fluid index of 14. The cervical appears long and closed on speculum examination. She has slow, continuous vaginal bleeding. Fetal heart is monitored (see image).

Blood pressure 110/78 mmHg
Heart rate 106 /min
Respiratory rate 14 /min
Temperature 36.9 °C

Which of the following is the most appropriate in management?

**A. Hospitalization

B. Betamethasone

C. Cesarean section

D. Magnesium sulfate

A 27-year-old woman primigravida at 39 weeks' gestation has been laboring for a few hours. Her cervix is 6 cm dilated, 80% effaced, and fetal vertex is at 0 station. Membranes have been ruptured for 20 hours and her labor is being augmented with oxytocin. Non-stress test is done (see image).

Blood pressure 110/76 mmHg

Heart rate 82 /min
Respiratory rate 18 /min
Temperature 37.2 °C
Oxygen saturation 95 %

Which of the following is the most appropriate in management?

**A. Discontinue oxytocin

B. Cesarean section

C. Amnioinfusion

D. Ampicillin

A 25-year-old woman primigravida at 31+5 weeks' gestation presents with abdominal cramping and lower back pain. She denies leaking of fluid from the vagina. Speculum examination shows no pooling liquor and nitrazine paper stays yellow. Cervical cultures are taken. Her cervix changes from closed and 50% effaced to 2 to 3 cm and 80% effaced. She is placed on fetal monitoring (see image).

Which of the following is the most appropriate next step in management?

A. Terbutaline

B. Cesarean section

C. Magnesium sulphate

**D. Tocolytic therapy and corticosteroids

A 34-year-old woman G3 P1011 at 30 weeks' gestation is in preterm labor. She has received an initial bolus of 6 g of MgSO4 over 30 minutes and continuing on a maintenance rate of 4 g/hr for the last 2 days to reduce her contraction pattern to 1 every 15 minutes. Currently, the contractions are barely noticeable to her. Deep tendon reflexes are 0 bilaterally. Auscultation reveals crackles on her lung bases on deep inspiration.

Blood pressure 90/50 mmHg
Heart rate 88 /min
Respiratory rate 9 /min
Temperature 37.1 °C
Oxygen saturation 95 %

Which of the following is the best next step in management?

A. Calcium gluconate

**B. Discontinue MgSO4

C. Switch to terbutaline

D. Serum magnesium level

A 39-year-old woman primigravida presents at 39 weeks gestation for a routine visit. Physical examination is unremarkable. Cervix is 2 cm dilated and 90% effaced, with the fetal vertex at 0

station. Urine dipstick is done (see image).

Blood pressure 140/90 mmHg

Which of the following is the most appropriate management option?

**A. Induction of labor

B. Immediate cesarean section

C. Admission to hospital for observation

D. Outpatient observation till 40 weeks'gestation

A 36-year-old woman with 10-year history of infertility due to male factor is brought to Emergency Room with vaginal bleeding and abdominal pain. Thereafter, she progresses to complete abortion at 8 weeks' gestation while awaiting for admission. She is crying and her husband is an overwhelmed emotionally.

Which of the following is the most appropriate next step?

A. Quick counseling and expedite admission

**B. Explore, identify and respond to the couple emotion

C. Admission to postpartum ward based on her condition

D. Explore, identify the cause and respond to the couple with management plan

A 30-year-old woman G5 P0030 and her husband present to the clinic at 9 weeks' gestation with mild spotting after an intercourse, no abdominal pain reported. She has a history of 3 previous first trimester abortions. The couple are blaming themselves for the bleeding. They show a strong presentation of emotion.

Which of the following is best way to deal with this situation?

A. Identify their emotion and calm them down

B. Empathic response is sufficient to calm them down

C. Understand their emotion without showing that to them

**D. Explore and validate their emotion with empathic response

A 21-year-old woman married for 6 months brought to the Emergency Department by police with bruises on the face, chest and both hands. On examination, she looks sad with tears, sitting quite, and facing down to the floor.

Which of the following is the most appropriate approach for history and examination?

A. Invest time with clinical findings at the beginning

**B. Explore and identify her sadness and find out more what is causing it

C. Introducing yourself with a big smile and proceed to a chief complain

D. History and examination should be with the presence of the family member

A 28-year-old G4 P0121 at 28 weeks' gestation, visitor to the country, presents with labor-like pain for 2 hours. On arrival, while trying to take history and to perform examination, the patient could not understand due to language barrier. She looks anxious and worries about her pregnancy, which is similar experience to her 4-year-old boy whom delivered prematurely.

Which of the following is the most appropriate step in communication?

A. Showing an understanding to her emotion is inappropriate because of language barrier

B. Showing that her emotions cannot be validated because she had similar experience

**C. Showing that her emotions are understood

D. Calling a help from other colleagues

A 37-year-old woman G2 P1001 at 20 weeks' gestation presents for a routine prenatal visit. she has no complaints. Her previous pregnancy has been unremarkable. She has chronic hypertension and history of cholecystectomy. She admits to smoking cigarettes several packs a day for relaxation and says she has read several papers that show no increased risk of congenital anomalies. Doppler shows fetal heart rate at 156 beat per minute.

Blood pressure 108/68 mmHg
Heart rate 100 /min
Respiratory rate 16 /min
Temperature 36.6 °C
Oxygen saturation 95 %

Which of the following is the best course of action?

A. Schedule her in 4-week time in antenatal clinic

B. Refer her to a social worker for possible substance abuse

**C. Educate her about the possibility of delivering a small infant

D. Acknowledge that she is correct about no increased risk of congenital anomalies

A 29-year-old primigravida presented in labor and progressed well and had a mediolateral episiotomy.

Which of the following is a theoretical benefit to performing a mediolateral episiotomy compared to a midline episiotomy?

A. Improved healing

B. Less painful for patient

C. Decreased risk of infection

**D. Decreased risk of fourth degree laceration

A 20-year-old primigravida at 39 weeks presents in labor and she progresses well. During the delivery, it is necessary to cut an episiotomy. However, the tear extends through the rectal mucosa.

What is the classification of this type of perineal tear?

A. 1ST degree

B. 2ND degree

C. 3RD degree

**D. 4TH degree

A 39-year-old G5 P2114 at 23 weeks gestation presents to her routine antenatal visit. Ultrasound shows a large fetus for date and she is scheduled for an oral glucose tolerance test (GTT). She had previous pregnancy ended up with preterm labor due to polyhydramnios. Result of GTT shows abnormal of fasting and 2- hour plasma glucose.

What is the following pathophysiology statement explains the above condition?

A. Normal pregnancy is a diabetogenic state mediated by placental inhibin hormone

B. Normal pregnancy is a diabetogenic state mediated by placental progesterone hormone

C. Normal pregnancy is a diabetogenic state mediated by placental estradiol hormone

**D. Normal pregnancy is a diabetogenic state mediated by placental lactogen hormone

A 17-year-old woman presents with her mother to the clinic complaining of never having had menstruation. On examination, she is webbing of her neck and cubitus valgus. Lacks pubic hairs and no breast development noted. The mother is worried about the daughter and would inquire about the simplest test to start with.

Height 135 cm
Weight 46 kg

Which of the following is the simplest and most useful test?

A. Serum TSH and FT4

**B. Serum FSH and LH

C. Serum estrogen

D. Serum prolactin

A 32-year-old G3 P0020 admitted to the hospital with an incomplete abortion. She underwent dilatation and curettage during which excessive bleeding developed that required vigorous curettage. She returned to the clinic 6 months later complaining of no menstruation since her curettage despite positive premenstrual symptoms.

Which layer of her endometrium is damaged based on history?

A. Spongy zone

**B. Basalis zone

C. Compact zone

D. Functional zone

A 51-year-old woman presents to her appointment complaining of hot flushes. She would like to get an explanation of her symptom.

Which of the following involves hot flushes?

A. Subjective symptoms of vasomotor instability

B. Peripheral vasodilatation reflecting an elevation of core body temperature

C. Peripheral vasodilatation resulting from direct effect of elevated FSH and LH

**D. Peripheral redistribution of blood flow leading to sweating and increased heart rate

A 17-year-old healthy girl and gymnast in her school team presents with history of the absence of menstruation. She reports that she develops breasts later than her friends and never began menses. On examination, her Tanner stage V development of breasts and pubic hair.

Which of the following is the most likely cause of this girl primary amenorrhea?

**A. Hypogonadotropic hypogonadism

B. Transverse vaginal septum

C. Testicular feminization

D. Gonadal agenesis

A 40-year-old woman has achieved a pregnancy via in-vitro fertilization presents with her spouse at 11 weeks' gestation to the clinic (see report).

Ultrasound:
Shows a twin pregnancy. A 5-mm nuchal translucency (NT) is discovered in one of the fetus.

Which of the following is an implication of NT finding?

A. The fetus has a high risk of NT enlargement by 18 weeks' gestation

**B. The fetus has a high risk of cardiac malformation

C. The fetus has a high risk of neural tube defect

D. The fetus has a high risk of Turner syndrome

A 62-year-old patient presented with vaginal bleeding. Investigations revealed a malignant tumor of uterine fundus.

Which of the following groups of lymph nodes is likely affected in this condition and to be dissected during surgery?

A. Superficial inguinal

B. Deep inguinal

C. Internal iliac

**D. Para-aortic

A 25-year-old married woman is found to have a 5-cm left adnexal mass during a routine pelvic examination, which is confirmed by ultrasound. She denies symptoms or using any contraceptives. Her last menstrual period was 2 weeks earlier. A urine pregnancy test is negative.

Which of the following is the most likely diagnosis?

**A. Follicular cyst

B. Pelvic kidney

C. Ectopic pregnancy

D. Corpus luteal cyst

A 21-year-old woman primigravida at 38 weeks' gestation is in active labor. Her cervix is 5 cm dilated and fetal vertex is at +1 station. The tocodynamometer is done (see image).

What is the best description of the initial acid-base status of the fetus?

A. Uteroplacental insufficiency

**B. Respiratory acidosis

C. Metabolic acidosis

D. Asphyxia

A 38-year-old G3 P1011 woman presents for her initial antenatal visit at 6 weeks' gestation. She is known to have type 2 diabetes mellitus for 5 years that is managed by oral hypoglycemic agents.

Which of the following is the best indicator of fetal outcome in her pregnancy?

A. Glucose Tolerance Test

B. Blood glucose value in the clinic

**C. Glycosylated hemoglobin value

D. Nuchal translucency on ultrasound

A 43-year-old woman G9 P5126 breastfeeding of her 5-month-old daughter comes to the clinic because of positive home pregnancy test. She does not know her last menstrual period.

Which of the following would be the most useful method to determine her estimated date of delivery?

A. Physical examination

B. Maternal perception of fetal movement

C. Abdominal ultrasound at 18 weeks' gestation

**D. Transvaginal ultrasound as early as possible in the first trimester

A couple from Al-Ahsa Eastern Province of Saudi Arabia presents for antenatal booking. A complete blood count and blood film is ordered. Accordingly, further assessment of the risk to the fetus and to the pregnancy from the disease that is typified by the blood smear (see image).

What is a diagnostic test to be performed at preconception or early in prenatal care?

A. Serum iron

B. Serum total bilirubin

**C. Hemoglobin electrophoresis

D. Platelet-associated immunoglobulin G electrophoresis

A 27-year-old primigravida at 39 weeks' gestation presents to the hospital complaining of spontaneous watery gush. A speculum examination is performed and small amount of fluid is seen in the vault. Nitazine paper test indicates a pH of 7.

Which of the following is another reliable test to confirm amniotic fluid leaks?

A. Indigo carmine injection into the amniotic sac

B. Methylene blue injection into the amniotic sac

C. Ultrasonography to assess amniotic fluid volume

**D. Microscopy to detect arborization or ferning of fluid

An 80-year-old woman who presents to the clinic with a vulval lump. It has been bleeding intermittently. It is very sore and she is finding it very uncomfortable to sit down.

A new vulval lump in an elderly woman is vulval cancer until proven otherwise. It is not unusual for elderly women to put off consulting their doctors because of embarrassment and reluctance to be examined.

What is the best step to reduce embarrassment and reluctance to be examined?

**A. Building rapport, taking history and examination

B. Getting help from social worker in management plan

C. Brief discussion and reschedule a visit in a nearest future

D. Introducing oneself followed by history and examination

A 48-year-old woman presents with a complaint of a 3-year history of stress incontinence, urgency and urge incontinence. She leaks urine about 4 times a day, has to wear sanitary pads all the time and rarely travels due to the urgency and need to pass urine 8 or 9 times during the day. On examination, body mass index normal, pelvic floor; marked reduced muscle strength noted.

Which of the following is the recommended first line of management?

A. Request a cystoscopy

B. Commence an oral anticholinergic medication for 8 weeks

C. Midstream culture and treatment with antibiotics if indicated

**D. A course of pelvic floor exercises and bladder retraining for 8 weeks

A 45-year-old woman presents to clinic with symptoms of leaking urine on coughing, sneezing, exercising and when she has the urge to void. No medical or surgical significant of note.

Which of the following is the most likely diagnosis?

A. Urge incontinence

**B. Mixed incontinence

C. Functional incontinence

D. Stress urinary incontinence

A 58-year-old postmenopausal woman presented to Gynaecology Clinic with history of inability to reach the toilet and control her micturition. The complaint was associated with strong desire for emptying her bladder even if the circumstances are not appropriate.

Which of the following is the most likely diagnosis?

**A. Urge incontinence

B. Mixed Incontinence

C. Retention with overflow

D. Stress urinary incontinence

A 35-year-old pregnant woman at 13-weeks of pregnancy presented with painless vaginal bleeding. Vaginal examination shows a suspicious lesion of the cervix (see report).

Fetal ultrasound:
Shows normal viable fetus and size corresponds to her gestational age.

Which of the following is the most appropriate next step?

**A. Pap smear

B. Colposcopy

C. Cone biopsy

D. Endocervical curettage

A 26-year-old patient with 6-weeks history of amenorrhea presented with mild lower pelvic pain and vaginal bleeding.

Pelvic examination revealed a soft uterus of normal size with mild tenderness at the right adnexa (see lab results and report).

Blood pressure 110/70 mmHg
Heart rate 82 /min

Respiratory rate 22 /min
Temperature 37.6 °C

Test Result Normal Values
Human chorionic gonadotropin 1000 < 5 mIU/mL
B-hCG 1000 1080-56500 mIU/ml

Pelvic ultrasound:
Shows a thickened endometrium with no intrauterine sac, minimal amount of fluid in the cul-de-sac and right adnexal mass measuring 1.2 cm.

Which of the following is the most appropriate management?

A. Mifepristone

**B. Methotrexate

C. Salpingectomy

D. Salpingostomy

A 6-year-old girl brought by her mother with vulvar itching and bloody vaginal discharge for few days.

Which of the following is the most likely diagnosis?

A. Candidiasis

**B. Foreign body

C. Sexual abuse

D. Atrophic vaginitis

A 55-year-old menopausal woman presented with vulvar irritation associated with urgency and frequency. Examination of the external genitalia revealed odourless watery discharge and generalized vulvar erythema with excoriation.

Which of the following is the most likely diagnosis?

A. Candidiasis

B. Trichomoniasis

**C. Atrophic vaginitis

D. Bacterial vaginosis

A 22-year-old woman presented with headache, malaise and fever. Examination revealed multiple, bilateral painful anogenital vesicles.

Which of the following is the most likely diagnosis?

A. Genital warts

**B. Genital herpes

C. Genital mycoplasmas

D. Chlamydia trachomatis

A 32-year-old pregnant woman at 26-weeks of gestation diagnosed with large genital warts in the vulva.

Which of the following is the most appropriate management?

**A. Cryotherapy

B. Electrocautery

C. Podophyllin resin

D. Intralesional interferon

A 34-year-old patient at 38-weeks of pregnancy with genital chlamydia trachomatis.

Which of the following is most commonly acquired infection by the newborn in such a condition?

**A. Eye

B. Ear

C. Liver

D. Lung

A 32-year-old pregnant woman with polyhydramnios presented at 37-weeks of gestation with painful vaginal bleeding and uterine tenderness following spontaneous rupture of membranes. Cardiotocography, shows persistent bradycardia.

Which of the following is the most likely diagnosis?

A. Vasa previa

B. Cord prolapse

C. Placenta previa

**D. Abruptio placenta

A 23-year-old primigravida presented at 32-weeks of gestation with seizures (see lab result).

Blood pressure 160/110 mmHg
Heart rate 78 /min
Respiratory rate 18 /min
Temperature 36.6 °C

Test Result Normal Values
Protein +++ absent

Which of the following is the most appropriate next step in management?

A. Steroids

B. Diuretics

C. Hydralazine

**D. Magnesium sulfate

A 38-year-old primigravida presents at 38-weeks of gestation with history of spontaneous rupture of membranes 24-hours ago. She has no labour pains. On abdominal examination, the uterus is soft and the fetus is in cephalic presentation. Cardiotocography shows normal fetal heart rate.

Which of the following is the most appropriate next step in management?

A. Observation

B. Amnioinfusion

C. Caesarean section

**D. Induction of labour

A 27-year-old woman presented at 24-weeks of gestation with dysuria and lower abdominal pain.

Which of the following is the most appropriate next step in management?

A. Cystoscopy

B. MRI pelvis

**C. Urine culture

D. Ultrasound of urinary tract

A 40-year-old woman presents to the clinic complaining of heavy bleeding for the last 4-months. After taking a detailed history and full physical examination, the patient and her gynaecologist reach to a plan of management and decision to undergo a hysteroscopy.

Which of the following is the most common complication of hysteroscopy?

A. Infection

B. Adhesion

**C. Haemorrhage

D. Vaginal discharge

A 22-year-old woman is seen in the Preconception Clinic. She is planning to get pregnant during winter season.

Which of the following vaccine is recommended during preconception period?

A. Rubella

B. Pertussis

**C. Influenza

D. Varicella

A 26-year-old woman is seen in the preconception clinic for a routine visit.

Which of the following is recommended during preconception period?

A. Zinc

B. Iron

C. Calcium

**D. Folic acid

A 34-year-old woman presented at 33-weeks of gestation with fever, rigors and loin pain. She gave a history of urinary tract infection twice during this pregnancy.

Which of the following is the most appropriate next step in management?

A. MRI pelvis

B. Ureteroscopy

**C. Septic screening

D. Ultrasound urinary tract

A 30-year-old woman presents with oligomenorrhea and mild hirsutism. She was diagnosed as a case of polycystic ovarian syndrome (PCOs). She has no desire to get pregnant.

Which of the following is the most appropriate next step in management?

A. Metformin

B. Spironolactone

C. Progesterone pills

**D. Combined estrogen-progesterone pills

A 39-year-old woman presented with menorrhagia. Pelvic ultrasound confirms the presence of uterine fibroid.

What is the most likely location of this fibroid?

A. Cervical

B. Subserosal

C. Intramural

**D. Submucosal

A 35-year-old P2002 woman presented with secondary amenorrhea for 8 months.

Which of the following is the most appropriate next step in management?

A. Pregnancy test

B. Pelvic ultrasound

**C. Full history taking

D. Clinical examination

A 33-year-old woman, known case of polycystic ovarian syndrome (PCOs), presents with oligomenorrhea and severe hirsutism.

Which of the following is the best biochemical test for hirsutism?

**A. Testosterone

B. 17 Hydroxyprogesterone

C. Adrenocorticotropin (ACTH)

D. Sex steroid binding globulin

A 22-year-old patient presented at 10-weeks of gestation with mild vaginal bleeding and suprapubic pain. Vaginal examination reveals a bulky uterus corresponding to the gestational age and a closed cervix.

Which of the following is the most likely type of abortion?

A. Missed

B. Complete

C. Inevitable

**D. Threatened

A 32-year-old known case of secondary infertility found to have a submucosal uterine fibroid measuring 6 cm on pelvic ultrasound. She desires to preserve her fertility.

Which of the following is the most appropriate management?

**A. Hysteroscopic resection

B. Laparoscopic myomectomy

C. Laparoscopic hysterectomy

D. Laparotomy myomectomy

A 37-years-old P4 with a history of 3 previous caesarean sections is undergoing an elective caesarean section at 37 weeks of gestation. The placenta was found to be attached deeply into the uterine wall.

Which of the following is the most likely diagnosis?

A. Placenta previa

B. Placenta increta

**C. Placenta accreta

D. Placenta percreta

A 29-year-old primigravida presented at 22 weeks of gestation with mild lower abdominal pain. Abdominal examination reveals that the uterus is corresponding to the gestational age with positive fetal heart. Vaginal examination reveals a short soft cervix, which is 1.5 cm dilated with herniation of fetal membranes.

Which of the following is the most likely diagnosis?

A. Septic abortion

B. Threatened abortion

C. Incomplete abortion

**D. Cervical incompetence

A 27-year-old primigravida presented at 36-weeks of gestation with headache, blurred vision (see lab result).

Blood pressure 160/110 mmHg
Heart rate 76 /min
Respiratory rate 18 /min
Temperature 36.8 °C

Test Result Normal Values
Protein +++ absent

Which of the following is the most appropriate medication for acute treatment of hypertension?

A. Clonidine

B. Methyldopa

**C. Hydralazine

D. Sodium nitroprusside

A 39-year-old G6 P5005 is seen in the Antenatal Clinic for routine check-up at 22 weeks of gestation. Her blood pressure found to be 140/90 mmHg and no proteinuria.

Which of the following is the most appropriate treatment?

**A. Methyldopa

B. Verapamil

C. Nifedipine

D. Hydralazine

A 27-year-old woman presented to the police department with bruises all over her body.

Which of the following is the main predictor of a domestic violence?

A. Tobacco use

B. Second marriage

C. Personal bankruptcy

**D. Marital dissatisfaction

A 25-year-old newly married woman presented to the Outpatient Clinic for routine gynecological examination.

Which of the following has the highest diagnostic value?

A. Abdomen

B. Vaginal inspection

C. General appearance

**D. Pelvic digital examination

A 50-year-old woman with menorrhagia due to a large uterine fibroid was seen in the clinic to complete the consent form of an elective hysterectomy.

What is the most appropriate step in this condition?

A. Listening carefully

**B. Clear documentation

C. Exploration of her feelings

D. Giving an introduction about surgery

A 36-year-old woman came at 10 weeks of gestation for an ultrasound.

Which of the following has the highest diagnostic value?

A. Femur length

B. Biparietal diameter

**C. Crown-rump length

D. Abdominal circumference

A 37-year-old primigravida was seen in the Antenatal Clinic for a follow-up. She is a known smoker for 3 years and has a history of subfertility. A positive family history of diabetes mellitus in a second degree relative.

Which of the following is a significant risk factor in her history?

A. Age

**B. Smoking

C. History of diabetes

D. History of subfertility

A 35-year-old woman came for an ultrasound scan to confirm gestational age of her pregnancy.

Which of the following is most appropriate timing?

**A. 11-13 weeks

B. 20-22 weeks

C. 26-28 weeks

D. 32-34 weeks

A 34-year-old woman with a history of recurrent pregnancy loss was seen in the clinic.

Which of following is the best predictor for pregnancy complication?

A. Heartburn

B. Ankle edema

C. Abdominal pain

**D. Vaginal bleeding

A 28-year-old woman presented to Preconception Clinic with a known diagnosis of epilepsy 6 years ago, poorly controlled and frequent epileptic attacks.

Which of the following is the most appropriate next step in management?

A. Reassurance

**B. Review medication

C. Start her with aspirin

D. Start her with folic acid

A 38-year-old presented to Labor Ward with severe abruptio placentae. She was diagnosed with intrauterine fetal death and disseminated intravascular coagulopathy (DIC). Vaginal examination revealed 6 cm dilated cervix.

Which of the following is the most appropriate management?

A. Observation

B. Cesarean section

**C. Augmentation of labor

D. Total abdominal hysterectomy

A 22-year-old patient presented to the Emergency Department with history of expulsion of products of conception at home. On examination, cervix were closed with minimal vaginal bleeding.

Which of the following is the most likely diagnosis?

**A. Complete abortion

B. Inevitable abortion

C. Threatened abortion

D. Incomplete abortion

A 29-year-old woman was seen in the clinic with a history of recurrent pregnancy loss between 9-12 weeks of gestation.

Which of the following is the most likely cause of her condition?

**A. Genetic

B. Anatomic

C. Endocrine

D. Immunological

A 27-year-old sexually active woman came for annual examination. 3 years ago, she had a pap smear which was reported to be normal.

Which of the following is the most appropriate management?

A. Reassurance

B. No pap testing

C. Digital pelvic examination

**D. Repeat pap test with cytology

A 40-year-old pregnant woman at 24 weeks of gestation with fever and did not seek any medical advice.

What is the most likely reason for illness denial?

A. Neglect

**B. Self-medication

C. Fear from physician

D. Cost of consultation

A 34-year-old woman came to the clinic with history of primary infertility for 3 years. She was

anxious, worried and depressed.

Which of the following is a positive body language?

A. Scratching

**B. Eye contact

C. Picking fingers

D. Fiddling with hair

A 33-year-old woman was seen in the clinic with her husband, they have a history of primary infertility. The investigations of the husband had showed that he is HIV positive.

What is the most appropriate next step?

A. Inform wife

B. Reassurance

**C. Inform husband

D. Hide information

A 38-year-old multipara had a postpartum hemorrhage after a normal vaginal delivery of a macrosomic baby.

Which of the following is the best management of this condition?

**A. Oxytocin

B. Ergonovine

C. Misoprostol

D. Carboprost

A 38-year-old woman had postpartum hemorrhage after a normal vaginal delivery. She was started on oxytocin and bimanual massage of the uterus, but failed to control the bleeding.

What is the most appropriate next step in management?

A. B-Lynch suture

B. Hysterectomy

**C. Uterine artery ligation

D. Angiographic embolization

A 23-year-old newly married woman came to the police department after beaten up by her husband.

Which of the following is the most consistent predictor of attitudes supporting the use of violence against women?

A. Age

B. Cultural background

**C. Beliefs about gender roles

D. Socio-economic background

A 33-year-old woman was seen at 34 weeks of gestation with a broken arm after beaten up by her husband.

When is the most common time that increases the risk of violence by an intimate partner?

A. At holidays

B. After retirement

**C. During pregnancy

D. After family visiting

A 25-years-old pregnant woman at 20 weeks of gestation presented with twisted ovarian cyst, which needed an emergency laparotomy. The patient was explained about the condition, but she refused the surgery.

Which of the following is the most appropriate action should be taken?

**A. Accept her refusal

B. Force her for surgery

C. Inform a close relative

D. Take the consent from husband

A 31-year-old diabetic woman in active labor. Cardiotocography shows abnormal fetal heart tracing.

What is the most appropriate next step in management?

A. Stop oxytocin

6th June Exam DHA

B. Face mask Oxygen

C. Inject tocolytic drug

**D. Chang the maternal position

A 35-year-old woman in active labour. Cardiotocography for fetal monitoring done (see image).

Which of the following is the most likely diagnosis?

**A. Late deceleration

B. Early deceleration

C. Variable deceleration

D. Combined decelerations

A 13-year-old girl presented with her mother with primary dysmenorrhea since her menarche a year ago.

Which of the following is the best management?

A. Aspirin

B. Medroxyprogesterone

C. Oral contraceptive pills

**D. Non-steroidal anti-inflammatory drug

A 24-year-old woman experienced sexual harassment in the workplace.

Who is the most likely involves in such condition?

A. Employee

B. Coworker

**C. Supervisor

D. Potential client

A couple with infertility came to the clinic for follow-up. The investigations showed that the wife had bilateral blocked Fallopian tubes.

Which of the following is the most appropriate step of the counselling process?

**A. Inform wife

B. Inform husband

C. Inform the couple

D. Inform a close relative

A 59-year-old woman attends to the clinic complaining of abnormal uterine bleeding for the last 2 months and concerned about her condition. She had the last menstrual cycle 12 years ago. On examination, the vagina is found to be pale with dry, smooth and shiny epithelium losing of most of its rugation.

Which of the following is the most probable cause of the condition?

**A. Atrophy

B. Infection

C. Adenomyosis

D. Herbal or dietary supplementation

A 59-year-old woman attends to the clinic complaining of abnormal uterine bleeding for the last

2 months. She had the last menstrual cycle 12 years ago. On examination, agina is noted to be pale, smooth and shiny dry epithelium along with loss of vaginal rugae (see report).

Ultrasound Scan:
The endometrial lining is 15 mm thick, the uterus is average in size with no abnormality in shape. The ovaries are normal and no adnexal masses or free fluid detected.

Which of the following is the most appropriate procedure at this stage?

A. MRI of the pelvis

**B. Endometrial sampling

C. Diagnostic laparoscopy

D. Ultrasound guided biopsy

A 59-year-old woman attends the clinic complaining of abnormal uterine bleeding for the last 2 months. She had the last menstrual cycle 12 years ago. An Ultrasound Scan was taken and endometrial sampling is planned (see report).

Ultrasound Scan:
The endometrial lining is 15 mm thickness.

Which of the following best describes a prerequisite for this procedure?

A. Admission

**B. Verbal consent

C. Anesthesia clearance

D. Operating Room setting up

A 59-year-old woman attends for the first time to the clinic complaining of abnormal uterine bleeding for the last 2 months and she is extremely concerned about her condition. The last menstrual cycle was 12 years ago. The patient requests admission, preparation and booking for a hysterectomy.

Which of the following is the most appropriate response?

A. Approve the request

B. Admit into the hospital to gain confidence

C. Discuss in referring to an oncologist because of age and risk of malignancy

**D. Calm her down and conduct a detailed informative discussion about best options of her

A 59-year-old woman attends to the clinic complaining of abnormal uterine bleeding for the last 2 months. All her investigations are normal and endometrial atrophy is the cause of her condition. The patient is not convinced and requesting a second opinion by another physician.

Which of the following is the most appropriate response at this point?

A. Offer repeating the workup again

B. Perform further imaging studies to gain her trust

**C. Provide a detailed medical report as it is her right

D. Convince her not to waste time by getting a second opinion

A 59-year-old woman attends to the clinic complaining of abnormal uterine bleeding for the last 2 months and concerned about her condition, she had the last menstrual cycle 12 years ago. An ultrasound scan was taken and endometrial polyp is suspected (see report).

Ultrasound Scan:
19 mm endometrial lining.

Which of the following should be offered to the patient at this stage?

A. Endometrial ablation

B. Abdominal hysterectomy

C. Laparoscopic hysterectomy

**D. Hystroscopy and polypectomy

A 59-year-old woman with a complaint of abnormal uterine bleeding for the last 2 months undergoes a procedure (see image).

What is the name of this procedure?

A. Cystoscopy

**B. Hystroscopy

C. Laparoscopy

D. Urethroscopy

A 59-year-old woman undergoes a hysteroscopy secondary to her complain of abnormal uterine bleeding for the last couple of months (see image).

Which of the following is the most likely diagnosis?

A. Adenomyosis

B. Endometriosis

C. Subserosal fibroid

**D. Endometrial polyps

A 60-year-woman old is complaining of abnormal genital bleeding. She describes the amount of bleeding has been scanty, spotting and just staining the pad.

Which of the following would be the most likely source of bleeding?

A. Uterus

B. Ovarian source

C. Fallopian tubes

**D. Lower genital tract

A 45-year-old woman is complaining of abnormal genital bleeding.

Which of the following would highly suggest a uterine source of bleeding?

A. Color of the blood

B. Post-coital bleeding

C. Scanty vaginal bleeding

**D. Profuse vaginal bleeding

A 35-year-old woman is complaining of abnormal genital bleeding.

Which of the following would suggest a cervical source of bleeding?

**A. Post-coital bleeding

B. Heavy vaginal bleeding

C. Pain-associated bleeding

D. Color of bleeding contents

A 35-year-old woman is complaining of abnormal genital bleeding, she states that the amount is scanty and not associated with blood clots, but noticeable for post-coital bleeding.

Which of the following is the most appropriate next step?

A. Pelvic ultrasound

B. Coagulation profile

C. Complete blood count

**D. Assess the vagina and cervix

A 40-year-old woman is complaining of abnormal uterine bleeding. She is known diabetic on oral hypoglycemic agent for 5 years and her menarche at the age of 13. The last 3 cycles were heavy, however, denies any weight loss or palpitation.

Which of the following would make the highest risk of endometrial cancer?

A. Late menarche

B. Early menopause

6th June Exam DHA

**C. Diabetes mellitus

D. Progesterone secreting tumor

A 43-year-old never married woman is complaining of abnormal uterine bleeding for the last 3

months. She was placed on progestin tablets to control her bleeding by a family physician prior to referral. One of the sisters had a diagnosis of thyroid cancer 2 years ago.

Blood pressure 110/70 mmHg
Heart rate 76 /min
Respiratory rate 16 /min
BMI 17 kg/m2

Which of the following would make the highest risk of endometrial cancer?

**A. Nulliparity

B. Underweight

C. Progesterone therapy

D. Family history of thyroid cancer

A 47-year-old woman presents with abnormal uterine bleeding, she describes the interval between the onset of bleeding episodes to be less than 21 days, heavy and prolonged.

Which of the following is the most appropriate next step?

A. MRI pelvis

**B. Endometrial sample

C. Oral Progesterone therapy

D. Progesterone releasing IUCD

A 27-year-old woman presents with abnormal uterine bleeding, she describes the interval between the onset of bleeding episodes to be less than 21 days, heavy and prolonged.

BMI 21 kg/m2

Which of the following is the most appropriate next step in management?

A. GnRH injection

B. Thermal ablation

C. Endometrial sampling

**D. Oral contraceptive pills

A 36-year-old woman presents with abnormal uterine bleeding. The bleeding is persistent for the last 8 months. She denies any significant family history of endometrial cancer.

BMI 41 kg/m2

Which of the following is the most appropriate next step in assessment?

A. Pelvic MRI

**B. Endometrial sample

C. Hystroscopic resection

D. Chest, abdomen and pelvic CT

A 32-year-old married woman presents to the clinic with vague abdominal pain of 1-week duration, she claims an irregular menstrual cycles and her last cycle occurred 2 months ago.

Blood pressure 142/85 mmHg
Heart rate 101 /min
Respiratory rate 18 /min
Temperature 36.6 °C

Which of the following is the most appropriate next step?

A. Reassurance

**B. Pregnancy test

C. Hystrosalpingogram

D. Administer analgesia

A 32-year-old married woman presents to the clinic with vague abdominal pain of 1-week duration. She claims an irregular menstrual cycles and her last menstrual cycle occurred 2 months ago. The patient is a known smoker with surgical history of open appendectomy due to ruptured appendicitis when she was 14 years of age.

Blood pressure 110/70 mmHg
Heart rate 102 /min
Temperature 36.6 °C

Which of the following diagnoses is to be rule out initially?

A. Diverticulitis

B. Acute Cystitis

**C. Tubal pregnancy

D. Ovarian cyst torsion

A 32-year-old married woman presents with vague, sharp abdominal pain of 1-week duration, she claims an irregular menstrual cycles and her last menstrual cycle occurred 2 months ago. The patient is a known smoker with history of open appendectomy due to ruptured appendicitis at the age of 14 years (see lab results).

Blood pressure 90/40 mmHg
Heart rate 105 /min
Respiratory rate 18 /min
Temperature 36.6 °C

Test Result Normal Values

Human chorionic gonadotropin 1800 < 5 mIU/mL
Hb 11 130-170 g/L (Male)
120-160 g/L (Female)
HCT 0.39 0.42-0.52 (Male)
0.37-0.48 (Female)
MCH 29 28-33 pg/cell
MCHC 332 320-360 g/L
MCV 89 80-95 fl

Which of the following is the best next step in management?

A. Administer misoprostol

B. Administer strong analgesics

**C. Direct surgical intervention after stabilization

D. Consult general surgery team to rule out acute abdomen

A 33-year-old woman is day 2 post laparotomy where salpingostomy was performed for right tubal pregnancy, the procedure was performed without complications and the patient is suitable to be discharged from the hospital (see lab results).

Test Result Normal Values
Hb 12 130-170 g/L (Male)
120-160 g/L (Female)
Human chorionic gonadotropin (hCG) 3500 < 5 mIU/mL

Which of the following is the most appropriate follow up approach?

A. Follow up appointment is not required

B. Out-patient visit at 6 weeks post-operative

C. Perform a pelvic ultrasound scan 1 week post-operative

**D. Serum hCG to be measured weekly until the level is undetectable

A 29-year-old woman is day 2 post laparotomy where salpingectomy was performed for left tubal pregnancy, the procedure was performed without complications and the patient is suitable to be discharged from the hospital (see lab results).

Blood pressure 110/70 mmHg
Heart rate 76 /min
Temperature 36.6 °C

Test Result Normal Values
Hb 13 130-170 g/L (Male)
120-160 g/L (Female)
Human chorionic gonadotropin (hCG) 6488 < 5 mIU/mL

Which of the following is the most appropriate follow up approach?

**A. Single postoperative hCG testing to confirm a large decline in the level

B. Weekly hCG level measurement until the level is undetectable

C. Pelvic ultrasound to be performed 6 days post-operative

D. Hystrosalpingogram 6 weeks post-operative

A 30-year-old woman 6 weeks post laparotomy where salpingostomy was performed for left tubal pregnancy, the procedure was performed without complications and the patient was discharged in a good stable condition. She has been followed up weekly to measure the serum human chorionic gonadotropin level, a plateau was noticed for the last 3 weeks at the following level (see lab result).

Test Result Normal Values
Human chorionic gonadotropin 3442 < 5 mIU/mL

Which of the following is the most appropriate next step in management?

A. Admit for laparotomy

B. Initiate oral contraceptive pills

**C. Consider methotrexate injection

D. Reassure the patient and continue follow up

A healthy 33-year-old woman G2 P1001 at 6 weeks of gestation with a diagnosis of right tubal ectopic pregnancy is upon counselling for medical versus surgical management. She opts for medical treatment (see lab results and report).

Blood pressure 110/70 mmHg
Heart rate 76 /min
Respiratory rate 18 /min
Temperature 36.6 °C

Test Result Normal Values
Hb 13 130-170 g/L (Male)
120-160 g/L (Female)
Human chorionic gonadotropin 3400 < 5 mIU/mL

Ultrasound: Reveals a 3-cm right tubal pregnancy with a negative fetal heart activity.

Which of the following should considered with regard to medical treatment?

A. Higher failure rate is expected

B. Medical treatment is contraindicated

C. CT is to be done prior to methotrexate administration

**D. Medical treatment with provision accessibility to the hospital

A 20-year-old woman was recently diagnosed with endometriosis. She is concerned with the progression of endometriosis to malignancy.

What would be the best provided information to the patient about endometriosis regarding her concern?

A. Protects against cancer

B. Has no relationship with cancer in general

C. Has clear relationship with thyroid cancer

**D. Appears to be associated with epithelial ovarian cancer

A 21-year-old primigravida is being monitored in the Labor and Delivery Unit. She is currently at 37 weeks of gestation and the cardiotocogram is done. It is persistently showing the pattern for the last 90 minutes. Therefore, she is concerned about the reason of this pattern in the fetal monitoring (see image).

Which of the following would best describe the cause of this pattern in response to the patients concern?

**A. Fetal anemia

B. Head compression

C. Cord compression

D. Utero-placental insufficiency

A 30-year-old woman P3 at 33 weeks of gestation, according to her last menstrual period, presents at the Ultrasound Unit. Ultrasound scan is done (see report).

Ultrasound Scan:
confirms the presence of a non-viable 30 weeks fetus.

Which of the following would be best to help in breaking this news?

A. Right away and straight to the point

B. Defer any plan of follow-up till after delivery

C. Be as strong as you can be and hide your emotions

**D. Address her emotions with empathetic verbal and nonverbal support

A 30-year-old primigravida at 37 weeks of gestation was just informed about the finding of a confirmed non-viable fetus with no obvious identified reason. She is now questioning the urgency of deciding the timing of delivery (see lab results).

Blood pressure 110/70 mmHg
Heart rate 76 /min
Respiratory rate 18 /min
Temperature 36.6 °C
Oxygen saturation 95 %
BMI 22 kg/m2

Test Result Normal Values
Hb 12 130-170 g/L (Male)
120-160 g/L (Female)

Platelets count 200 150-400 x 109/L
INR 1 0.8-1.2

Which of the following would be the best advice to be given to the patient?

A. It is necessary that the patient is urgently admitted for induction

**B. She has time to go home and take time in deciding the next step

C. Timing of induction should solely depend on the Bishop score

D. Waiting for spontaneous labor is not an option

A 32-year-old woman G2 P1001 at 38 weeks of gestation with history of cesarean section in her first delivery 4 years ago due to breech presentation. Current pregnancy, a diagnosis of intrauterine fetal demise is confirmed and mode of delivery to be discussed accordingly.

Which of the following would best be performed at this stage?

A. Wait for the patient's decision

B. Direct to a trial of vaginal delivery to avoid CS

C. Direct to have a CS to avoid pain and emotional distress

**D. Thorough counseling about the benefits and risks of vaginal delivery versus CS

A 20-year-old primigravida at 37 weeks of gestation has just been informed that the fetus is non-viable. She starts to feel guilty and blaming her habit of smoking up to 5 cigarettes per day which causes her fetal demise.

Which of the following to be considered in counselling this patient?

A. Smoking has no definite relationship with fetal demise

B. She should stop smoking for the sake of future pregnancies

**C. The cause is yet undetermined and investigations will be performed

D. Smoking 5 cigarette per day will increase the likelihood of fetal demise by 10 folds

A 21-year-old G2 P1001 at 15 weeks of gestation according to her last menstrual period, she presents with mild vaginal bleeding and is planned to undergo suction evacuation (see image).

Which of the following is the most expected complications of the procedure?

A. Pneumonia

B. Hypothyroidism

C. Amniotic embolism

**D. Uterine perforation

A 22-year-old woman presents to the clinic complaining of pelvic pain, dysmenorrhea, and dyspareunia. She denies any history of fever or vaginal discharge. Ultrasound was performed

(see image and report).

Blood pressure 110/70 mmHg
Heart rate 76 /min
Respiratory rate 18 /min
Temperature 36.6 °C

Ultrasound:
Describes the appearance as containing "ground glass" internal echoes

Which of the following would be best described to the patient regarding her condition?

A. The condition is highly malignant

B. The partner should be investigated

C. Antibiotics are required to be initiated

**D. Association with infertility to be considered

A 33-year-old woman presents to the clinic after an incidental finding of a mass in the cervix. She denies any complaints of pelvic pressure, pain or menorrhagia but admits to have occasional post coital bleeding (see image).

Which of the following is the most appropriate in counselling the patient?

**A. Excision to be performed in the clinic

B. Admission and further workup is required

C. Reassurance and follow-up in a few months

D. Broad spectrum antibiotics need to be started

A patient notices one or more sharply marginated, scaling, and red plaques predominantly involving only the vulva. Psoriasis is suspected.

Which of the following is required for a definitive diagnosis of psoriasis?

**A. Biopsy is required

B. Staining using iodine

C. Clinical diagnosis is sufficient

D. Potassium hydroxide skin scraping

A 24-year-old woman has been applying recently a new herbal cream on her vulva for the last 2 weeks. She notices a burning sensation and itching along with redness at the area of application.

Which of the following is the most likely diagnosis?

A. Psoriasis

B. Candidiasis

**C. Allergic contact dermatitis

D. Squamous intraepithelial lesions of the vulva

A 30-year-old woman is complaining of a newly developed red and painful swelling on the vulva. On examination, the appearance of a solitary lesion is noticed, located at the 5 o'clock position on the vestibule. It is red, tender, fluid-filled and appears to be infected.

Which of the following is the most likely diagnosis?

A. Furuncle

B. Vulvar abscess

**C. Bartholin duct abscess

D. Hidradenitis suppurativa

A 66-years-old woman presents with a single and asymptomatic bright-red papule at the urethral meatus. The surface bleeds easily on touch (see image).

Which of the following is the most likely diagnosis?

**A. Urethral caruncles

B. Urethral prolapse

C. Bartholin Abscess

D. Furuncle

An 18-year-old girl is complaining of the appearance of lesions that are firm, smooth and skin-colored. They located at the anogenital area and mons pubis. Occasionally they get inflamed and become red and are described to be of 2 to 3 mm in diameter with occasional itching (see image).

Which of the following is the most likely diagnosis?

A. Squamous cell carcinoma

**B. Molluscum contagiosum

C. Insect bites

D. Furuncle

A 20-year-old is suffering from vitiligo, which involves the vulva.

Which of the following is the cause for this condition?

A. Malignant changes of the keratocytes

B. Allergic reaction from ingested drugs

C. Result from overuse of irritants locally

**D. Autoimmune lymphocytic attack against melanocytes

A 20-year-old is complaining of asymptomatic solitary, benign, soft, smooth-surfaced cyst appearing on the vulvar vestibule. On examination, it is found to be domed, translucent and filled with clear, viscous mucin. Incision of the lesion allows jelly-like mucinous material to be extruded.

Which of the following is the most likely diagnosis?

A. Candidiasis

B. Molluscum contagiosum

C. Hidradenitis suppurativa

**D. Vestibular mucinous cyst

A 70-year-old comes to the clinic complaining of a slowly enlarging lesion at the labia majora, which does not heal and bleeds when traumatized (see image).

Which of the following is the most likely diagnosis?

**A. Basal cell carcinoma

B. Fox-fordyce disease

C. Neurofibromas

D. Syringomas

A 30-year-old woman comes to the clinic with anogenital lesions that appears as sharply marginalized are seen. They are smooth, flat-topped, 1 to 2 cm in diameter, moist papules and small plaques. The patient admits of having multiple sexual partners and of use of illicit drugs (see image).

Which of the following is the most likely diagnosis?

**A. Condyloma lata

B. Basel cell carcinoma

C. Molluscum contagiosum

D. Lichen simplex chronicus

A 35-year-old obese woman notices soft, skin-colored, brown papules with short, thin stalks that are 1 to 3 mm developing on the multiple areas of the inguinal folds. She states that when they are traumatized, they becomes blue and purpuric (see image).

Which of the following is the most likely diagnosis?

**A. Skin tags

B. Condylomata lata

C. Basel cell carcinoma

D. Condylomata accumonata

A 25-year-old primigravida at 38 weeks of gestation is being monitored in the Labor and Delivery Ward. Abdominal examination reveals an average size fetus of 3 kg in cephalic presentation and well engaged head. Cervical examination shows 5 cm dilated, 70% effaced and -3 station for the last 4 hours. She is not distressed and not on epidural analgesia. Fetal monitoring is done (see image).

Which of the following is the best next step of management?

A. Start MgSO4

**B. Start Oxytocin

C. Cesarean section

D. Reassess in 2 hours

A 35-year-old woman G5 P4004 in labor and has been fully dilated for the last 2 hours. Maternal exhaustion is noted after pushing efforts for the last hour. She is not on epidural analgesia and the cardiotocogram shows category 1. Abdominal examination shows an average size fetus of 2.7 kg, cephalic presentation with 4/5 palpable head. On pelvic examination, the cervix is fully dilated and 100% effaced with -3 station.

Which of the following is the best next step?

**A. Cesarean section

B. Forceps delivery

C. Ventose delivery

D. Reassess in 2 hours

A 38-year-old woman G5 P4004 at 39 weeks of gestation is in labor room and on epidural analgesia. She has been fully dilated for the last 30 minutes and all of sudden, the uterine contractions cease despite of oxytocin infusion along with fetal deceleration and mild vaginal bleeding.

Which of the following is the best next step?

**A. Stop oxytocin infusion and perform an immediate cesarean section

B. Left lateral position and review in 20 minutes

C. Stop the epidural analgesia infusion pump

D. Increase the oxytocin infusion

A 39-year-old woman G2 P1001 at 37 weeks of gestation presented in labor. She has history of cesarean section due to breech presentation 2 years ago. It has been 2 hours since she was declared fully dilated and current pelvic examination reveals 10-cm dilatation, fully effacement and +3 to +4 station. She is contracting 4 strong contractions in 10 minutes. The cardiotocogram is showing occasional early deceleration.

Which of the following in the best next step?

**A. Ventose delivery

B. Cesarean section

C. Review in 2 hours

D. Initiate oxytocin

A 30-year-old woman G4 P3003 at 37 weeks pregnant with breech presentation presents to the clinic inquiring about external cephalic version.

Which of the following is a contraindication of external cephalic version would be conveyed to the patient?

A. Amniotic fluid index of 22 cm

**B. The presence of a low lying placenta

C. History of smoking 10 cigarettes per day

D. An umbilical cord length of 35 to 38 cm

A 30-year-old woman G4 P3003 is pregnant at 37 weeks with a history of cesarean section due to non-reassuring fetal heart trace. Currently, she is in labor with breech presentation. Her inquiry is possibility of external cephalic version.

Which of the following would be an absolute contraindication of external cephalic version?

A. Anterior placenta

B. History of cesarean section

C. Cervical dilatation of 3 to 4 cm

**D. Cardiotocogram with variable deceleration

A couple suffering infertility asked the feto-maternal consultant about surrogacy as an option to treat their infertility. The hospital does not offer the service and the consultant is not sure if surrogacy is legal in Saudi Arabia.

Which of the following is the most appropriate action?

**A. Inform the couple that hospital doesn't provide the service

B. Warn the couple that surrogacy might be illegal in Saudi Arabia

C. Refer them to a colleague who has connections with surrogacy canters

D. Give them appointment after few weeks to have enough time to review the topic

Post-menopausal women asked her gynecologist for hormone replacement therapy. The gynecologist explained to the women that no evidence support the use of hormone replacement therapy in her case. The women insisted.

Which of the following is the most appropriate action?

A. Refer the women to another gynecologist

B. Prescribe the hormone replacement therapy

C. Consult the hospitals clinical ethics committee

**D. Refuse to prescribe the hormone replacement therapy

A 50-year-old diabetic woman admitted to the medical ward with chest pain. The chest X-ray is suggestive of empyema. The radiologist was consulted and advised to do CT guided aspiration.

Who should perform the informed consent process?

**A. The radiologist

B. The head nurse

C. The internal medicine resident

D. Any member of the treating team

An internal medicine resident is teaching the medical students how to examine a diabetic patient. He forgot to close the curtain while exposing the patient's abdomen.

Which one of the ethical principles is violated?

A. Respect patients dignity

**B. Respect patients privacy

C. Respect patients autonomy

D. Respect patients confidentiality

A 20-year-old man is admitted as a suspected Ebola case. After few hours, the patient asked the treating physician to discharge him or he will leave the hospital.

Which of the following is the most appropriate next action?

**A. Call the hospitals security team

B. Consult the hospitals ethics committee

C. Refer the case to the infectious disease team

D. Ask the patient to sign the discharge against medical advice from

A 70-year-old man is diagnosed with metastatic cancer. His family asked the oncologist not to tell their father of the diagnosis.

Which of the following is the most appropriate action?

A. Consult the hospitals legal advisor

**B. Inform the patient about his diagnosis

C. Consult the hospitals ethics committee

D. Do not inform the patient about his diagnosis

A 78-year man with post chemotherapy and radiotherapy end stage cancer is suffering from unbearable pain. His family asked the oncologist to increase the pain killer doses to relive their father's pain. The oncologist agreed after explaining to the family that the higher doses may hasten their father's death.

Which of the following principles is used to make the decision?

A. Principle of totality

B. Principle of subsidiarity

**C. Principle of double effect

D. Principle of informed choice

A 70-year-old woman admitted for a hip replacement operation. The surgeon was interrupted by the patient when he was trying to explain the surgery and its possible complications. The patient expressed her wish to not knowing the details. The surgeon respected her wish and informed the anesthesiologist who insisted to explain to the patient all details.

Which of the following actions should be taken by the surgeon?

**A. Consult the hospitals ethics committee

B. Let the anesthesiologist deal with the patient

C. Inform the patient about the anesthesiologist decision

D. Reschedule the operation and find another anesthesiologist

A 40-year-old diabetic man presents to the Emergency Room with charcot knee. He was stabilized and transferred to the Surgical Ward. The surgical team explained to the patient the need for amputation. The patient refused.

Which of the following is the most appropriate next action?

**A. Assess the patient mental capacity

B. Refer the patient to another hospital

C. Consult the hospitals clinical ethics committee

D. Aske the patient to sign discharge against medical advice form

A 20-year-old man was admitted for a simple tonsillectomy. The operation took longer time than usual because of a bleeding resulted from a surgical error. The surgery was successful and the patient fully recovered with no complications. Next day the patient asked the surgeon why his operation took longer time than usual.

Which of the following is the most appropriate action?

A. Consult the hospital's ethics committee

**B. Reassure the patient and tell him what happened

C. Ask another surgeon from the team to tell the patient

D. Reassure the patient but do not tell him what happened

A 30-year-old woman presented to the Emergency Room with abdominal pain. The signs and symptoms are suggestive of acute appendicitis. During the surgery, the appendix found in normal state. Appendectomy was done as it is the common practice is to remove the appendix even if it is not inflamed. The surgeon does not remember that he informed the patient about this decision during the consent procedure.

What should the surgeon do when the patient recovered next day?

**A. Tell the patient that it is part of the standard procedure

B. Ask another surgeon from the team to tell the patient

C. Consult the hospital's ethics committee

D. Do not tell the patient what happened

A 90-year-old man with advanced metastatic lung cancer was admitted to the Surgical Intensive Care Unit with deteriorating pulmonary functions and labelled a do not resuscitate case by the intensivist. The thoracic surgeon would like to do a de-bulking operation to enable the patient to breath but not sure, if the patient could survive the operation.

Which of the following is the most appropriate action?

A. Explain to the patient and ask him to sign high risk consent form

**B. Do not operate since the patient is likely not going to improve

C. Consult the hospitals ethics committee

D. Discuss the case with the intensivist

A 19-month-old boy known case of spinal muscular atrophy admitted with deterioration of pulmonary functions that mandate intubation. The pediatrician discussed the decision of intubation with the family but they refused because of their previous experience with their child who died with the same condition.

Which of the following is the most appropriate next action?

A. Call the hospital's child abuse team

B. Search the Internet for similar cases

**C. Consult the hospital's clinical ethics committee

D. Ignore the family objection and intubate the patient

A 15-year-old boy is a suspected case of acute meningitis was rushed to the Emergency Room by his parents. The pediatrician decided to do a lumber puncture.

Which of the following is the most appropriate next action?

A. Take parent consent but not patient assent

B. Take patient assent but not parent consent

**C. Take both patient assent and parent consent

D. Do not take patient assent or parent consent because it is an emergency case

A 12-year-old girl is brought to the Emergency Room with multiple bruises attributed by her parents to an accident while she was playing. After thorough history and physical examination, the pediatrician suspected child abuse.

Which of the following is the most appropriate next action?

**A. Call the hospital's child protection team

B. Confront the parents with her suspicions

C. Consult the hospitals clinical ethics committee

D. Ask the family to take the patient to another hospital

A newly born baby resulted from out of wedlock pregnancy was abandoned by his mother. On examination, the baby found to have inguinal hernia and the pediatric surgeon advised to do hernia repair now.

Which of the following is the most appropriate action?

A. Refer the case to the police

**B. Refer the case to the social worker

C. Consult the hospitals clinical ethics committee

D. Perform the operation without consent form

A 7-year boy diagnosed with measles. When his father was asked about the child immunization record, he replayed that he does not believe in immunization.

Which of the following is the most appropriate action?

A. Inform the child protection team

B. Consult the hospital's clinical ethics committee

**C. Explain to the father the importance of immunization

D. Ignore the father's response and focus on treating the child

A 6-year-old child a known case of bronchial asthma presents to the Emergency Room with asthmatic attack. His father is a heavy smoker and was advised many times to avoid exposing his son to smoking. The father seems to be careless and not interested to listen to the pediatrician.

Which of the following is the most appropriate action?

**A. Inform the child protection team

B. Consult the hospital's clinical ethics committee

C. Explain to the father the importance of immunization

D. Ignore the father's response and focus on treating the child

A premature baby at 23-weeks, with fatal congenital anomalies is born and in need for intubation and resuscitation. His mother is one of the physicians in the hospital and she expressed her wish to do not resuscitate the baby.

Which of the following is the most appropriate action?

A. Honor the mother's wish

B. Refer the case to another colleague

**C. Consult the hospital's clinical ethics committee

D. Ignore the mother's wish and do full resuscitation

A 35-years-old man comes to the clinic complaining of fever. He just come back from a 2-weeks trip to a country in sub-Saharan Africa.

Which of the following is the most likely cause of his fever?

**A. Malaria

B. Zika virus

C. Dengue fever

D. Travelers' diarrhea

Which of the following preventive measures is recommended for travel diarrhea?

**A. Avoid beverage with ice

B. Eat only in clean restaurants

C. Drink government-supplied water only

D. Avoid raw vegetables and eat fruits only

A 40-year-old man is planning to travel to Sudan for a short trip.

Which of the following prophylactic medications is recommended for malaria prevention?

A. Chloroquine

B. Malaria vaccine

**C. Atorvaquone/proguanil

D. No need for prophylaxis

Which of the following preventive measures is recommended for pilgrims from African meningitis belt countries in addition to quadrivalent (ACYW 135) vaccine against meningitis?

A. Strict surveillance for 6 days after arrival

B. Strict surveillance for 10 days after arrival

**C. 1 tablet (500 mg) of ciprofloxacin chemoprophylaxis

D. Vaccination with a booster dose of the quadrivalent (ACYW 135) on arrival

According to the health regulations for travelers to Saudi Arabia for the pilgrimage (Hajj), which of the following vaccines is required for pilgrims arriving from any country?

**A. Meningitis

B. Yellow fever

C. Dengue fever

D. Poliomyelitis

A 40-year-old man comes to the clinic complaining of fever. He just arrived back from a short trip to a country in Southeast Asia.

Which of the following is the most likely cause of his fever?

A. Malaria

B. Zika virus

**C. Dengue fever

D. Travelers' diarrhea

Which of the following is the percentage prevalence of smoking among Saudi adult men?

A. 11 %

**B. 21 %

C. 37 %

D. 51 %

A 42-year-old man presented to the Primary Care Clinic for the routine checkup. He has been smoking 1-pack of cigarettes a day for 22 years. He has no intention of quitting and feels fine.

Which of the following is the most appropriate cessation approach?

A. Set a "quit date" with the patient

6th June Exam DHA

B. Prescribe nicotine replacement therapy

**C. Give clear, personalized advice to quit

D. Refer him to classes for smoking cessation

A 45-year-old smoker came to the clinic for his diabetes follow-up. During discussion, he acknowledged that smoking is not good for his health. He plans to quit this year.

According to the Stages of Change Model, at what stage of change is this patient?

A. Precontemplation

**B. Contemplation

C. Preparation

D. Maintenance

Tobacco products consists of thousands of chemical compounds including nicotine.

Which of the following is the most outcome related to nicotine substance?

A. COPD

**B. Addiction

C. Lung cancer

D. Heart diseases

Which of the following is the most approved evidence-based intervention to be used in smoking cessation?

A. Hypnosis

**B. Varenicline

C. Acupuncture

D. BICOM bioresonance device

Which of the following is the most effective preventive measure to improve post-myocardial infarction prognosis?

A. Lowering lipid

B. Regular exercise

**C. Smoking cessation

D. Maintaining an ideal body weight

Which of the following sets indicates the 5 A's approach during smoking cessation counselling?

**A. Ask, advise, assess, assist, arrange follow-up

B. Ask, assist, advise, advocate, arrange follow-up

C. Assess, advocate, ask, advise, arrange follow-up

D. Advocate, ask, assess, advise, arrange follow-up

Which of the following is the minimum recommended daily minutes of physical activity for children?

A. 30

**B. 60

C. 120

D. 150

What is the minimum number of days per week recommended to practice muscle-strengthening physical activity?

**A. 2

B. 3

C. 4

D. 5

Which of the following is the most appropriate intervention for primary prevention of type 2 diabetes?

A. Screening

B. Pharmacotherapy

**C. Physical activity

D. Bariatric surgery

Which of the following is the recommended minimum number of minutes for an effective small session of aerobic physical activity?

A. 5

**B. 10

C. 15

D. 20

Which of the following is the most appropriate characteristic for a new test as a confirmatory test for a disease diagnosis?

**A. Specific

B. Sensitive

C. Non-invasive

D. Easy to administer

Which of the following is the recommended age in years to start screening for dyslipidemia in a low-risk man?

A. 18

B. 25

**C. 35

D. 50

A 55-year-old woman has just completed her screening mammogram and the results were normal. She has no symptoms and no family history of breast cancer.

When she should have another mammogram?

A. 6 months

B. 1 year

**C. 2 years

D. 3 years

What is the recommended age in years to start screening for high blood pressure in adults with no risk factors?

**A. 18

B. 25

C. 35

D. 50

Which of the following is a recommended age in years for a low-risk adult man to start screening for colon cancer?

A. 30

B. 40

**C. 50

D. 60

A screening test for liver cirrhosis was administered to 800 people with proven liver cirrhosis and to 800 people without liver cirrhosis. The test results were positive for 200 of the proven cases and 100 of the normal persons.

What is the sensitivity of the screening test?

**A. 25 %

B. 33 %

C. 67 %

D. 88 %

A new screening test for diabetes has a sensitivity of 90% and specificity of 80%.

Which of the following is the best interpretation?

A. 80% of non-diabetics had positive result

B. 80% of diabetic patients had positive result

**C. The test was positive for 90% of diabetic patients

D. For each 100 positive test results, 90% were diabetics

An 82-year-old woman is admitted at noon with pneumonia to the General Medical Ward. At night, she is found disoriented and restless by the nursing staff.

Blood pressure 152/88 mmHg
Heart rate 99 /min
Respiratory rate 22 /min
Temperature 38.2 °C
Oxygen saturation 94 %

Which one of the following is the best initial step the nurse should do?

A. Call her family to come and watch her at bedside

B. Restrain the patient physically in her bed

**C. Orient the patient to her environment, start nasal O2 and raise the rails of her bed

D. Call the duty doctor for Lorazepam order of 5 mg IV Stat

A 77-year-old woman is admitted to Neurology Ward with right hemispheric intracranial bleeding. 5 days after admission the physiotherapist reported verbally to the nurse that the patient left buttock is getting red with skin loss. The nurse forgot to tell the resident and no action was taken. 2 days later, the patient spiked a fever with hypotension. On examination, the resident found purulent discharge from the pressure sore.

Which of the following is the best approach to prevent this incident?

A. Better nutritional support

**B. Better communication

C. More nursing training

D. Extra nursing staff

A 92-year-old man was admitted after fall at home. There was no fracture. Foley catheter was inserted due to immobility from pain. His appetite was good. Acetaminophen with codeine was prescribed for pain. 4 days later, the patient became confused with agitation. The nurse noted cloudy urine in the bag.

Blood pressure 168/92 mmHg
Heart rate 105 /min
Respiratory rate 18 /min
Temperature 38.2 °C
Oxygen saturation 98 %

What is the best action to prevent this complication?

A. Avoid Codeine in this age group

B. Request frequent turning of the patient by family

**C. Review the need for urinary catheter daily

D. Add nutritional supplement twice daily

A 73-year-old woman is brought to Emergency Room after a fall at home. She is diagnosed with left hip fracture (see lab results).

Weigh 82 kg

Test Result Normal Values
Sodium 136 134-146 mmol/L
Potassium 4.2 3.5-5.1 mmol/L
Creatinine 68 44-115 µmol/L

What is the best order by the admitting orthopedic surgeon to prevent deep vein thrombosis?

A. Aspirin 81 mg po daily

**B. Enoxparin 40 mg SC daily

C. Fondaparinux 10 mg SC daily

D. Heparin Sulfate 10,000 units IV BID

A 45-year-old woman underwent open laparotomy for a ruptured appendicitis. 3 days postoperatively, she developed fever again with severe abdominal pain and vomiting. On examination, her abdomen was rigid with decreased bowel sounds. CT scan showed foreign body in right iliac fossa. Patient was taken urgently back to Operating Room and was found to have a missed infected sponge in her peritoneal cavity (see lab results).

Test Result Normal Values
WBC 27 4.5-10.5 x 109/L
Neutrophils 95 40-60%
Creatinine 87 44-115 µmol/L

Which of the following is the most appropriate action by the surgeon?

A. Report the surgical assistant mistake to the administration

B. Do not inform the patient about the finding

C. Call his malpractice lawyer and report the incident

**D. Inform the patient with apology about the mistake

An intern was attending Operation Room for laparoscopic nephrectomy for suspicious renal mass. The urologist asked to prep for the right kidney approach. However, the intern remember

from his history and exam that it was the left kidney.

Which of the following is the most appropriate action by the intern?

A. Keep quiet since he might be wrong

B. Leave OR and check the electronic note

C. Call the chief intern to ask for guidance

**D. Inform the surgeon about his concern

While doing ward round the consultant surgeon asked the resident to write Pipercillin-Tazobactam for their patient. The pharmacist reported that the patient has a questionable allergy to penicillin. The consultant insisted to write the order.

Which of the following is the most appropriate action by the resident?

A. Write the order and let the consultant sign it

B. Write the order then call chief surgeon to complain

**C. Gently refuse to write the order

D. Write the order and keep quiet fearing retaliation

A 27-year-old woman presented to Emergency Room with right lower abdominal pain for 1 day with vomiting. The Emergency Room physician requested CT scan of the abdomen.

Which of the following is the most important information to know?

A. Any Previous CT scan results

B. Full urinary bladder

C. Volume status

**D. Pregnancy test

A 19-year-old healthy woman presented to Emergency Room with left leg swelling and pain for 2 days. She has no significant past medical history. She just missed her menstrual period.

Blood pressure 131/89 mmHg
Heart rate 92 /min
Respiratory rate 26 /min
Oxygen saturation 94 %

Which of the following is the most important question to ask next in history?

A. History of fatigue

B. History of sleepiness

C. History of constipation

**D. History of oral contraceptive use

A 28-year-old pregnant woman in her 34 weeks of gestation presented to Emergency Room with heavy vaginal bleeding. Abruptio placentae is suspected (see lab result).

Blood pressure 88/42 mmHg
Heart rate 129 /min
Respiratory rate 26 /min
Oxygen saturation 96 %

Test Result Normal Value
Hb 86 130-170 g/L (Male)
120-160 g/L (Female)

Which one of the following is the best next approach to save her life?

A. Pelvic ultrasound

B. Admission to SICU under obstetric service

C. Transfusion with 2 units of fresh frozen plasma

**D. Rapid response team with coordinated multi-specialty team

A 68-year-old woman with history of heart failure, stroke and diabetes, admitted for hysterectomy. She was kept on normal saline due to poor oral intake. 2 days post-operation, the nurse noticed the patient pulse oxymetry was dropping with respiratory distress. On lung auscultation, there was bilateral basal crepitations

Which of the following is the best action to prevent this complication?

A. Cardiology and pulmonary consultation

B. Oxygen by nasal cannula at 2 L/min

C. Furosemide 40 mg iv on post-op day 1

**D. Daily reassessment of fluid status

A 19-month-old boy was brought to the Pediatric Clinic for ear infection. The nurse noticed the boy has not received any vaccination as recommended. The parents mentioned that they read that vaccinations are "bad to the boy brain".

Which of the following is the most appropriate action?

A. Refer the parent for psychiatric evaluation

B. Accept since parent have full right to choose

C. Call social services to take over the custody

**D. Correct the myth and explain the great benefit of vaccinations

A 24-year-old woman comes to the clinic. She is married for 3 years and has no previous pap smears. She asks for a pap smear during the visit.

Which of the following is the most appropriate action?

**A. Should get pap smear during this visit

B. Do not screen now, wait until she is 30 years of age

C. Next screening after 5 years with a combination of cytology and HPV testing

D. Cervical cancer screening in women younger than 30 years is likely to lead to more harms than benefits

A 4-year-old child presented with anorexia, low-grade fever, watery bloodless diarrhea, vomiting, abdominal cramps and dehydration 2 days after exposure to a case of diarrhea in day care center.

Which of the following is the most appropriate treatment?

A. Doxycycline

B. Ceftriaxone

C. Metronidazole

**D. Supportive management

Which of the following is considered a secondary prevention for diabetes?

**A. Screening

B. Chronic diseases management

C. Education about healthy lifestyle

D. Immunization against infectious diseases

Which of the following is the main method for prevention of tuberculosis?

A. BCG vaccine

B. Chemoprophylaxis

C. Health education

**D. Treatment of the patients with tuberculosis

In cardiovascular disease prevention, which of the following is considered primordial prevention?

**A. Prevention of coronary heart disease risk factors

B. Initiation of therapy to reduce recurrent coronary heart disease events

C. Decrease cardiac mortality in patients with established coronary heart disease

D. Modification of risk factors in order to prevent or delay the onset of coronary heart disease

Which of the following factors is directly related to increased risk of stroke?

A. Obesity

B. Diabetes

**C. Hypertension

D. Hypercholesterolemia

Which of the following is the strongest risk factor for diabetes in adults?

A. Stress

B. Pregnancy

**C. Abdominal obesity

D. High body mass index

A 13-year-old girl presented to the clinic with fever and painful cervical lymph nodes. On examination, tonsils were covered by white exudate.

Temperature 39 °C

Which of the following is the most likely complication to develop?

A. pneumonia

B. pharyngitis

C. scarlet fever

**D. glomerulonephritis

A 75-year-old woman presented with significant height loss.

Which of the following is the most appropriate investigation?

A. Bone mineral density

B. Measure serum 25-OH-D

C. Fracture risk assessment

**D. lateral thoracic and lumbar spine X-ray

Which of the following number of sleep hours is associated with more weight gain?

**A. < 5

B. 6

C. 7

D. > 7

For which of the following cancers "population screening" is recommended?

A. Oral cancer

B. Ovarian cancer

C. Pancreatic cancer

**D. Colorectal cancer

Which of the following is the treatment goal for diabetic patients with coronary artery disease?

A. Triglyceride < 150

B. Blood pressure < 140/90

**C. Low density lipoprotein < 70

D. High density lipoprotein > 70

Which level of prevention we apply when detecting a pregnant woman infected with hepatitis B?

A. Primordial

B. Primary

**C. Secondary

D. Tertiary

Which of the following best explains the increase of diseases prevalence when incidence is constant?

A. Loss at follow-up

B. Poor case ascertainment

**C. Improved quality of care

D. Increased diagnostic accuracy

Which of the following is the major preventable cause for dyslipidemia and coronary heart disease in women?

A. Diet

**B. Smoking

C. Low sleep quality

D. Physical inactivity

A 65-year-old man with a history of myocardial infarction (see lab results).

Blood pressure 140/90 mmHg
BMI 25 kg/m2

Test Result Normal Values

Cholesterol (LDL) 3.7 <3.36 mmol/L
Cholesterol (HDL) 1.1 >1.03 mmol/L
Apo A-I 1.37 0.88-1.8 g/L (Male)
0.98-2.1 g/L (Female)
Apo B-100 1.16 0.55-1.51 g/L (Male)
0.44-1.48 g/L (Female)

Which of the following is the most powerful risk prediction value for cardiovascular disease?

A. Hypertension

B. Body mass index

C. LDL cholesterol

**D. Apo B/Apo A1 Ratio

Which of the following vaccine is contraindicated during pregnancy?

**A. Zoster

B. Hepatitis B

C. Meningococcal (ACWY)

D. Human papillomavirus (HPV)

A 35-year-old Indian man came to Saudi Arabia for Hajj. He presented with a 4-day history of intermittent fever, shortness of breath, drowsiness, convulsion and confusion.

Which of the following is the most probable diagnosis?

**A. Malaria

B. Influenza

C. Yellow fever

D. Tuberculosis

Which of the following is the most significant risk factor for developing breast cancer among women? 6th June Exam DHA

**A. Age

B. Late menopause

C. Early menarche

D. Delaying childbirth until after 30

A 34-year-old male presents with chills, fever to 39 °C, retro-orbital pain, and severe muscle and joint pains.

Which of the following is the most likely diagnosis?

A. Ebola

B. Chikungunya

**C. Dengue fever

D. Corona (MERS Cov)

Which of the following provides the highest level of evidence for establishing effect of exercise on the quality of life?

A. Cohort study

**B. Clinical trials

C. Case control study

D. Observational study

Which of the following is the most appropriate measurement to estimate the impact of obesity prevention on the prevalence of type 2 diabetes?

A. Odds ratio

B. Relative risk

**C. Attributable risk

D. Cross product ratio

Which of the following is the most important characteristic to consider when choosing a screening test for cancer?

A. Cheap

B. Highly specific

**C. Highly sensitive

D. Quick to perform

Which of the following is most likely to increase the risk of cardiovascular disease?

**A. Sedentary lifestyle

B. Having a BMI of 28

C. Having a HbA1c of 6%

D. Consuming only 5 servings/day of vegetables

Which of the following is recommended to improve the general health of a person?

A. Monitoring dietary protein intake

**B. Performing regular physical activity

C. Switching from cigarette use to waterpipe

D. Consuming at least 2 servings of fruits and vegetables per day

Which of the following fulfils the minimum recommended time of moderate physical activity for healthy adults?

A. 20 minutes for 6 times per week

**B. 30 minutes for 5 times per week

C. 40 minutes for 3 times per week

D. 50 minutes for 2 times per week

Which of the following measures is recommended to avoid malaria infection in people traveling to an endemic country?

A. Vaccination

B. Immunoglobulin

**C. Chemoprophylaxis

D. Avoiding highly endemic areas

Which of the following medications is the most likely that malaria parasites develop resistance to?

A. Malarone

B. Mefloquine

**C. Chloroquine

D. Atorvaquone/proguanil

What is the most common diagnosis for travelers returning with fever from sub-Saharan Africa?

**A. Malaria

B. Zika virus

C. Dengue fever

D. Travelers' diarrhea

What is the most common disease diagnosed among travelers returning with fever from Southeast Asia?

A. Malaria

B. Zika virus

**C. Dengue fever

D. Travelers' diarrhea

Which of the following is the peak biting period for Aedes aegypti mosquito (the primary vector of dengue fever)?

**A. Early morning

B. Mid-day

C. Early night

D. Late night

Which of the following interventions is the best to use with pregnant women who smoke?

A. Bupropion

B. Varenicline

**C. Behavioral therapy

D. Nicotine replacement therapy

What is the latent period (incubation period) for lung cancer caused by cigarette smoking (in years)?

A. =5

B. =10

C. =15

**D. =20

After how many years the excess risk of myocardial infarction will decline significantly for individual who stop smoking?

**A. 1

B. 2

C. 3

D. 4

How many times the risk of myocardial infarction is increased in smokers compared to nonsmokers?

**A. 2

B. 3

C. 4

D. 5

On average, how many years of life the average smokers are expected to lose?

A. 5

**B. 10

C. 15

D. 20

How many times the risk of lung cancer is increased in smokers compared to nonsmokers?

A. 5

B. 10

**C. 15

D. 20

In a screening program in a population with a low prevalence of a particular disease, what most of the positive results would likely to be?

A. True positive

**B. False positive

C. True negative

D. False negative

Natural history of the disease has various stages. In which of the following stages a screening program would be most useful?

A. Pre-disease stage

B. Clinical disease stage

**C. Pre-clinical disease stage

D. Recovery, disability or death stage

Which of the following criteria is supporting the use of a screening test for community screening program?

A. The disease is rare

B. The test is very specific

**C. The test is quick and easy

D. Natural history of the disease is not yet clear

Which of the following screening test parameter is most likely to be affected by the disease prevalence?

A. Specificity

B. Sensitivity

C. Likelihood ratios

**D. Predictive values

What is the recommended age to start Pap smear screening for cervical cancer in married women?

**A. 20-24

B. 25-29

C. 30-34

D. 35-39

Which of the following is the recommended frequency of Pap smear screening for cervical cancer?

A. Every year

B. Every 2 years

**C. Every 3 years

D. Every 5 years

Which of the following is the recommended frequency of mammography for women aged 50 to 74 years?

A. Every year

**B. Every 2 years

C. Every 3 years

D. Every 5 years

Which of the following cancers is recommended to be screened for in asymptomatic adults?

A. Skin cancer

**B. Colon cancer

C. Thyroid cancer

D. Bladder cancer

After how many weeks of gestation, it is recommended to screen for gestational diabetes mellitus in asymptomatic pregnant women?

A. 4

B. 14

**C. 24

D. 34

What is the recommended age to start screening for osteoporosis with bone measurement testing in women?

A. 50-54

B. 55-59

C. 60-64

**D. 65-69

Which of the following populations should be screened for asymptomatic bacteriuria?

**A. Pregnant women

B. Diabetic patients

C. Newly married adolescent

D. Patients admitted for surgery

Which of the following vaccine is contraindicated in a child with egg allergy and should be assessed by an allergy/immunology specialist before vaccination?

A. MMR

B. Influenza

**C. Yellow fever

D. Pneumococcus